

Case Report

Asian Pacific Journal of Tropical Medicine

apjtm.org

doi: 10.4103/apjtm.apjtm_39_24

Mixed infection of *Nocardia farcinica* and *Nocardia cyriacigeorgica* in an immunocompromised patient: A case report

Vrushali Harsh Thakar, Prajakta Jadhav, Aishwarya Babu✉, Mahadevan Kumar, Abhijeet Kantilal Mane

Department of Microbiology, Bharati Vidyapeeth Deemed to be University Medical College, Dhankawadi, Pune, India

ABSTRACT

Rationale: *Nocardia* is a soil saprophyte, which can cause disseminated infection in immunocompromised patients. Early diagnosis and treatment can greatly improve prognosis.

Patient concern: A 26-year-old male presented with repeated episodes of fever, cough and breathlessness for 3 months.

Diagnosis: Mixed infection of *Nocardia (N.) farcinica* and *N. cyriacigeorgica* with diabetes and Cushing's syndrome.

Interventions: *N. cyriacigeorgica* was isolated from empyema fluid and *N. farcinica* from blood. Based on antimicrobial susceptibility, he was treated with imipenem, cotrimoxazole and amikacin.

Outcome: Patient expired due to infection and delayed diagnosis.

Lesson: Several cases of infection due to *N. farcinica* or *N. cyriacigeorgica* have been reported. But mixed infection caused by these two species is rare. Pulmonary and disseminated nocardiosis is associated with high mortality, especially in immunocompromised hosts. So early diagnosis and prompt treatment is needed.

KEYWORDS: *Nocardia cyriacigeorgica*; *Nocardia farcinica*; Matrix-assisted laser desorption ionization time-of-flight mass spectrometry

1. Introduction

The genus *Nocardia* is an aerobic actinomycete, which is catalase-positive, partially acid-fast, Gram-positive branching filamentous bacillus. It is widely distributed in soil. There are around 50 species that can cause human disease. Pathogenic species of *Nocardia* include *Nocardia* (*N.*) *asteroids*, *N. brasiliensis*, *N. farcinica*, *N. otitidiscaviarum* and *N. cyriacigeorgica*[1,2].

Immunocompromised individuals are more susceptible to develop nocardiosis. It commonly presents as pulmonary infection caused by inhalation of spores or fragment of broken hyphae[1]. Pulmonary nocardiosis manifests as lung abscess, pneumonia, endobronchial inflammatory mass or cavitatory lesion with clinical features of fever, cough, and chest pain. Central nervous system, skin, bone, brain, heart, eye, joints and kidneys are the extra pulmonary sites affected[3,4].

N. farcinica is a virulent species of *Nocardia* that can cause localized and disseminated infections, especially in immunocompromised conditions. Pneumonia, brain abscesses and skin infections are the major clinical presentations[4]. *N. cyriacigeorgica*, formerly known as *N. complex* Ⅵ, causes most cases of human nocardiosis, which commonly manifests as chronic bronchitis and brain abscess[5].

Clinical manifestation of nocardiosis is variable, making it difficult to diagnose[1]. The traditional diagnosis of nocardiosis is by culture but it has limited sensitivity. In recent studies, matrix-assisted laser desorption ionization time-of-flight mass spectrometry (MALDI-TOF) (Bruker, Daltonics, Germany) is used as a more rapid, accurate, and cost-effective method for identifying microorganisms. Here we present a case of necrotizing pneumonia caused by *N. farcinica* and *N. cyriacigeorgica*.

2. Case presentation

A 26-year-old male, a known case of diabetes mellitus and hypertension, from western Maharashtra, India, developed swelling

✉To whom correspondence may be addressed. E-mail: aishwaryabkk@gmail.com

This is an open access journal, and articles are distributed under the terms of the Creative Commons Attribution-Non Commercial-ShareAlike 4.0 License, which allows others to remix, tweak, and build upon the work non-commercially, as long as appropriate credit is given and the new creations are licensed under the identical terms.

For reprints contact: reprints@medknow.com

©2024 *Asian Pacific Journal of Tropical Medicine* Produced by Wolters Kluwer-Medknow.

How to cite this article: Thakar VH, Jadhav P, Babu A, Kumar M, Mane AK. Mixed infection of *Nocardia farcinica* and *Nocardia cyriacigeorgica* in an immunocompromised patient: A case report. Asian Pac J Trop Med 2024; 17(11): 516-518.

Article history: Received 13 January 2024 Revision 14 October 2024
Accepted 21 October 2024 Available online 26 November 2024

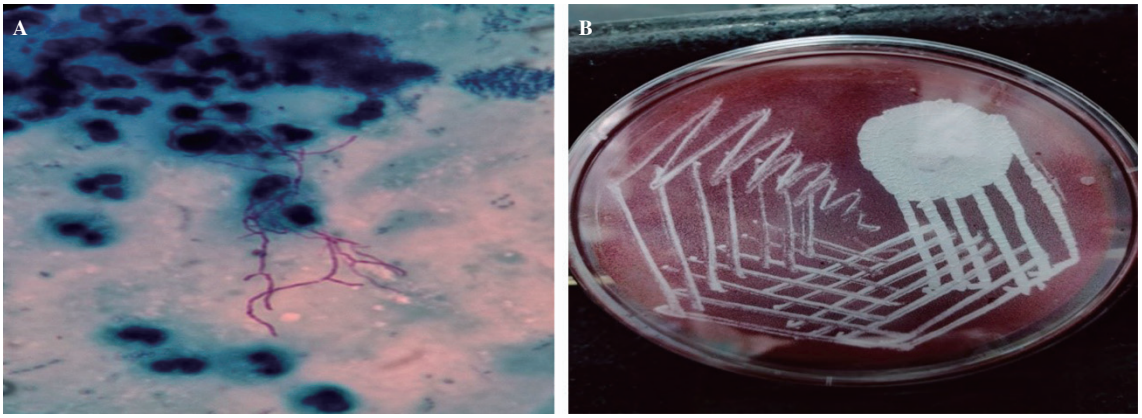

Figure 1. Ziehl-Neelsen stain showing thin filamentous branching acid-fast bacilli (A); and growth of *Nocardia* on blood agar (B) in a 26-year-old male presented with repeated episodes fever, cough and breathlessness for 3 months.

all over the body and palpitation three months earlier. One week later, the patient developed fever, cough and breathlessness and was treated with piperacillin-tazobactam at a local hospital. He showed improvement and was discharged after the treatment. He had repeated bouts of fever and cough for which he took treatment from a local practitioner. Three months later, he was admitted to our hospital with the same complaints. On examination, there was pedal edema, facial puffiness and pallor. Bilateral adrenal hyperplasia was noted. There was also reduction in air entry in the lower zone of right lung. Blood pressure and pulse were within normal limits. Oxygen saturation was 96% with two litres of oxygen. Haemogram, liver function test and renal function test were within normal limits. C-reactive protein (CRP)-111 mg/dL (normal range: <5 mg/dL), cortisol-106 μg/dL (normal range: 3.70-19.4 μg/dL), aldosterone-3.72 ng/dL (normal range: 3-16 ng/dL), adrenocorticotropic hormone-55.40 pg/mL (normal range: <120 pg/mL). Based on these investigations, a diagnosis of Cushing's syndrome was made.

The computed tomography of abdomen showed smooth hypertrophy of both adrenal glands with maintained adreniform shape, likely adrenal hyperplasia. The magnetic resonance imaging of brain was normal. Positron emission tomography scan showed consolidation like lesion in the right middle lobe of lung with cavitations and fluid collection which was suggestive of infective cause.

His blood, empyema fluid and sputum were sent for bacterial, fungal and mycobacterial culture. Automated blood culture was done by Bac T Alert (BioMérieux, Marcy l'Etoile, France) which flagged positive in 48 hours of incubation. Gram stain of blood and empyema fluid showed Gram positive filamentous bacilli. Modified Ziehl-Neelsen staining with 1% sulphuric acid showed thin filamentous branching acid fast bacilli (Figure 1A). Blood agar and Lowenstein Jensen medium (HiMedia, Mumbai, India) grew dry, chalky white colonies within 24 hours (Figure 1B). Organism was catalase positive, oxidase negative and hydrolysed urea. The organism was phenotypically identified as *Nocardia* species. Species identification was done by MALDI-TOF (Bruker, Daltonics, Germany) as *N. cyriacigeorgica* from empyema fluid (score ID 1.64) and *N. farcinica* (score ID 1.89) from blood. Antimicrobial susceptibility testing (AST) was done by broth micro dilution. *N. cyriacigeorgica* was susceptible to amikacin, co-trimoxazole, linezolid and tigecycline. *N. farcinica* was susceptible to amikacin, co-trimoxazole and linezolid. Both the strains were resistant to tobramycin, ciprofloxacin, clarithromycin, ceftriaxone, cefepime and imipenem.

The patient was empirically treated with imipenem, cotrimoxazole and amikacin. Imipenem was later discontinued as both species were resistant. The patient underwent middle and lower lobectomy of right lung. He was put on ventilator support. His clinical condition remained critical and prognosis was poor. Due to financial constraints, the patient took discharge against medical advice. He succumbed to his condition the day after discharge.

3. Discussion

Nocardia species usually cause chronic, progressive infections. These infections may be localized or disseminated and are an important cause of mortality in immunocompromised patients[6,7]. Major risk factors for pulmonary nocardiosis are poorly controlled diabetes mellitus, solid organ transplant recipients and long-term uses of immunosuppressive drugs or corticosteroids[1,5,7].

At least 219 species of *Nocardia* genus have been described. Among them, *N. asteroides* is the most common species associated with human infections while *N. farcinica* is less common. It is important to distinguish between *N. asteroides* and *N. farcinica* as later is more virulent and resistant to antibiotics like third generation cephalosporins, tobramycin and tetracycline. It causes aggressive infection associated with high mortality[8,9].

Torres *et al.* have reviewed 52 cases of *N. farcinica* infections and

found that it was frequently isolated from pus, bronchial secretions and biopsy specimen. Isolation from blood and urine is rare[10].

N. cyariacigeorgica was first described in 2001 and has been reported from various countries. It has been associated with brain abscess, spinal abscess, cellulitis and septicaemia[9-11]. However, infection caused by two different *Nocardia* species in the same patient is rare. To the best of our knowledge, this is the first case of mixed infection caused by two different *Nocardia* species in same patient. Our patient was immunocompromised due to co-morbidities like diabetes and Cushing's syndrome.

In most of the cases of pulmonary nocardiosis, clinical features are subtle and can often be underdiagnosed[3]. High mortality rates associated with *Nocardia* infections could be due to the delay in the diagnosing the condition which hinders initiation of treatment[5].

The microbiological diagnosis plays a key role in confirmation of nocardiosis as its clinical features often mimic tuberculosis[3].

Nocardiosis requires treatment for several months as it survives intracellularly and multiplies slowly[3]. The drug of choice for *Nocardia* is cotrimoxazole[1]. If the patient is unresponsive to cotrimoxazole, other antibiotics like ceftriaxone, linezolid, imipenem and minocycline can be used[3,6]. Our patient was treated with cotrimoxazole and amikacin based on antimicrobial susceptibility testing report. He showed improvement initially. However, as clinical diagnosis was missed during previous hospitalization and lobectomy was delayed due to financial constraints, he succumbed to his illness. So early diagnosis, prolonged antibiotics and timely surgical intervention are needed for better outcome of nocardiosis.

Conflict of interest statement

The authors declare that they have no conflict of interest.

Ethical approval and consent to participate

The study procedures followed were in accordance with the ethical standards of the Institutional Ethical Committee (BVDUMC/IEC/80). The written informed consent was obtained from the patient's father before the drafting of manuscript.

Funding

The authors received no extramural funding for the study.

Authors' contributions

TVH: Conceptualization, investigation, methodology, validation, visualization, supervision and editing; JP: Data curation, writing original draft preparation; AB: Conceptualization, formal analysis, supervision and editing; MK, AM: Investigation. All authors read and approved the submitted manuscript.

References

[1] Jiao M, Deng X, Yang H, Dong J, Lv J, Li F. Case report: A severe and multi-site *Nocardia farcinica* infection rapidly and precisely identified by metagenomic next-generation sequencing. *Front Med* 2021; **24**(8): 669552.

[2] Zheng SW. Disseminated nocardiosis due to *Nocardia otitidiscaviarum*: A case report and literature review. *Asian Pac J Trop Med* 2019; **12**(4): 185-194.

[3] Duggal SD, Chugh TD. Nocardiosis: A neglected disease. *Med Princ Pract* 2020; **29**(6): 514-523.

[4] Bagüeste G, Porcel JM. Pleural infection caused by *Nocardia farcinica*: Two cases and review of the literature. *Cureus* 2021; 26; **13**(4): e14697.

[5] Rivera K, Maldonado J, Dones A, Betancourt M, Fernández R, Colón M. *Nocardia cyriacigeorgica* threatening an immunocompetent host; a rare case of paramediastinal abscess. *Oxford Med Case Rep* 2017; **12**: omx061. doi: 10.1093/omcr/omx061. eCollection 2017 Dec.

[6] Matulionyte R, Rohner P, Uçkay I, Lew D, Garbino J. Secular trends of *Nocardia* infection over 15 years in a tertiary care hospital. *J Clin Pathol* 2004; **57**(8): 807-812.

[7] Abe S, Tanabe Y, Ota T, Fujimori F, Youkou A, Makino M. Case report: Pulmonary nocardiosis caused by *Nocardia exalbida* in an immunocompetent patient. *BMC Infect Dis* 2021; **21**: 776.

[8] Lee EK, Kim J, Park DH, Lee CK, Kim SB, Sohn JW, et al. Disseminated nocardiosis caused by *Nocardia farcinica* in a patient with colon cancer: A case report and literature review. *Medicine (Baltimore)* 2021; **100**(29): e26682.

[9] Budzik JM, Hosseini M, Mackinnon AC Jr, Taxy JB. Disseminated *Nocardia farcinica*: Literature review and fatal outcome in an immunocompetent patient. *Surg Infect (Larchmt)* 2012; **13**(3): 163-170.

[10] Torres OH, Domingo P, Pericas R, Boiron P, Montiel JA, Vázquez G. Infection caused by *Nocardia farcinica*: Case report and review. *Eur J Clin Microbiol Infect Dis* 2000; **19**(3): 205-212.

[11]Gabay S, Yakubovsky M, Ben-Ami R, Grossman R. *Nocardia cyriacigeorgica* brain abscess in a patient on low dose steroids: A case report and review of the literature. *BMC Infect Dis* 2022; **22**: 635.

Publisher's note

The Publisher of the *Journal* remains neutral with regard to jurisdictional claims in published maps and institutional affiliations.

Edited by Pan Y, Lei Y, Zhang Q