

Letter to Editor

Asian Pacific Journal of Tropical Medicine

apjtm.org

doi: 10.4103/apjtm.apjtm_489_25

# Metagenomic−based rapid identification and phylogenomic tracing of an imported melioidosis case in Beijing, China

Zhichao Liang[1], Fuyu Qiao[2], Xin Zhang[1], Bing Lv[1]✉

[1]*Beiiing Center for Disease Prevention and Control, Beijing 100013, China*

[2]*Xicheng District Center for Disease Control and Prevention, Beijing 100035, China*

Melioidosis is a zoonotic infectious disease caused by *Burkholderia (B.) pseudomallei*. It is predominantly endemic in Southeast Asia[1−3]. Clinical manifestations are often non-specific, commonly presenting as pneumonia or skin abscesses[4], and may progress to severe sepsis with a high case-fatality rate of 10%-50%[5]. Due to its early flu-like symptoms, melioidosis is frequently misdiagnosed by clinicians in non-endemic regions. Beijing, located in the North Temperate Zone, rarely reports melioidosis cases; the lack of awareness among healthcare professionals may lead to misdiagnosis and fatal outcomes.

In June 2023, a hospital in Beijing reported a case involving a 6-year-old male who had traveled to Thailand in May. On 24 May, the patient was stung on both dorsa of the feet by a jellyfish, and the wounds were repeatedly exposed to soil and contaminated water during the trip. That evening, he developed low to moderate fever, which progressed to a high fever of 41.5 ℃ one day later, accompanied by chills, rigors, paroxysmal dry cough, tachypnea, cyanosis, and postprandial vomiting. CT imaging revealed multiple inflammatory nodules in both lungs. Metagenomic next-generation sequencing of bronchoalveolar lavage fluid strongly suggested *B. pseudomallei* (Figure 1). The patient was treated with ceftazidime and meropenem. Subsequent culture and biochemical identification confirmed the pathogen as *B. pseudomallei*, with MLST typing identifying it as ST395-a sequence type not previously reported in China. For source tracing, whole-genome SNP phylogenetic analysis was performed using 144 global *B. pseudomallei* genomes from the NCBI database. The results indicated close genetic relatedness between the isolate and strains from Thailand (Figure 1). A comprehensive diagnosis confirmed an imported case of melioidosis from Thailand.

Metagenomic sequencing played a critical role in diagnosing this imported case, enabling rapid pathogen screening and providing precise microbiological evidence to guide therapy. Further optimization of metagenomic next-generation cost and bioinformatic workflows is recommended for broader application.

With increasing global travel, trade, and climate change-including recent extreme rainfall and wind events in northern China-melioidosis cases are no longer rare in northern regions[6,7]. It is imperative that epidemiologists and clinicians enhance their awareness, diagnostic capability, and management of melioidosis. Strengthening health education for travelers is also essential to mitigate its impact on public health.

## Conflict of interest statement

The authors declare that they have no competing interests.

✉To whom correspondence may be addressed. E-mail: lvbing2001@163.com

This is an open access article distributed under the terms of the Creative Commons Attribution-Non-Commercial-No Derivatives License 4.0 (CCBY-NC-ND), where it is permissible to download and share the work provided it is properly cited. The work cannot be changed in any way or used commercially without permission from the journal.

**For reprints contact:** reprints@medknow.com

©2026 *Asian Pacific Journal of Tropical Medicine* Produced by Wolters Kluwer-Medknow.

**How to cite this article:** Liang ZC, Qiao FY, Zhang X, Lv B. Metagenomic-based rapid identification and phylogenomic tracing of an imported melioidosis case in Beijing, China. Asian Pac J Trop Med 2026; 19(2): 91-93.

**Article history:** Received 27 August 2025 Revision 22 October 2025
Accepted 5 January 2026 Available online 27 January 2026

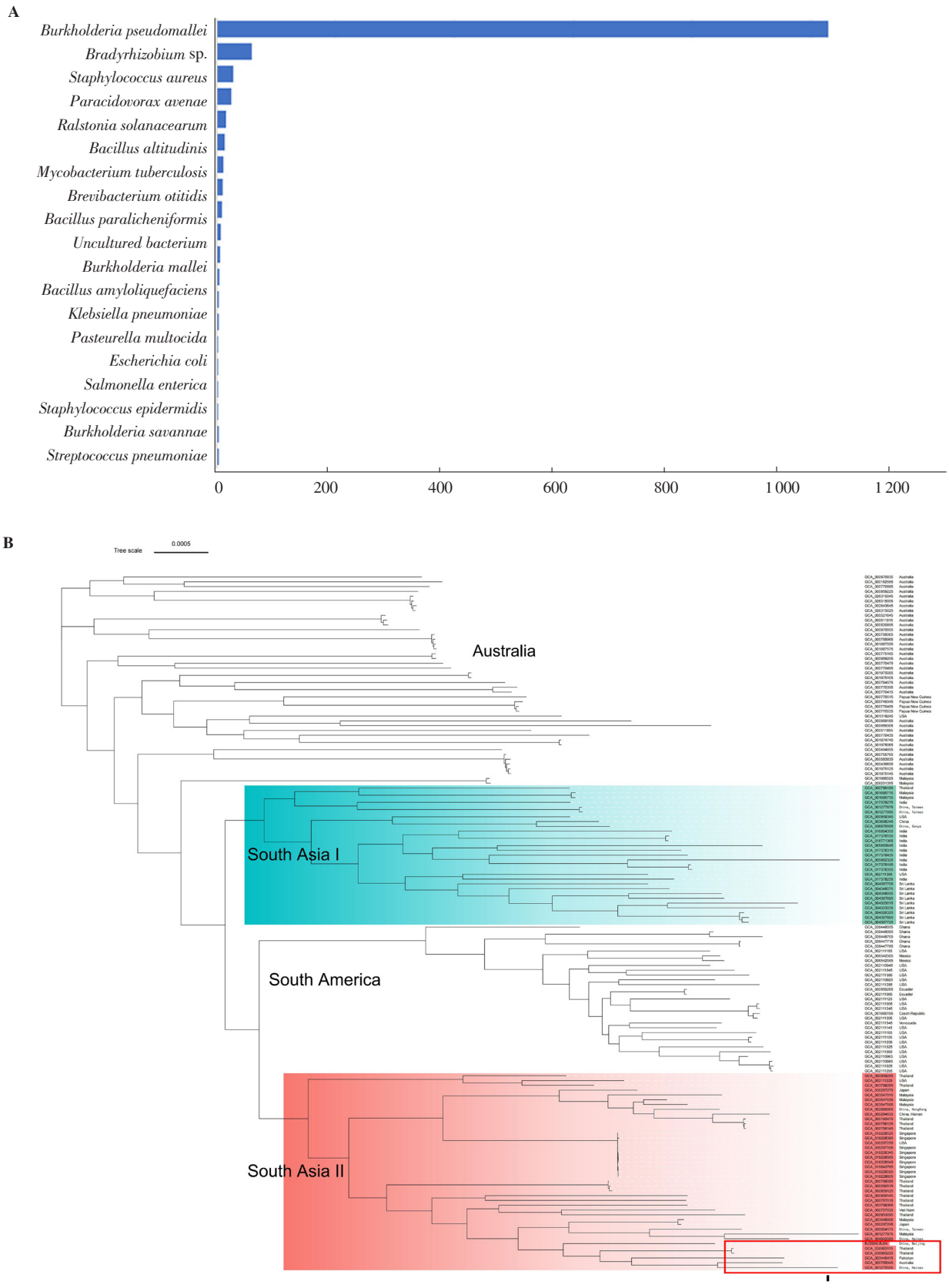


**Figure 1.** Pathogen identification and phylogenetic analysis of *Burkholderia* (*B.*) *pseudomallei* from the imported melioidosis case. A: Pathogen abundance distribution of *de novo* assembled contigs (⩾1 000 bp). The y-axis represents predominant pathogens, and the x-axis indicates their corresponding contig counts; *B. pseudomallei* accounted for 83.9% of total contigs. B: Whole-genome SNP (wgSNP) phylogenetic tree of 145 *B. pseudomallei* strains. The 145 strains were clustered into four clades (Australia, South America, South Asia Ⅰ, South Asia Ⅱ). The Beijing isolate was positioned in the South Asia Ⅱ clade and exhibited a close evolutionary relationship with Thai strains GCA_038983115 and GCA_038983225 (red-outlined clade).

## Ethics approval and consent to participate

Ethical approval for this study was obtained from the Ethics Review Committee of the Chinese Center for Disease Control and Prevention (CDC) (ICDC-LPJ-202408). All experiments were performed in accordance with relevant guidelines and regulations.

## Consent for publication

Written informed consent was obtained from the patient for publication of this report.

## Data availability

The datasets used and/or analyzed during the current study are available from the corresponding author on reasonable request.

## Acknowledgments

We are grateful to the staff from the Xicheng District Center for Disease Control and Prevention for conducting an epidemiological investigation. We also thank the staff from the Beijing Center for Disease Prevention and Control for their laboratory testing support.

## Funding

This work was supported by the Capital's Funds for Health Improvement and Research (2024-1G-4362) and the National Key Program for Infectious Disease of China (2018ZX10714002-003-002).

## Authors' contributions

Z.L. and B.L.: Conceptualization, funding, writing manuscript.; F.Q. and X.Z.: Investigation , data curation & analysis; All authors approved the final manuscript.

## References

[1] Rajesh C, Vaddeswarapu J, Mishra U, Eapen JJ, Thomas A, John EE, et al. Melioidosis in kidney transplant recipients: A report of two cases. *Asian Pac J Trop Med* 2025; **18**(4): 181-184.

[2] Chakravorty A, Heath CH. Melioidosis: An updated review. *Aust J Gen Pract* 2019; **48**: 327-332.

[3] Mohapatra PR, Mishra B. Burden of melioidosis in India and South Asia: Challenges and ways forward. *Lancet Reg Health Southeast Asia* 2022; **2**: 100004.

[4] Bzdyl NM, Moran CL, Bendo J, Sarkar-Tyson M. Pathogenicity and virulence of *Burkholderia pseudomallei*. *Virulence* 2022; **13**: 1945-1965.

[5] Cheng AC, Currie BJ. Melioidosis: Epidemiology, pathophysiology, and management. *Clin Microbiol Rev* 2005; **18**: 383-416.

[6] Chen KY, Ho HP, Lin HH, Hsu BM, Chen YS, Hsu DW, et al. Geographical and climatic contributions to melioidosis hotspot formation in Southern Taiwan. *PLoS Negl Trop Dis* 2025; **19**: e0012958.

[7] Le Tohic S, Montana M, Koch L, Curti C, Vanelle P. A review of melioidosis cases imported into Europe. *Eur J Clin Microbiol Infect Dis* 2019; **38**: 1395-1408.

## Publisher's note

The Publisher of the *Journal* remains neutral with regard to jurisdictional claims in published maps and institutional affiliations.

Edited by Pan Y, Lei Y, Zhang Q