四川大学学报（医学版） 2026，57（3）：657－661
J Sichuan Univ（Med Sci） doi: 10.12182/20260560502

在线全文

腹部无辅助切口经阴道拖出标本的机器人右半结肠癌根治术的临床研究*

刘东宁，周睿辰，肖 锋，胡文俊，何鹏辉，高庚妹，梁亚航，李太原△
南昌大学第一附属医院 胃肠外科（南昌 330006）

【摘要】 **目的** 探讨腹部无辅助切口经阴道拖出标本的机器人右半结肠癌根治术的安全性和可行性。**方法** 纳入2022年1月1日至2025年1月31日在我院接受腹部无辅助切口经阴道拖出标本的机器人右半结肠癌根治术治疗的女性患者22例，通过收集并分析手术时间，术中出血量，中转开腹率，术后并发症，术后30 d死亡率，再入院率（术后30 d内手术相关非计划再入院）等指标评估手术的安全性和可行性。**结果** 手术均顺利完成，手术时间158 min（152 ~ 169 min），术中出血量53 mL（43 ~ 75 mL），无中转开腹，术后首次排气时间53.00 h（49.25 ~ 57.50 h），术后住院时间9.00 d（8.00 ~ 11.00 d），术后出现肠梗阻1例，未见吻合口瘘、吻合口出血、阴道出血、阴道感染、腹腔感染等其余并发症，术后30 d无死亡，也无手术相关非计划再入院。**结论** 腹部无辅助切口经阴道拖出标本的机器人右半结肠癌根治术是安全可行的。

【关键词】 右半结肠癌 机器人手术 经自然腔道取标本手术

Clinical Study of Robotic Natural Orifice Specimen Extraction Surgery for Right Colon Cancer

LIU Dongning, ZHOU Ruichen, XIAO Feng, HU Wenjun, HE Penghui, GAO Gengmei, LIANG Yahang, LI Taiyuan△. *Department of Gastrointestinal Surgery, The First Affiliated Hospital of Nanchang University, Nanchang 330006, China*

△ Corresponding author, E-mail: jylitaiyuan@sina.com

This study was supported by the Jiangxi Provincial Health Commission Science and Technology Program (No. 202210029).

[**Abstract**] **Objective** To evaluate the safety and feasibility of robotic natural orifice specimen extraction surgery (NOSES) for right colon cancer. **Methods** Twenty-two female patients undergoing this procedure between January 1, 2022 and January 31, 2025 were enrolled. Safety and feasibility were assessed by analyzing operative time, intraoperative blood loss, conversion rate to open surgery, postoperative complications, 30-day mortality, and 30-day unplanned surgery-related readmission rate. **Results** All procedures were completed successfully. The median operative time was 158 min (152-169 min), and the median blood loss was 53 mL (43-75 mL). No conversions to open surgery occurred. The first postoperative flatus occurred at a median of 53.00 h (49.25-57.50 h), and the median postoperative hospital stay was 9.00 d (8.00-11.00 d). Postoperative complications included one case of intestinal obstruction. No anastomotic leakage, anastomotic bleeding, vaginal hemorrhage, vaginal infection, or abdominal infection was observed. There were no deaths within 30 days and no unplanned surgery-related readmissions. **Conclusion** Robotic NOSES for right colon cancer is safe and feasible.

[**Key words**] Right colon cancer Robotic surgery Natural orifice specimen extraction surgery

近年来，经自然腔道取标本手术（natural orifice specimen extraction surgery, NOSES）因其无辅助切口、疼痛轻、术后恢复快等优势，已成为结直肠外科的研究热点[1-2]。同时，机器人手术平台凭借其3D高分辨率的手术视野、机械臂操控灵活精准等优势，在结直肠外科应用越来越广泛[3-5]。机器人结直肠肿瘤NOSES是利用机器人手术平台开展NOSES，充分利用上述两大技术优势，有望成为结直肠外科主流技术之一[6-8]。目前，腹部无辅助切口经阴道拖出标本的机器人右半结肠癌根治术（R-CRC-NOSES Ⅷ A法）在我国开展例数很少。因此，本研究将通过分析22例接受R-CRC-NOSES Ⅷ A法治疗的右半结肠癌女性患者的临床资料，评估该术式的安全性和可行性。

1 资料与方法

1.1 研究对象

本研究纳入2022年1月1日–2025年1月31日在南昌大学第一附属医院接受R-CRC-NOSES Ⅷ A法治疗的女性

* 江西省卫生健康委科技计划（No. 202210029）资助
△ 通信作者，E-mail: jylitaiyuan@sina.com
出版日期：2026-05-20

患者。纳入标准:①年龄18 ~ 80岁;②ECOG评分≤2分;③组织或细胞学证实为右半结肠腺癌;④术前分期:$T_{1\text{-}3}N_0M_0$;⑤经直肠 NOSES术的标本环周直径< 3 cm,经阴道NOSES术的标本环周直径3 ~ 5 cm;⑥术前检查未提示转移或种植、侵犯相邻器官;⑦心肺肝肾功能能够耐受手术;⑧签署知情同意书。排除标准:①不适于行机器人腹腔镜手术者;②肿瘤过大,无法经肛门或阴道拖出者;③过于肥胖,体质量指数(body mass index, BMI)≥30 kg/m^2;④右半结肠系膜过于肥厚,判定经肛门或阴道拖出困难者;⑤同时性多原发癌;⑥肿瘤致肠道梗阻或穿孔;⑦严重精神疾病病史;⑧合并肛周疾病或肛门狭窄者;⑨合并妇科急性感染、阴道畸形或未婚未育以及已婚计划再育的女性。共纳入22例患者,中位年龄60岁(50 ~ 69岁),术前肠镜均可通过,患者及家属均知情同意并签署同意书。本研究已经南昌大学第一附属医院医学伦理委员会审查批准,批准号IIT【2023】临伦审第204号。

1.2 手术操作

1.2.1 术中患者体位

患者取改良截石位,头低脚高,左倾卧位,适当降低右腿高度,防止与机械臂碰撞[9]。

1.2.2 Trocar孔

机械臂操作孔R1:右侧麦氏点,直径8 mm;机械臂操作孔R2:正中线耻骨联合上方7 cm,直径8 mm;镜头孔R3:脐左下方3 cm,直径8 mm;机械臂操作孔R4:左锁骨中线与肋弓交点下7 cm,直径8 mm;辅助孔A:R4下方7 cm,直径12 mm。镜头孔R5:脐上3 cm,直径8 mm,取标本时使用[9]。

1.2.3 进机

使用机械臂操作孔R1、R2、R4,镜头孔R3及辅助孔A,机械臂系统安置于右侧肩部,其中线经过镜头孔R3,并与右肩成45°[9](图1)。

1.2.4 淋巴结清扫与右半结肠游离

所有手术均采用中间入路,在回结肠动静脉(ICA/ICV)投影与肠系膜静脉(SMV)之间的三角区域切开右结肠系膜,进入右侧Toldt间隙,充分裸化ICA、ICV直至汇入肠系膜上动静脉(SMA/SMV)处,沿途清扫此路径淋巴结及脂肪组织,于根部用Hem-o-lock夹闭ICA、ICV(图2)。

打开血管鞘,沿SMA、SMV向上游离,在右结肠动脉(RCA)分支水平清扫肠系膜上淋巴结并夹闭该动脉,继续向上游离,暴露结肠中动静脉(MCA/MCV)及其左右两分支,对于盲肠癌及升结肠癌,仅离断MCA/MCV右支,对于结肠肝曲癌及横结肠近端癌,离断MCA/MCV主干。沿SMV前方向上游离,裸化至Henle干水平,清扫血管周围淋巴结。将右结肠静脉(RCV)、副右结肠静脉(SRCV)、胃网膜右静脉(RGEV)充分游离,于静脉根部用Hem-o-lock夹闭。游离胃网膜右动脉(RGEA),于RGEA根部使用Hem-o-lock夹及钛夹夹闭(图3)。

自SMV右侧进入Toldt筋膜与Gerota筋膜间隙向头侧游离,直至十二指肠水平部及胰头前方,向尾侧及外侧游离直至腹膜返折处,将结肠系膜前后叶及系膜内淋巴脂肪组织完整切除。对盲肠癌及升结肠癌,从胃网膜血管弓外切开胃结肠韧带,进入大网膜囊,沿胃大弯分离横结肠系膜前叶,向右拓展至肝结肠韧带,向下拓展至胰腺下缘固有筋膜表面。对于结肠肝曲癌及横结肠近端癌,在

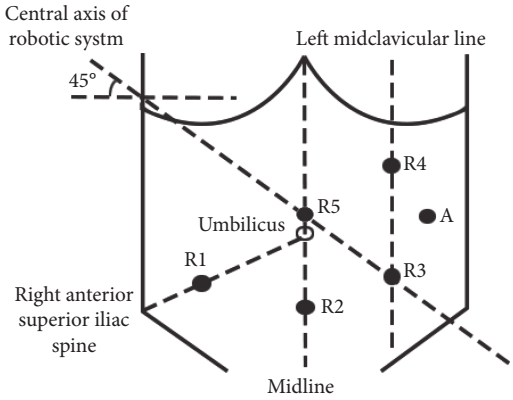

图 1 淋巴结清扫时Trocar孔位置及进机方向

Fig 1 The position of the trocar hole and the direction of insertion during lymph node dissection

R1: robotic arm operation hole, located at the right McBurney's point, diameter 8 mm; R2: robotic arm operation hole, located 7 cm above the pubic symphysis on the midline, diameter 8 mm; R3: camera hole, located 3 cm to the left of the umbilicus, diameter 8 mm; R4: robotic arm operation hole, located 7 cm below the intersection of the left midclavicular line and the costal arch, diameter 8 mm; A: auxiliary hole, located 7 cm below R4, diameter 12 mm; R5: camera hole, located 3 cm above the umbilicus, diameter 8 mm, used for specimen retrieval.

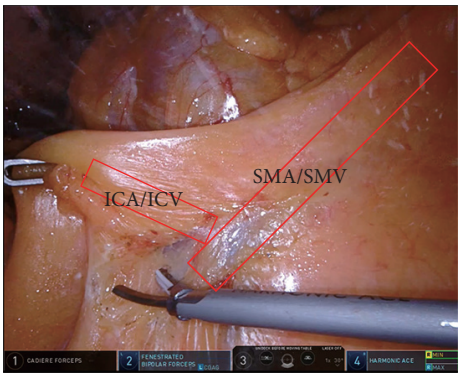

图 2 打开右结肠系膜

Fig 2 Developing the right colonic mesentery

ICA: ileocolic artery; ICV: ileocolic vein; SMA/SMV: superior mesenteric artery/superior mesenteric vein.

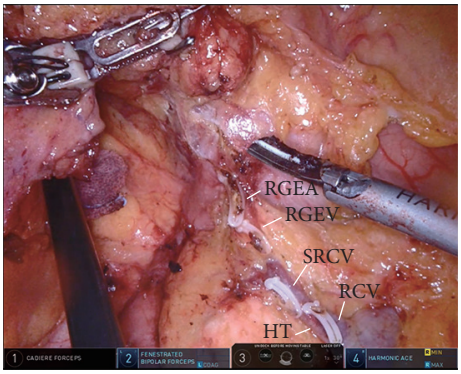

图 3 Henle干血管的处理

Fig 3 Management of Henle's trunk vasculature

RCV: right colic vein; SRCV: superior right colic vein; RGEV: right gastroepiploic vein; RGEA: right gastroepiploic artery; HT: Henle trunk.

胃大弯血管弓内切除右胃结肠韧带，并清扫幽门下淋巴结群。沿肝脏下缘及右Gerota筋膜表面，离断肝结肠韧带和右膈结肠韧带，向下切开右侧侧腹膜。在壁腹膜与右结肠浆肌层结合部切开侧腹膜，沿右结肠旁沟向上游离，与上方解剖平面会合[10-12]。

1.2.5 消化道重建

根据肿瘤位置决定切除肠段，充分游离结肠系膜和回肠系膜，在回肠、结肠各剪一小口，彻底消毒肠腔及切口后用60 mm直线切割闭合器行回结肠侧侧吻合，并使用薇乔线加固吻合口(图4)。

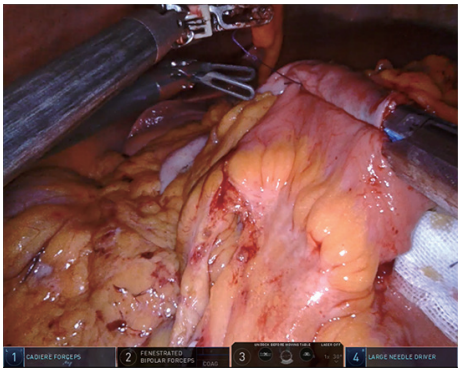

图 4 回结肠侧侧吻合

Fig 4 Ileocolic side-to-side anastomosis

用60 mm直线切割闭合器离断结肠和回肠，断端用薇乔线加固。无菌保护套经助手孔A置入，将标本装入无菌保护套，并使用Hem-o-lock夹扎紧袋口。

1.2.6 取标本

加大头高脚低的幅度，使用机械臂操作孔R1、R3，镜头孔R5，助手孔A[9](图5)。

使用荷包线经腹壁悬吊子宫，碘伏水充分冲洗阴道，用50 mL注射器活塞经阴道顶起阴道后穹窿。超声刀横行切开阴道后穹窿。经阴道用卵圆钳夹住标本袋拖出

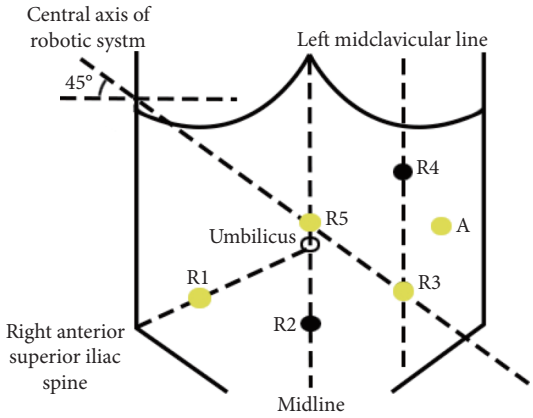

图 5 取标本时Trocar孔位置（黄色标记）

Fig 5 Trocar ports for specimen extraction (yellow markings)

体外。使用薇乔线经盆腔连续全层缝合关闭阴道切口(图6)。

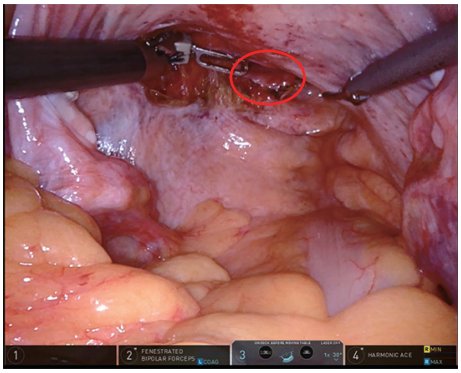

图 6 打开阴道后穹窿

Fig 6 Incision of the posterior vaginal fornix

1.2.7 引流管置入及关腹

使用蒸馏水冲洗腹腔、盆腔，置入28 mm直径双套管1根于右肝下结肠旁沟，20 mm橡皮引流管1根于盆腔，缝合各Trocar孔。

1.3 检测指标

收集手术时间，术中出血量，中转开腹率，术后住院时间，术后并发症情况，术后30 d死亡率，再入院率(术后30 d内手术相关非计划再入院)等指标。通过分析所收集指标评估腹部无辅助切口经阴道拖出标本的机器人右半结肠癌根治术的安全性和可行性。

1.4 统计学方法

正态分布数据采用$\bar{x} \pm s$，非正态分布数据采用中位数(最小值～最大值)和百分率形式表示。

2 结果

2.1 患者基本资料

所有患者均为右半结肠腺癌，其中$pT_2N_0M_0$ 1例，

$pT_3N_0M_0$ 12例, $pT_3N_1M_0$ 9例; 回盲部腺癌2例, 升结肠腺癌15例, 结肠肝曲腺癌4例, 横结肠近端腺癌1例。肿瘤最大直径4.6 cm(3.8 ~ 4.9 cm)。

2.2 患者围手术期指标

手术均顺利完成, 手术中位时间158 min, 术中中位出血量53 mL, 无患者术中转开腹, 术后首次排气中位时间53.00 h, 术后住院中位时间9.00 d, 无术后30 d死亡病例, 也无患者术后30 d内手术相关非计划再入院(表1), 1例患者术后出现肠梗阻, 经禁食、补液、胃肠减压等措施治疗后顺利出院, 未见吻合口瘘、吻合口出血、阴道出血、阴道感染、腹腔感染等其余并发症。基于这22例病例的观察结果, R-CRC-NOSES Ⅷ A法是安全可行的。

表 1 围术期指标

Table 1 Perioperative outcomes

Parameter	Value (n = 22)
Operative time/min, median (IQR)	158 (152-169)
Intraoperative blood loss/mL, median (IQR)	53 (43-75)
Conversion rate to open surgery/case	0
Patient first exhaust time/h, median (IQR)	53.00 (49.25-57.50)
Postoperative hospital stay/d, median (IQR)	9.00 (8.00-11.00)
Death within 30 days after the operation/case	0
Readmission within 30 days after the surgery/case	0

3 讨论

自结直肠肿瘤NOSES手术应用于临床以来, 多项研究表明: 与传统经腹部辅助切口取标本的手术方式相比, 结直肠肿瘤NOSES手术具有手术时间短、术后肠道功能恢复快(表现为首次排气及经口进食时间提前)、切口并发症发生率低及术后疼痛轻等优势[13-14]。然而, 目前关于经阴道取标本手术的报道主要集中于直肠癌领域[14-15], 针对机器人辅助下腹部无辅助切口经阴道拖出标本的右半结肠癌根治术(R-CRC-NOSES Ⅷ A法)的临床研究目前仍然少见。本研究纳入的22例接受R-CRC-NOSES Ⅷ A法手术的女性患者, 手术均顺利完成, 无中转开腹, 术后均顺利恢复。

在整个围手术期, 特别是手术过程中, 需严格遵守无菌无瘤原则[16]。本团队在完成22例R-CRC-NOSES Ⅷ A法手术后, 有以下四点经验体会: 第一, 术前需做好充分的肠道准备; 第二, 回肠和结肠切开时, 需在切开的肠管下垫一块纱布。回肠和结肠切开后, 立即用碘伏纱布擦拭消毒肠腔; 第三, 围手术期需做好充分的阴道准备。术前3 d每日使用碘伏水冲洗阴道1次。切开阴道后穹窿前, 用碘伏水充分冲洗阴道。切开阴道后穹窿后, 应立即用碘伏水冲洗阴道切口。术后用碘伏水冲洗阴道1次; 第四, 关腹前使用无菌蒸馏水冲洗盆腹腔, 分别在右结肠旁沟和盆腔各放置引流管1根, 用于术后冲洗。

然而, R-CRC-NESOS Ⅷ A法手术目前仍处于探索阶段, 其推广普及面临以下挑战: 首先, 患者对于经阴道取标本手术方式的接受度是一大挑战; 其次, 该术式受限于患者自身条件, 如存在子宫内膜异位症、阴道狭窄、病态肥胖或肿瘤体积过大等情况, 可能导致经阴道取标本失败[17]。因此, 在开展此术式的初期阶段, 应严格筛选病例, 选择解剖条件适宜、手术难度较低且患者接受度高的病例, 术中若遇标本取出困难, 应及时采用辅助切口取出标本, 以确保手术安全。

* * *

作者贡献声明 刘东宁负责经费获取和监督指导, 周睿辰负责初稿写作, 肖锋和胡文俊负责正式分析, 何鹏辉负责研究方法, 高庚妹负责验证, 梁亚航负责可视化, 李太原负责论文构思和审读与编辑写作。所有作者已经同意将文章提交给本刊, 且对将要发表的版本进行最终定稿, 并同意对工作的所有方面负责。

Author Contribution LIU Dongning is responsible for funding acquisition and supervision. ZHOU Ruichen is responsible for writing--original draft. XIAO Feng and HU Wenjun are responsible for formal analysis. HE Penghui is responsible for methodology. GAO Gengmei is responsible for validation. LIANG Yahang is responsible for visualization. LI Taiyuan is responsible for conceptualization and writing--review and editing. All authors consented to the submission of the article to the Journal. All authors approved the final version to be published and agreed to take responsibility for all aspects of the work.

利益冲突 所有作者均声明不存在利益冲突

Declaration of Conflicting Interests All authors declare no competing interests.

参 考 文 献

[1] 王锡山. 中国NOSES面临的挑战与展望. 中华结直肠疾病电子杂志, 2018, 7(1): 2-7. doi: 10.3877/cma.j.issn.2095-3224.2018.01.001.
WANG X S. Current challenges and prospects of NOSES in China. Chinese Journal of Colorectal Diseases (Electronic Edition), 2018, 7(1): 2-7. doi: 10.3877/cma.j.issn.2095-3224.2018.01.001.

[2] 关旭, 焦帅, 黄海洋, 等. 中国经自然腔道取标本手术开展现状分析. 中华结直肠疾病电子杂志, 2021, 10(2): 122-131. doi: 10.3877/cma.j.issn.2095-3224.2021.02.003.
GUAN X, JIAO S, HUANG H Y. An investigation report on the current situation of natural orifice specimen extraction surgery in China. Chinese Journal of Colorectal Diseases (Electronic Edition), 2021, 10(2): 122-131. doi: 10.3877/cma.j.issn.2095-3224.2021.02.003.

[3] LU J, LI T Y, ZHANG L, *et al*. Comparison of short-term and three-year oncological outcomes between robotic and laparoscopic gastrectomy for gastric cancer: a large multi-center cohort study. Ann Surg, 2024, 279(5): 808-817. doi: 10.1097/SLA.0000000000006215.

[4] 刘东宁, 熊凌强, 邹震, 等. 机器人与腹腔镜右半结肠切除术近期疗效对照研究. 中国实用外科杂志, 2016, 36(11): 1187-1189. doi: 10.7504/

CJPS.ISSN1005-2208.2016.11.13.
LIU D N, XIONG L Q, ZOU Z, *et al*. Contrast study of short- term effect between the da Vinci surgical robot and laparoscopic technology in righthemicolectomy for colon carcinoma. Chinese Journal of Practical Surgery, 2016, 36(11): 1187-1189. doi: 10.7504/CJPS.ISSN1005-2208.2016.11.13.

[5] 许剑民, 常文举, 鉴谧. 达芬奇机器人直肠癌根治术的现状和发展. 中华普外科手术学杂志(电子版), 2020, 14(1): 9-12. doi: 10.3877/cma.j.issn.1674-3946.2020.01.003.
XU J M, CHANG W J, JIAN M. Updates and prospect of da Vinci robotic surgical system in radical resection of rectal cancer. Chinese Journal of Operative Procedures of General Surgery (Electronic Edition), 2020, 14(1): 9-12. doi: 10.3877/cma.j.issn.1674-3946.2020.01.003.

[6] 汤庆超, 王锡山. 浅谈应用达芬奇机器人手术平台开展直肠癌NOSES手术的优越性和局限性. 中华结直肠疾病电子杂志, 2021, 10(4): 343-350. doi: 10.3877/cma.j.issn.2095-3224.2021.04.002.
TANG Q C, WANG X S. On the superiority and limitations of applying the da Vinci robotic surgical platform to perform NOSES surgery for rectal cancer. Chinese Journal of Colorectal Diseases (Electronic Edition), 2021, 10(4): 343-350. doi: 10.3877/cma.j.issn.2095-3224.2021.04.002.

[7] 叶善平, 吴灿, 李太原. 机器人手术系统右半结肠切除经自然腔道取标本机器人手术系统方式选择与质量控制. 临床外科杂志, 2024, 32(5): 463-465. doi: 10.3969/j.issn.1005-6483.2024.05.005.

[8] 武琦, 陈伊教, 朱德祥, 等. 机器人辅助直肠癌切除经自然腔道取标本手术(NOSES)联合多脏器切除术的应用. 中华结直肠疾病电子杂志, 2021, 10(6): 654-658. doi: 10.3877/cma.j.issn.2095-3224.2021.06.014.
WU Q, CHEN Y J, ZHU D X, *et al*. The application of robot-assisted natural orifice specimen extraction surgery in the combined with multiple organ resection in rectal cancer. Chinese Journal of Colorectal Diseases (Electronic Edition), 2021, 10(6): 654-658. doi: 10.3877/cma.j.issn.2095-3224.2021.06.014.

[9] 中国NOSES联盟, 中国医师协会结直肠肿瘤专业委员会NOSES学组, 中国医师协会结直肠肿瘤专业委员会机器人手术学组, 等. “机器人”结直肠肿瘤经自然腔道取标本手术专家共识(2025版). 中华结直肠疾病电子杂志, 2025, 14(3): 202. doi: 10.3877/cma.j.issn.2095-3224.2025.03.002.
China Natural Orifice Specimen Extraction Surgery (NOSES) Alliance, The Group of NOSES, Colorectal Cancer Professional Committee of the Chinese Medical Doctor Association, The Group of Robotic Surgery, Colorectal Cancer Professional Committee of the Chinese Medical Doctor Association, *et al*. Expert consensus on robotic natural orifice specimen extraction surgery for colorectal neoplasm (2025 Edition). Chinese Journal of Colorectal Diseases (Electronic Edition), 2025, 14(3): 202. doi: 10.3877/cma.j.issn.2095-3224.2025.03.002.

[10] 池畔, 陈致奋. 腹腔镜右半结肠癌根治术解剖学基础与规范化手术. 中华普外科手术学杂志(电子版), 2015, 9(1): 7-13. doi: 10.3877/cma.j.issn.1674-3946.2015.01.003.
CHI P, CHEN Z F. The"membrane" anatomical understanding and the surgical value of laparoscopic caudal-to-cranial approach for radical right hemicolectomy. Chinese Journal of Operative Procedures of General Surgery (Electronic Edition), 2015, 9(1): 7-13. doi: 10.3877/cma.j.issn.1674-3946.2015.01.003.

[11] 林锋, 李勇. 腹腔镜右半结肠癌根治术. 中国实用外科杂志, 2011, 31(9): 861-866.

[12] 郑民华, 何子锐. 腹腔镜右半结肠癌根治术的热点与未来发展. 中华普外科手术学杂志(电子版), 2019, 13(5): 433-436. doi: 10.3877/cma.j.issn.1674-3946.2019.05.001.
ZHENG M H, HE Z R. Focus and future of laparoscopic radical resection of right colon cancer. Chinese Journal of Operative Procedures of General Surgery (Electronic Edition), 2019, 13(5): 433-436. doi: 10.3877/cma.j.issn.1674-3946.2019.05.001.

[13] LIU D, HE G, YAO H, *et al*. Robotic natural orifice specimen extraction surgery versus robotic transabdominal specimen extraction surgery for early-stage rectal cancer: a multicenter propensity score-matched analysis. Surg Endosc, 2024, 38(8): 4521-4530. doi: 10.1007/s00464-024-10995-5.

[14] ZHANG Z C, LUO Q F, WANG W S, *et al*. Development and future perspectives of natural orifice specimen extraction surgery for gastric cancer. World J Gastrointest Surg, 2022, 14(11): 1198-1203. doi: 10.4240/wjgs.v14.i11.1198.

[15] TANG Q, ZHU Y, XIONG H, *et al*. Natural orifice specimen extraction surgery versus conventional laparoscopic-assisted resection in the treatment of colorectal cancer: a propensity-score matching study. Cancer Manag Res, 2021, 13: 2247-2257. doi: 10.2147/cmar.s291085.

[16] 中国医师协会结直肠肿瘤专业委员会, 中国抗癌协会大肠癌专业委员会, 中国NOSES 联盟. 结直肠肿瘤经自然腔道取标本手术指南(2023版). 中华结直肠疾病电子杂志, 2023, 12(2): 89-99. doi: 10.3877/cma.j.issn.2095-3224.2023.02.001.
Colorectal Cancer Professional Committee of the Chinese Medical Doctor Association, Colorectal Cancer Professional Committee of the China Anti-Cancer Association, China NOSES Alliance. Guidelines for natural orifice specimen extraction surgery in colorectal neoplasm (V. 2023). Chinese Journal of Colorectal Diseases (Electronic Edition), 2023, 12(2): 89-99. doi: 10.3877/cma.j.issn.2095-3224.2023.02.001.

[17] ASTI E, BONAVINA L. Short-term efficacy of transvaginal specimen extraction for right colon cancer based on propensity score matching: a retrospective cohort study. Int J Surg, 2019, 70: 28-29. doi: 10.1016/j.ijsu.2019.08.008.

（2025 – 07 – 30收稿, 2025 – 10 – 20修回）

编辑　汤　洁

开放获取　本文使用遵循知识共享署名—非商业性使用4.0国际许可协议（CC BY-NC 4.0），详细信息请访问https://creativecommons.org/licenses/by-nc/4.0/。

OPEN ACCESS　This article is licensed for use under Creative Commons Attribution-NonCommercial 4.0 International license (CC BY-NC 4.0). For more information, visit https://creativecommons.org/licenses/by-nc/4.0/.

© 2026《四川大学学报(医学版)》编辑部

Editorial Office of *Journal of Sichuan University (Medical Sciences)*