

apjtm.org

Perspective

Asian Pacific Journal of Tropical Medicine

doi: 10.4103/apjtm.apjtm_174_26

Microscopy and molecular approaches: A combined diagnostic framework for malaria surveillance in Malaysia

Kumuthamalar Sangaran[1,2], Si Jie Goh[3], Ameera Aleeshya Mohd Fadrul Izwan[3], Guan Min Wee[4], Zulkarnain Md Idris[1]✉

[1]*Department of Parasitology and Medical Entomology, Faculty of Medicine, Universiti Kebangsaan Malaysia, Cheras, Kuala Lumpur, Malaysia*

[2]*National Public Health Laboratory, Ministry of Health, Sungai Buloh, Selangor, Malaysia*

[3]*Faculty of Applied Sciences, UCSI University, Cheras, Kuala Lumpur, Malaysia*

[4]*Faculty of Medicine, AIMST University, Bedong, Kedah, Malaysia*

By 2024, Malaysia achieved a significant public health milestone by marking its seventh consecutive year without a single local transmission of indigenous human *Plasmodium* species. The country has sustained elimination of non-zoonotic malaria, primarily caused by *Plasmodium (P.) falciparum* and *P. vivax*, while remaining vigilant against imported and introduced cases driven by cross-border movement and international travel. However, despite this achievement, Malaysia has emerged as the global epicentre of zoonotic for *P. knowlesi*. In 2021 alone, 3 575 cases of *P. knowlesi* and 13 deaths were reported[1], underscoring the shifting epidemiology of malaria in the country. The growing convergence of habitats shared by humans, non-human primates and mosquito vectors, together with ongoing land-use changes, has contributed to the rising incidence of zoonotic malaria[1]. The World Health Organization (WHO) further indicates that countries such as Malaysia, are unlikely to achieve malaria elimination if the burden of *P. knowlesi* cases remains persistently high[2].

The rise of *P. knowlesi* has necessitated a strategic transition in national malaria control efforts, with greater emphasis on surveillance and diagnostic precision. A key challenge lies in the continued reliance on microscopy as the gold standard for rapid clinical diagnosis. Although microscopy is widely accessible and cost-effective, distinguishing *P. knowlesi* morphologically remains difficult, as it closely mimics the early stages of *P. falciparum* and the later stages of *P. malariae*[3]. Consequently, definitive species identification increasingly depends on molecular methods. In response, the Ministry of Health Malaysia established the National Malaria Molecular Surveillance Programme (NMMSP), which integrated polymerase chain reaction (PCR), genotyping and gene sequencing to improve species confirmation, classifying cases by origin, monitoring drug resistance and supporting outbreak investigations[4].

This diagnostic transition is reflected in the evolving landscape of malaria epidemiological research in Malaysia. There were 31 published malaria epidemiological studies in Malaysia indexed in PubMed and Scopus from 2011 to 2025 (Figure 1). Most studies adopted combined diagnostic approaches, particularly microscopy with PCR (n=16), followed by microscopy with PCR and serology (n=5), and microscopy with PCR and rapid diagnostic tests (RDTs) (n=4). In contrast, reliance on single diagnostic methods was limited (Figure 1). This trend highlights the complementary strengths of microscopy and molecular tools, particularly in the context of malaria elimination, where parasite densities are often low and submicroscopic infections are common[5,6].

Microscopy remains indispensable for routine surveillance, especially in rural and resource-limited settings. It enables visualisation of parasite morphology and quantification of parasitaemia, making it practical, portable and cost-effective for field use. However, its diagnostic accuracy depends heavily on operator expertise and is constrained by reduced sensitivity at low parasite densities[7]. Moreover, morphological similarities among *Plasmodium* species, particularly between *P. knowlesi* and *P.*

✉To whom correspondence may be addressed. E-mail: zulkarnain.mdidris@ukm.edu.my

This is an open access article distributed under the terms of the Creative Commons Attribution-Non-Commercial-No Derivatives License 4.0 (CCBY-NC-ND), where it is permissible to download and share the work provided it is properly cited. The work cannot be changed in any way or used commercially without permission from the journal.

For reprints contact: reprints@medknow.com

©2026 *Asian Pacific Journal of Tropical Medicine* Produced by Wolters Kluwer-Medknow.

How to cite this article: Sangaran K, Goh SJ, Mohd Fadrul Izwan AA, Wee GM, Idris ZM. Microscopy and molecular approaches: A combined diagnostic framework for malaria surveillance in Malaysia. Asian Pac J Trop Med 2026; 19(5): 193-195.

Article history: Received 19 April 2026 Revision 19 May 2026
Accepted 25 May 2026 Available online 29 May 2026

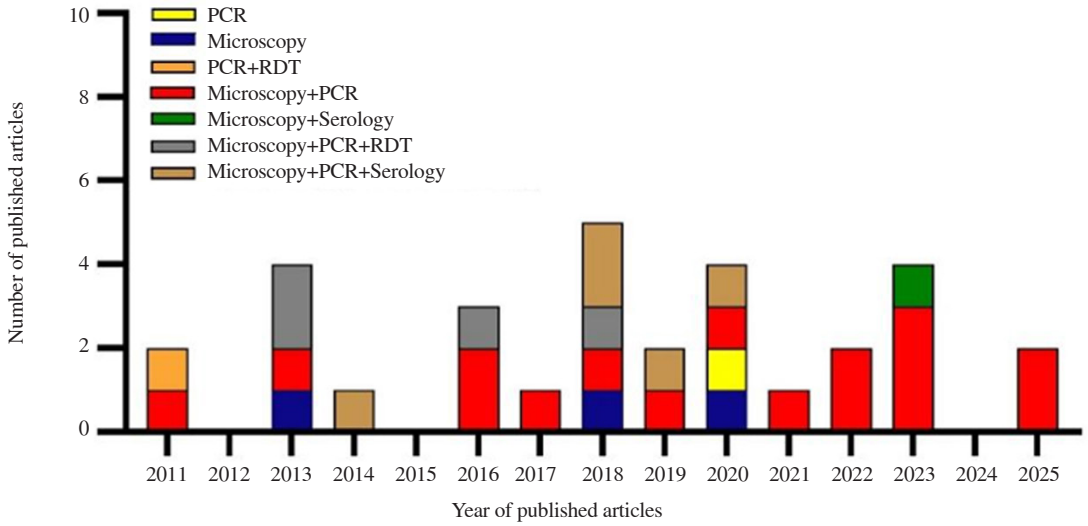

Figure 1. Number of published malaria epidemiological studies in Malaysia indexed in PubMed and Scopus from 2011 to 2025. A systematic search of both database using relevant keywords ("malaria" OR "malari*" OR "plasmodium" OR "malaria transmission" OR "malaria exposure") AND ("malaysia" OR "sabah" OR "sarawak") AND ("epidemiolog*" OR "prevalence" OR "incidence" OR "cross-section*" OR "cohort" OR "surveillance" OR "distribution" OR "transmission" OR "exposure") identified a total of 31 studies conducted in malaria-affected communities, employing various malaria diagnostic approaches, including single methods and combinations of methods. PCR: polymerase chain reaction; RDT: rapid diagnostic test.

malariae, pose significant challenges for accurate identification[2]. This limitation is further illustrated by the first reported human infection of *P. cynomolgi* in Malaysia, which was initially misidentified as *P. vivax* by microscopy but later confirmed by PCR[8]. In contrast, molecular methods such as PCR offer superior sensitivity and specificity. They can detect low-level and submicroscopic infections, identify mixed-species infections and accurately differentiate morphologically similar parasites. These capabilities are critical for surveillance in low-transmission settings and for understanding the true burden of zoonotic malaria. However, PCR-based methods are resource-intensive, require specialized laboratory infrastructure, and do not provide direct information on parasite density or morphology[9]. As such, they are less suited for immediate clinical decision-making in field settings.

The increasing preference for integrated diagnostic approaches in Malaysia reflects the need to balance these strengths and limitations. Combining microscopy and PCR enables both quantitative and qualitative assessment of malaria infections, thereby improving diagnostic accuracy and surveillance sensitivity[7]. The addition of serological tools, for example, can further enhance epidemiological insights by capturing historical and recent exposure, which is particularly valuable in near-elimination settings where transmission is heterogeneous and often cryptic[10]. Furthermore, maintaining Malaysia's malaria-free status for human-only species while addressing the growing threat of zoonotic malaria requires a comprehensive and adaptive strategy. Sustained investment in microscopy training and competency assessment is essential, particularly in low-transmission settings where diagnostic skills may decline due to reduced case exposure. At the same time, molecular diagnostics should be institutionalized as a reference standard in regions with emerging zoonotic transmission to ensure accurate species identification and detection of mixed infections.

In conclusion, Malaysia's experience underscores the importance of integrating conventional and advanced diagnostic tools in malaria surveillance. The synergy between microscopy, molecular methods, and potential use of serology not only strengthens diagnostic accuracy but also provides a robust, data-driven framework for malaria control in the context of zoonotic transmission. As the country moves beyond elimination towards sustained prevention of reintroduction, such integrated approaches will be critical in addressing the evolving challenges of malaria epidemiology.

Conflict of interest statement

We declare that there is no conflict of interest.

Funding

It was supported by the Geran Fundamental Fakulti Perubatan (FF-2025-202), Universiti Kebangsaan Malaysia.

Authors' contributions

The conceptualization was done by KS and ZMI. The literature and drafting of the manuscript were conducted by KS, SJG, AAMFI and GMW. The editing and supervision were performed by ZMI. All authors have read and agreed to the final version of the manuscript.

References

[1] Muhammad AB, Azman EN, Eddie NA, Azmi NI, Yee VCT, Idris ZM. The rise of *Plasmodium knowlesi* cases: Implication to Malaysia's malaria-free status. *Asian Pac J Trop Med* 2022; **15**(8): 337-338.

[2] World Health Organization. *World malaria report 2024*. [Online]. Available from: https://www.who.int/teams/global-malaria-programme/reports/world-malaria-report-2024. [Accessed on 12 March 2026].

[3] Dian ND, Rahim MAFA, Chan S, Idris ZM. Non-human primate malaria infections: A review on the epidemiology in Malaysia. *Int J Environ Res Public Health* 2022; **19**(13): 7888.

[4] Ministry of Health Malaysia. *Guidelines for malaria vector control in Malaysia 2022*. [Online]. Available from: https://www.moh.gov.my/penerbitan-dan-laporan/dasar-akta-polisi-garis-panduan/garis-panduan-umum-kkm/senarai-garis-panduan-umum-awam/guidelines-for-malaria-vector-control-in-malaysia-1st-edition. [Accessed on 15 March 2026].

[5] Dian ND, Muhammad AB, Azman EN, Eddie NA, Azmi NI, Yee VCT, et al. Evidence of submicroscopic *Plasmodium knowlesi* mono-infection in remote indigenous communities in Kelantan, Peninsular Malaysia. *Am J Trop Med Hyg* 2023; **109**(5): 1081-1085.

[6] Abdull-Majid N, Yap NJ, Tee MZ, Er YX, Ngui R, Lim YA. Evidence of submicroscopic malaria parasitemia, soil-transmitted helminths, and their coinfections among forest-fringed Orang Asli communities in Peninsular Malaysia. *Am J Trop Med Hyg* 2025; **112**(6): 1391-1399.

[7] Rahim MAFA, Munajat MB, Idris ZM. Malaria distribution and performance of malaria diagnostic methods in Malaysia (1980-2019): A systematic review. *Malar J* 2020; **19**(1): 395.

[8] Dian ND, Rahim, Rahim MAFA, Idris ZM. *Plasmodium cynomolgi*: An emerging threat of zoonotic malaria species in Malaysia? *Asian Pac J Trop Med* 2022; **15**(1): 4-6.

[9] Opoku Afriyie S, Addison TK, Gebre Y, Mutala AH, Antwi KB, Abbas DA, et al. Accuracy of diagnosis among clinical malaria patients: Comparing microscopy, RDT and a highly sensitive quantitative PCR looking at the implications for submicroscopic infections. *Malar J* 2023; **22**(1): 76.

[10]Rahim MAFA, Munajat MB, Dian ND, Seri Rakna MIM, Wahid W, Ghazali N, et al. Naturally acquired antibody response to *Plasmodium falciparum* and *Plasmodium vivax* among indigenous Orang Asli communities in Peninsular Malaysia. *Front Cell Infect Microbiol* 2023; **13**: 1165634.

Publisher's note

The Publisher of the *Journal* remains neutral with regard to jurisdictional claims in published maps and institutional affiliations.

Edited by Zhang Q, Lei Y, Pan Y