

Case Report

Asian Pacific Journal of Tropical Medicine

apjtm.org

doi: 10.4103/apjtm.apjtm_305_25

Cutaneous actinomycoses leading to brain invasion: A case report

Naman Lodha[1], Angirekula Shekhar[1], Naresh Kumar Midha[2]✉, Ananya Panda[3], Kanishka Chaurasia[4], Anupama Bains[5], Deepak Kumar[2]

[1]*Department of General Medicine, AIIMS Jodhpur (Jodhpur City), India*

[2]*Department of General Medicine, Division of Infectious Disease, AIIMS Jodhpur (Jodhpur City), India*

[3]*Department of Radiology, University of Lowa, (Lowa City), USA*

[4]*Department of Pathology and Lab Medicine, AIIMS Jodhpur (Jodhpur City), India*

[5]*Department of Dermatology, Venerology and Leprosy, AIIMS Jodhpur (Jodhpur City), India*

ABSTRACT

Rationale: Central nervous system (CNS) actinomycosis is rare, spreading hematogenously from distant infections. Cutaneous actinomycosis with skull/meninges spread is especially unusual.

Patient concerns: A 57-year-old man presented with complaints of discharge from the back of his scalp for six months, an ataxic gait, and bilateral upper and lower limb weakness and numbness over the past 4-5 months.

Diagnosis: CNS actinomycosis.

Interventions: Intravenous injection of ceftriaxone followed by oral amoxicillin-clavulanic acid therapy.

Outcomes: The patient was able to walk without support, with complete resolution of sinus discharge.

Lessons: In patients presenting with discharging sinuses especially when accompanied by CNS symptoms, actinomycosis should be considered as a differential, along with tuberculosis, non-tubercular mycobacterial infection, and aspergillosis. Microbiological confirmation should be attempted wherever possible, for accurate diagnosis and treatment, as clinic-radiological picture alone may not differentiate these infections, as treatment of each is diametrically opposite and patients can be cured with timely and appropriate treatment.

KEYWORDS: Actinomycosis; CNS invasion; Cutaneous abscesses; Osteomyelitis; Pachymeningitis

1. Introduction

Actinomycoses are Gram-positive, anaerobic, fastidious organisms that constitute the normal flora of the oropharyngeal cavity, pharynx, genitourinary tract, and gastrointestinal tract. Multiple clinical manifestations of actinomycoses affecting various anatomical sites, such as the face and neck, respiratory tract, gastrointestinal tract, central nervous system (CNS), skin, and soft tissues, have been reported. Risk factors include dental procedures, gastrointestinal and otolaryngologic surgeries, human immunodeficiency virus infection, use of immunosuppressive drugs, intrauterine devices, and cyanotic heart disease. CNS actinomycosis is a rare entity, with a prevalence of 2%-3%, and usually results from hematogenous spread from a distant primary site such as the oral cavity, lungs, abdomen, or pelvis. It can also occur through direct extension from the face, jaw, ears, paranasal sinuses, or *via* cutaneous extension, as in our case. We report a case of actinomycosis presenting with multiple cutaneous abscesses in the scalp and posterior neck, associated with calvarial and skull base osteomyelitis, and extension into the CNS

✉To whom correspondence may be addressed. E-mail: midha.naresh@gmail.com

This is an open access journal, and articles are distributed under the terms of the Creative Commons Attribution-Non Commercial-ShareAlike 4.0 License, which allows others to remix, tweak, and build upon the work non-commercially, as long as appropriate credit is given and the new creations are licensed under the identical terms.

For reprints contact: reprints@medknow.com

©2025 *Asian Pacific Journal of Tropical Medicine* Produced by Wolters Kluwer-Medknow.

How to cite this article: Lodha N, Shekhar A, Midha NK, Panda A, Chaurasia K, Bains A, et al. Cutaneous actinomycoses leading to brain invasion: A case report. Asian Pac J Trop Med 2025; 18(9): 421-424.

Article history: Received 3 June 2025 Revision 15 September 2025
Accepted 21 September 2025 Available online 29 September 2025

causing meningeal involvement and venous sinus invasion. This case highlights cutaneous actinomycosis of the scalp leading to CNS invasion, confirmed by histopathological evidence.

2. Case report

A 57-year-old man presented with complaints of discharge from the back of his scalp for six months, an ataxic gait, and gradually progressive bilateral upper and lower limb weakness and numbness (proximal, followed by distal involvement) for four to five months. On presentation, the patient was conscious and well-oriented to time, place, and person. No meningeal signs were present. Cranial nerve examination was normal.

On motor examination, tone was raised in all limbs. Bilateral upper and lower limb deep tendon reflexes were exaggerated, and power was 4/5 in all four limbs (both proximal and distal). Sensory examination suggested decreased fine and crude touch (distal> proximal) with normal proprioception and vibration sense. The Romberg test showed swaying of the patient with eyes open.

Routine blood tests showed anemia and deranged liver function tests. Viral markers showed seropositivity for HBsAg. Anemia profile showed a transferrin saturation ratio of (25.3%, normal range: 20%-50%) and elevated ferritin levels, suggestive of anemia of chronic disease. To evaluate for hepatitis B, a FibroScan was done, which was reported as normal. HBV viral load was 1 176 IU/mL (<2 000), and HBeAg was negative. Liver function tests showed elevated ALT (90.2 IU/L) and AST levels (68.2 IU/L). ALP was also elevated (349 IU/L). A CD4 count was also sent, which was within the normal range (Supplementary Table 1).

Contrast-enhanced CT head and contrast-enhanced MRI was performed (Figure 1). Radiology demonstrated multiple left scalp and posterior neck cutaneous abscesses with discharging sinuses, left calvarial and skull base osteomyelitis, and diffuse pachymeningeal thickening along the left parieto-occipital region and tentorium cerebelli. There was invasion of the left venous sinuses with left cerebellar edema. The dural thickening also extended to the upper cervical spine with spinal canal narrowing and cord compression, accounting for the patient's quadriparesis and upper motor neuron signs.

A dermatology referral was made for the discharging sinuses. On cutaneous examination, there was irregular thickening of the

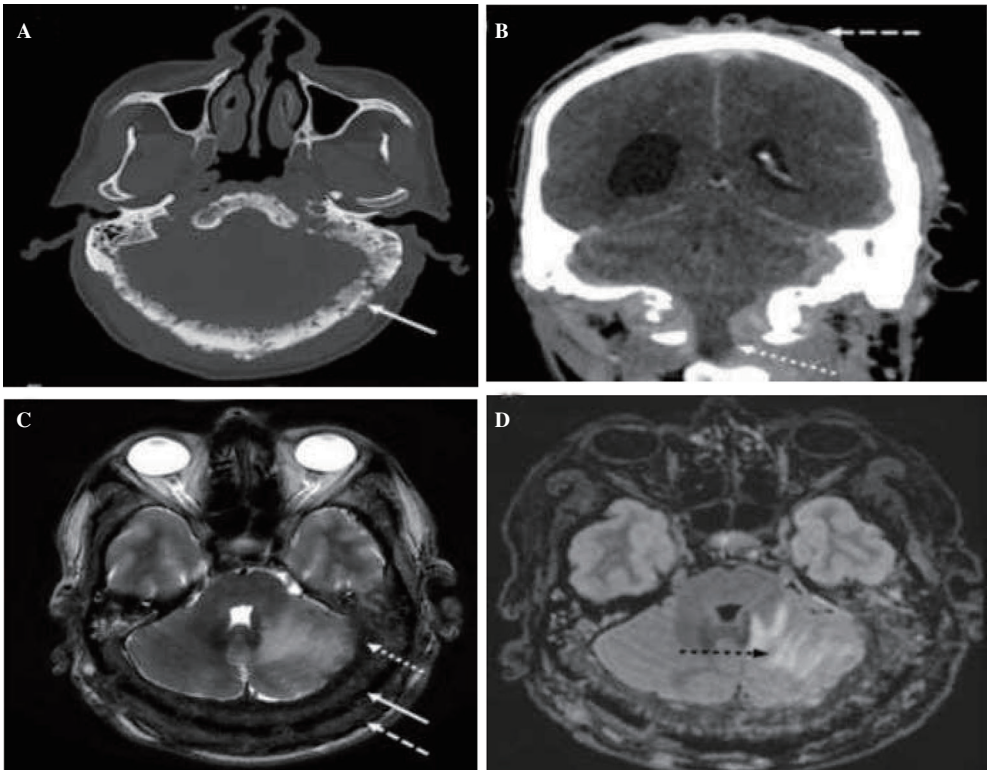

Figure 1. Contrast-enhanced CT and contrast-enhanced MRI images of the head of a 57-year-old man diagnosed with cutaneous actinomycoses. A: Axial CT showing calvarial hyperostosis, permeative changes and sinus tracts (solid white arrows) suggestive of chronic osteomyelitis. B: Coronal CT showing scalp thickening (dashed white arrow) and dural thickening (dotted white arrow) compressing cervical cord and adjacents of tissues of the neck. C: Axial T2MRI showing hypointense scalp thickening (dashed white arrow), bony sclerosis (solid white arrow), dural thickening (dotted white arrow). D: Axial T2 MRI showing cerebellar edema with brainstem mass effect (dotted black arrow).

skin over the scalp (Supplementary Figure 1). There were multiple convoluted folds and deep furrows along with mildly erythematous skin nodules with discharging sinuses. A punch biopsy from the nodule revealed thinned-out epidermis with loss of rete ridges with basket-weave orthokeratosis. The deep dermis showed hypertrophy and hyperplasia of the adnexal structure without an associated increase in collagen fibers, consistent with cutis verticis gyrata. Also noted was the presence of hyperplastic stratified squamous epithelium exhibiting parakeratosis, follicular plugging, and an ulcer bed formed by dense granulation tissue comprising an acute on chronic inflammatory infiltrate with cystically dilated blood vessels. Multiple foreign body giant cells and occasional Langhans giant cells were noted. Focal neutrophilic collections were also seen with clumps of basophilic filamentous bacteria surrounded by dense mixed inflammatory infiltrate. A few bacterial clumps were surrounded by eosinophilic granular material (Splendore-Hoeppli phenomenon). Gram stain showed Gram-positive bacilli consistent with Actinomycosis, while staining with Periodic Acid Schiff and Ziehl-Neelsen stain were negative (Supplementary Figure 2). Tissue aerobic, anaerobic, fungal, and mycobacterial cultures did not show any growth. Lumbar puncture and cerebrospinal fluid (CSF) analysis showed no WBCs and normal proteins, and subsequent CSF cultures showed no growth.

The patient was started on injectable ceftriaxone 2 g intravenously every 12 hours along with limb physiotherapy. The patient showed gradual improvement during the course of his hospital stay and was discharged on day 15 with a peripherally inserted central catheter for continued treatment with intravenous ceftriaxone. At one-month follow-up, the patient was able to walk without any support, with improved ataxia and power and improved weight-bearing. There was no active sinus discharge. The patient was shifted to oral amoxicillin-clavulanate 625 mg three times a day and was kept on follow-up.

3. Discussion

Human actinomycosis is an endogenous infection, usually colonizing the oral cavity, genitourinary tract, and gastrointestinal tract. These are commensals with low pathogenicity. They usually result from the disruption of the mucosal barrier or a simultaneous bacterial infection. It is a chronic granulomatous disease, with Actinomyces israelii being the most commonly implicated causative agent; however, other species are also implicated[1,2].

CNS actinomycosis is rare, with 2%-3% incidence rates. Most commonly, it occurs *via* hematogenous spread from distant primary sites such as the lungs, abdomen, and pelvis[3]. Contiguous extensions can occur through connective tissue planes or foramina in the skull. Bony spread as osteomyelitis has also been described[4,5].

CNS involvement can be classified as meningeal and intraparenchymal. Meningeal involvement includes pachymeningitis (most common), epidural abscess, and subdural empyema. Intraparenchymal involvement manifests as actinomycetoma (which appears as a ring-enhancing lesion and is indistinguishable from other causes of brain abscess) and as a brain abscess. Brain abscesses account for 75% of all lesions[3]. There is a predilection for the frontal and temporal lobes. Vascular involvement associated with meningitis is less frequently seen and includes intracranial mycotic aneurysm, subarachnoid hemorrhage[6], and moyamoya syndrome[7]. Bone involvement in the form of hyperostosis and osteomyelitis can present as part of the disease spectrum. There are case reports of sinusitis with secondary osteomyelitis or post-surgical spread of actinomycosis to skull bones[4,5].

Actinomycosis of the CNS can present with focal neurological signs (65.3%), headache (50.1%), fever (43.2%), altered sensorium (25.4%), meningeal signs (21.2%) and seizures (16.1%)[8]. Leukocytosis can be detected in routine investigations, and inflammatory markers can be normal or mildly increased. CSF evaluation can reveal lymphocytic pleocytosis, elevated protein levels, and low to normal glucose concentration[3]. Our case presented with discharge from the back of the scalp for six months and bilateral upper and lower limb weakness and numbness over duration of four to five months. There was no history of fever. Routine blood tests did not show leukocytosis. CSF evaluation was normal with no pleocytosis present.

The diagnosis of actinomycosis is mostly based on histopathological examination, as these infections are generally polymicrobial, and synergistic bacteria identified on cultures can mask the growth of Actinomyces. Thus, a tentative diagnosis mostly depends on the histopathological presence of Gram-positive filamentous organisms and sulfur granules in the tissue.

Clinical differential considerations in our case included tuberculosis, which is ubiquitous in our patient setting and has similar varied presentations in the form of meningitis, vascular infarcts, spondylodiscitis, and cold abscesses. Tuberculosis was ruled out based on a normal chest X-ray as well as negative results from sinus discharge and CSF samples, a normal cartridge-based nucleic acid amplification test, and mycobacterial culture. Also, MRI brain findings were not suggestive of tuberculosis. Other radiological considerations were atypical fungal infection and nocardiosis. *Nocardia* may also spread to the central nervous system through a cutaneous route or from a pulmonary site, disseminating particularly in immunocompromised individuals, and can present as an abscess or meningitis. *Nocardia* species are difficult to distinguish morphologically[9] from *Actinomyces*; however, they are differentiated based on their acid-fastness and aerobic growth. CSF evaluation did not show pleocytosis or elevated proteins, and aerobic culture and partial acid-fast staining were negative in our patient. Moreover, CSF galactomannan reports were negative, thus ruling

out CNS Aspergillosis, which can present with a similar radiological presentation.

Treatment usually includes beta-lactam antibiotics, especially penicillin G, amoxicillin-clavulanate, or ceftriaxone, which are required for a long duration, approximately 6-12 months. Considering high CNS penetration and good efficacy against actinomycosis, the patient was started on intravenous ceftriaxone 2 g every 12 hours. Surgery is reserved for brain abscesses, refractory disease, and invasion of critical sites (such as epidural infections[10].

The main highlights of our case report are as follows: CNS spread occurred in a contiguous manner *via* scalp and posterior neck abscesses with discharging sinuses, calvarial and skull base osteomyelitis without a history of previous surgery or sinusitis, diffuse pachymeningeal thickening in the left parieto-occipital region and tentorium cerebelli rather than the more common fronto-temporal region involvement, extension of dural thickening to the cervical spine with spinal canal narrowing and cord compression leading to quadriparesis and upper motor neuron signs, and histopathological evidence of gram-positive filamentous bacteria.

The cornerstone in management and also for diagnostic purposes (particularly in patients who lack microbiological evidence) is the clinical, radiological, and laboratory response to treatment, with early diagnosis leading to good treatment outcomes.

Conflict of interest statement

The authors declare that they have no conflict of interest.

Ethics approval and consent to participate

The need for ethical approval was waived by Institutional Ethics Committee of AIIMS Jodhpur. Informed consent was obtained from the patient for the publication of this case report and any accompanying images.

Funding

The authors received no extramural funding for the study.

Authors' contributions

NL: Conceptualization, data curation, writing original draft preparation; AS: Data collection, clinical management, writing-review&editing; NKM: Supervision, critical revision of the manuscript, clinical management; AP: Radiology interpretation, preparation of radiology figures, writing-review & editing; KC: Pathology analysis, preparation of pathology figures, writing-review & editing; AB: Dermatology evaluation, contribution of dermatological findings and images, writing-review&editing; DK: Clinical input, data verification, writing-review&editing.

References

[1] Mishra A, Prabhuraj AR, Bhat D, Nandeesh BN, Mhatre R. Intracranial actinomycosis manifesting as a parenchymal mass lesion: A case report and review of literature. *World Neurosurg* 2019; **122**: 190-194.

[2] Ravindra N, Sadashiva N, Mahadevan A, Bhat DI, Saini J. Central nervous system actinomycosis-a clinicoradiologic and histopathologic analysis. *World Neurosurg* 2018; **116**: e362-e370.

[3] Smego RA. Actinomycosis of the central nervous system. *Clin Infect Dis* 1987; **9**: 855-865.

[4] Akhaddar A, Elmostarchid B, Boulahroud O, Elouennass M, Boucetta M. Actinomycotic brain abscess with osteomyelitis arising from frontal sinusitis. *Intern Med Tokyo Jpn* 2009; **48**: 619-620.

[5] Lewin W, Morgan AD. Actinomycosis of the brain. *J Neurol Neurosurg Psychiatry* 1947; **10**: 163-170.

[6] Koda Y, Seto Y, Takeichi S, Kimura H. Fatal subarachnoid hemorrhage complicating actinomycotic meningitis. *Forensic Sci Int* 2003; **134**: 169-171.

[7] Zhang M, Meng S, Al Mahmoud M, Li Y, Dai Y, Li C, et al. A rare case of central nervous system actinomycosis presenting with moyamoya syndrome. *CNS Neurosci Ther* 2022; **28**: 1139-1142.

[8] Meena DS, Kumar D, Sharma M, Malik M, Ravindra A, Santhanam S, et al. The epidemiology, clinical presentation and treatment outcomes in CNS actinomycosis: A systematic review of reported cases. *Orphanet J Rare Dis* 2023; **18**(1): 133.

[9] Anagnostou T, Arvanitis M, Kourkoumpetis TK, Desalermos A, Carneiro HA, Mylonakis E. Nocardiosis of the central nervous system. *Medicine (Baltimore)* 2014; **93**: 19-32.

[10]Perez A, Syngal G, Fathima S, Sandkovsky U. Actinomyces causing a brain abscess. *Bayl Univ Med Cent Proc* 2021; **34**: 698-700.

Publisher's note

The Publisher of the *Journal* remains neutral with regard to jurisdictional claims in published maps and institutional affiliations.

Edited by Pan Y, Lei Y, Zhang Q

Supplementary Table 1. ***Routine baseline laboratory parameters at admission.***

Parameter	**Value**	**Reference value**
Hemoglobin (gm/dL)	13.3	14-16
TLC ($x10^3$)	6.02	4-11
Platelet count ($x10^3$)	175	150-450
Blood urea (mg/dL)	32	(5-20)
Creatinine (mg/dL)	1.04	(0.5-1.1)
AST (IU/L)	50	(<35)
ALT (IU/L)	84	(<35)
ALP	217	(47-119)
Total bilirubin	0.6	(0.3-1.2)
Direct bilirubin	0.2	(<0.2)
PT/INR	17.6/1.04	(16/1.5)
Total protein (mg/dL)	6.8	(6.6-8.8)
Albumin (mg/dL)	3.1	(3.5-5.2)

Sodium (Meq/L)	134	(136-146)
potassium (Meq/L)	3.72	(3.5-5.1)
CRP (mg/L)	75.7	(<5)
ESR (mm in one hour)	89	(<15)
HCV antibody rapid	Non reactive	Non reactive
HBsAg by ELISA test	**Positive**	Negative
HIV 1 & 2 rapid test	Non reactive	Non reactive
HBeAg by ELISA test	Negative	Negative
HBV viral load (IU/mL)	1176	-

TLC: Total leucocyte count; AST: Aspartate aminotransferase; ALT: Alanine aminotransferase; ALP: Alkaline phosphatase; PT: Prothrombin time; INR: International normalized ratio; CRP: C-reactive protein; ESR: Erythrocyte sedimentation rate; HCV: Hepatitis B virus; HBsAg: Hepatitis B surface antigen; HIV: Human immunodeficiency virus; HBeAg: Hepatitis B 'e' antigen; ELISA: Enzyme-linked immunosorbent assay; HBV: Hepatitis B virus.



Supplementary Figure 1. Scalp with multiple convoluted folds and deep furrows (Cutis verticis gyrata) with few erythematous nodules.

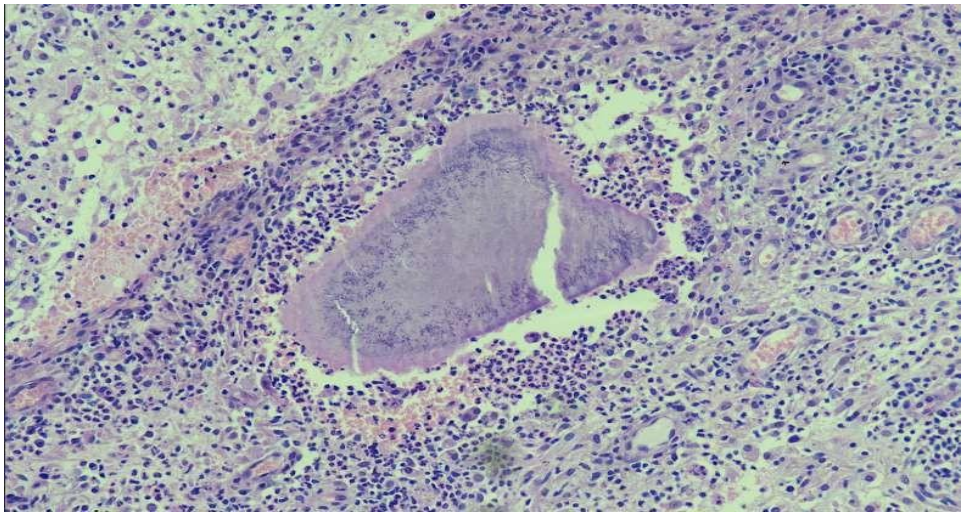

Supplementary Figure 2. Hematoxylin and eosin stain showing large basophilic filamentous bacteria and splendore Hoeppli phenomenon surrounded by neutrophils.