四川大学学报（医学版） 2026，57（2）：473－481
J Sichuan Univ（Med Sci） doi: 10.12182/20260360109

在线全文

The Prevalence and Clinical Significance of the Centromere Protein-F-Like Immunofluorescence Staining Pattern in a Large ANA-positive Cohort

SU Zhenzhen[1, 2, 3], *ZHANG Feng*[1, 2, 3], *ZHANG Lijing*[1, 2, 3], *HAYISAER YEERKEN*[4], *YANG Bin*[1, 2, 3], *HU Jing*[1, 2, 3], *WANG Li*[1, 2, 3], *GAO Xuedan*[1, 2, 3], *ZHANG Junlong*[1, 2, 3], *HUANG Zhuochun*[1, 2, 3△]. 1. *Department of Laboratory Medicine, West China Hospital, Sichuan University, Chengdu 610041, China*; 2. *Clinical Laboratory Medicine Research Center, West China Hospital, Sichuan University, Chengdu 610041, China*; 3. *Sichuan Clinical Research Center for Laboratory Medicine, Chengdu 610041, China*; 4. *West China School of Medicine, Sichuan University, Chengdu 610041, China*

△ Corresponding author, E-mail: huangzcscu@163.com

This study was supported by the National Key R&D Program of China (No. 2022YFC2406600/No. 2022YFC2406604).

[Abstract] **Objective** To investigate the prevalence and clinical significance of the centromere protein-F-like (CENP-F-like) immunofluorescence staining pattern in a large patient cohort and through literature review. **Methods** We retrospectively analyzed antinuclear antibody (ANA) immunofluorescence assay results from 191 274 patients at West China Hospital of Sichuan University between March 2018 and November 2020. Specific immunological markers were tested in sera with CENP-F-like patterns. Additionally, a narrative review of seven relevant studies was performed for comparison. **Results** In Southwest China, ANA positivity was found in 32.09% of patients, with the CENP-F-like pattern detected in 0.015% of all cases and 0.05% of ANA-positive individuals. The CENP-F-like pattern appeared predominantly at titers ≥ 1∶320, most often in isolation (68.97%), but also mixed with cytoplasmic speckled patterns. Patients with cancers accounted for the highest proportion (31.03%), including solid tumors and hematologic malignancies. Metastasis was observed in patients with solid tumors, while graft-versus-host disease (GVHD) occurred in those with hematologic malignancies post-transplantation. Autoimmune diseases (AIDs) were diagnosed in 20.69% of cases, all showing disease-specific autoantibodies. These findings were broadly consistent with previous reports and suggest a possible association between the CENP-F-like pattern and malignancies. **Conclusion** The CENP-F-like pattern is rare in ANA tests but may be associated with clinically important conditions, particularly cancers and AIDs. The occurrence of metastasis and GVHD in patients with this pattern highlights its potential clinical relevance, and concurrent autoantibodies may assist in diagnosing AIDs.

[Key words] Antibodies, antinuclear Fluorescent antibody technique, indirect Clinical relevance Neoplasms Autoimmune diseases

抗核抗体阳性大样本人群中着丝点F样型免疫荧光模型的检出率及临床意义*

苏真珍[1, 2, 3]， 张 凤[1, 2, 3]， 张丽静[1, 2, 3]， 哈依萨尔.叶尔肯[4]， 杨 滨[1, 2, 3]， 胡 静[1, 2, 3]，
王 丽[1, 2, 3]， 高雪丹[1, 2, 3]， 张君龙[1, 2, 3]， 黄卓春[1, 2, 3△]

1. 四川大学华西医院 实验医学科（成都 610041）；2. 四川大学华西医院 临床检验医学研究中心（成都 610041）；
3. 四川省医学检验临床医学研究中心（成都 610041）；4. 四川大学华西临床医学院（成都 610041）

【摘要】 **目的** 探讨着丝点F样型（centromere protein-F-like, CENP-F-like）免疫荧光模型在大样本人群中的检出率及临床意义，并结合文献进行对照分析。**方法** 回顾性分析2018年3月–2020年11月在四川大学华西医院就诊的191 274例患者的抗核抗体（antinuclear antibody, ANA）免疫荧光检测结果，对检出着丝点F样型的血清进一步进行特异性免疫学指标检测。同时，对7篇相关研究开展叙述性文献回顾以作比较。**结果** 在西南地区，ANA的阳性率为32.09%，着丝点F样型在人群中的检出率为0.015%，在ANA阳性个体中为0.05%。该荧光模型滴度多≥1∶320，以单一模型为主（68.97%），也可与胞

* 国家重点研发计划项目（No. 2022YFC2406600、No. 2022YFC2406604）资助

△ 通信作者，E-mail: huangzcscu@163.com

出版日期：2026-03-20

质颗粒型共存。疾病分布中,肿瘤患者比例最高(31.03%),涵盖实体瘤和血液系统恶性肿瘤;其中实体瘤患者可见转移,血液系统恶性肿瘤患者移植后均出现移植物抗宿主病(graft-versus-host disease, GVHD)。此外,20.69%的病例被诊断为自身免疫病(autoimmune diseases, AIDs),且均伴有特异性自身抗体。上述结果与既往文献报道总体一致,提示着丝点F样型与恶性肿瘤之间可能存在关联。**结论** 着丝点F样型虽在ANA检测中罕见,但可能与多种重要临床情况相关,尤其是肿瘤和AIDs。该模型在转移及GVHD患者中的出现提示其潜在临床价值,而合并存在特异性自身抗体可为AIDs的诊断提供支持。

【关键词】 抗体,抗核 荧光抗体技术,间接 临床相关性 肿瘤 自身免疫病

Antinuclear antibodies (ANA) are a series of autoantibodies against cellular components, including nuclear, cytoplasmic, and mitotic structures. ANA can be found in most autoimmune diseases (AIDs)[1], such as systemic lupus erythematosus (SLE), Sjogren's syndrome (SjS), systemic sclerosis, idiopathic inflammatory myopathies, and autoimmune liver diseases. They play critical roles in diagnosing, classifying, and monitoring disease activity. Notably, ANA may also occur outside AIDs, including in chronic infections, medication-related adverse events, and even apparently healthy individuals[2-4].

The indirect immunofluorescence assay (IFA) based on the human epithelial type 2 (HEp-2) cell substrate is considered the gold standard for ANA determination due to its exceptional sensitivity[5-7]. HEp-2 IFA provides information about disease states and types through fluorescence intensity (represented by titer) and patterns. Higher ANA titers often indicate higher ANA levels, which correlate better with ANA-related rheumatic diseases[8].

According to the International Consensus on ANA Patterns (ICAP), ANA patterns are classified by the anti-cell (AC) code, including 31 patterns (from AC-1 to AC-31) reported to the clinic[9]. The centromere protein-F-like (CENP-F-like) pattern, referred to as the AC-14 pattern, is a nuclear pleomorphic pattern characterized by variability in fluorescence intensity: strongest in G_2 phase and weakest/negative in G_1. Centromeres are positive only in prometaphase and metaphase, revealing multiple aligned small and faint dots. Prometaphase cells frequently show weak staining of the nuclear envelope. During anaphase and telophase, some sera demonstrate intense staining in the ring located at the midzone (i.e., mid-body, stem body) where the division of the daughter cells is taking place (shown in Fig 1)[10-11].

Unlike common ANA patterns, such as nuclear homogenous pattern (AC-1) and nuclear speckled pattern (AC-4, 5) which have been extensively explored and revealed their clinical relevance[12-14], the prevalence and clinical significance of the CENP-F-like pattern remain insufficiently studied. Therefore, in this study, we analyzed 191 274 ANA IFA cases from the Southwest China population to elucidate the prevalence and further explore the clinical significance of the CENP-F-like pattern. Additionally, a narrative review was conducted to identify 97 additional patients with anti-CENP-F antibodies/CENP-F-like patterns from seven studies, allowing us to compare our findings with existing data and provide a comprehensive understanding of this distinctive ANA pattern and its potential clinical implications.

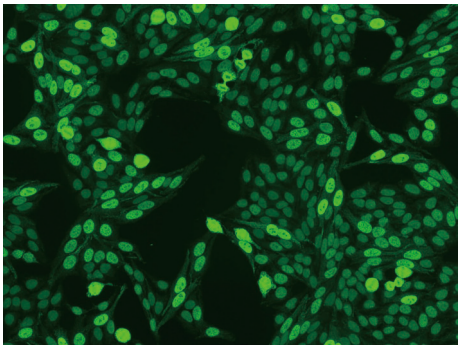

Fig 1 The CENP-F-like pattern (AC-14)

Observed under a fluorescence microscope, showing characteristic nuclear pleomorphic staining. Magnification × 200.

1 Materials and methods

1.1 Patients

From March 1st, 2018 to November 15th, 2020, 191 274 patients (excluding duplicates) from West China Hospital of Sichuan University were sequentially included in this study. All patients underwent HEp-2 IFA tests, and the data were retrospectively analyzed. Clinical and other laboratory information were collected from the hospital and laboratory information systems. The study was approved by the West China Hospital Ethics Committee (approval number: 2022-1952) and conducted following relevant guidelines and regulations. As this was a retrospective analysis of routinely collected data, all patient information was de-identified, and

the requirement for informed consent was waived.

1.2 ANA detection

ANA detection was performed by automated processing of immunofluorescence tests following the manufacturer's protocols for ANA IFA using HEp-2 cell substrate and primate liver tissue (Sprinter XL, Euroimmun, Lübeck, Germany). A $\sqrt{10}$ dilution system was employed, starting at 1∶100. ANA IFA slides were read by two experienced technologists under a fluorescence microscope (EUROStar Ⅲ Plus, Euroimmun, Lübeck, Germany). In case of discrepant interpretation, the slides and archived digital images were jointly reviewed to reach a consensus. If consensus could not be achieved, a third senior reviewer adjudicated; when staining quality was suboptimal or uncertainty persisted, the assay was repeated. An ANA titer of ⩾1∶100 was considered a positive result in this study. Samples displaying the CENP-F-like pattern were identified according to pattern-related characteristics. For samples displaying mixed patterns, the reported ANA titer (endpoint titer) was defined as the highest dilution at which any specific pattern remained clearly detectable, and all patterns discernible at any dilution throughout the titration series were recorded.

1.3 Specific immunological marker detection

To explore the potential association with other immunological markers, especially autoantibodies, all sera displaying ANA positivity with the characteristic CENP-F-like pattern were screened for extractable nuclear antigen (ENA) autoantibodies, including anti-nRNP/Sm, anti-Sm, anti-SSA, anti-Ro52, anti-SSB, anti-Scl-70, anti-Jo-1, and anti-ribosomal P protein (Rib-P), using a line immunoblot assay (Euroimmun, Lübeck, Germany). Additionally, partial sera positive for the CENP-F-like pattern were tested for other specific autoantibodies, such as anti-double-stranded DNA (anti-dsDNA) and antikeratin antibodies (AKA) detected by IFA (Euroimmun, Lübeck, Germany), anti-cyclic citrullinated peptide antibodies (anti-CCP) detected by electrochemiluminescence immunoassays (Cobas e601, Roche Diagnostics, Basel, Switzerland), rheumatoid factor (RF) detected by rate scattering turbidimetry (IMMAGE 800, Beckman-Coulter, Brea, California, USA), and autoimmune liver disease-related autoantibodies were detected by line immunoassay (Tenfly Phoenix-A, YHLO, Shenzhen, China). Furthermore, human leukocyte antigen B27 (HLA-B27) was detected using the BD™ HLA-B27 Kit with the BD FACSCanto™ Ⅱ flow cytometer (BD Biosciences, San Jose, California, USA).

1.4 Literature review

A narrative review was conducted by searching PubMed from 1993 to 2023 using the following keywords: "CENP-F", "centromere protein F", "p330d", "NSp-Ⅱ", "antinuclear antibody", and "autoantibody". Relevant articles focusing on the prevalence and clinical significance of the CENP-F-like pattern were selected for review.

1.5 Statistical analysis

Data were presented as mean ± standard deviation or median with the interquartile range according to the data distribution. Continuous variables were compared using the Student's *t*-test or Mann-Whitney *U* test based on the normality of the data distribution. Categorical variables were analyzed using the Chi-square test or Fisher's exact test. All data were analyzed using the Statistical Package for Social Sciences (SPSS) version 24.0 (IBM Corp., Armonk, NY, USA). A *P*-value of < 0.05 was considered statistically significant.

2 Results

2.1 Prevalence and demographics of patients with the CENP-F-like pattern

Among the 191 274 patients, 61 371 (32.09%) were found to have positive ANA-IFA results. Of these, 29 patients exhibited the CENP-F-like pattern (0.05% of ANA-IFA positive patients; 0.015% of the total patients tested). The mean age of ANA-IFA positive patients was (51 ± 16) years, while for those with the CENP-F-like pattern, it was (55 ± 14) years, with no significant difference ($P > 0.05$). Females constituted 73.90% of ANA-IFA positive patients and 55.17% (16/29) of those with the CENP-F-like pattern, showing a significant difference in gender ratio ($P = 0.023$).

2.2 Features of the CENP-F-like pattern

In this study, the immunofluorescent characteristics of the CENP-F-like pattern are shown in Fig 1. The CENP-F-like pattern could display low, medium, and high fluorescence titers, predominantly at or above 1∶320 in 19 cases (65.52%). Isolated CENP-F-like patterns were most common, observed in 68.97% (20/29) of cases. Among

patients exhibiting mixed patterns, the CENP-F-like pattern frequently co-occurred with the cytoplasmic speckled pattern, particularly in 55.56% (5/9) of such cases. Notably, all cases with a titer of 1 ∶ 100 presented isolated CENP-F-like patterns, while those with mixed patterns had titers of ⩾1 ∶ 320, with the CENP-F-like pattern consistently remaining dominant at the endpoint titer (shown in Table 1).

All patients exhibiting the CENP-F-like pattern were tested for ENA antibodies, with 12 cases (41.38%) returning positive results. Anti-Ro52 and anti-SSA were the most commonly detected ENA antibodies, present in 7 (24.14%) and 5 (17.24%) cases, respectively. In contrast, anti-RNP/Sm, anti-Sm, anti-SSB, anti-Jo-1, and anti-Rib-P were each found in only 1 case (3.45%), and anti-Scl-70 was not detected in any patient.

Table 1 Distribution of diseases in patients with the CENP-F-like pattern, stratified by fluorescence titer

Disease distribution	Total (n = 29)		Titer = 1 ∶ 100 (n = 10)		Titer ⩾ 1 ∶ 320 (n = 19)	
	Isolated	Mixed	Isolated	Mixed	Isolated	Mixed
Cancers	6	3	1	0	5	3
Solid tumors	4	1	1	0	3	1
Hematologic malignancies	2	2	0	0	2	2
Liver disease	4	0	2	0	2	0
Cerebral infarction	3	0	1	0	2	0
AIDs	4	2	2	0	2	2
Others	5	4	4	0	1	4
Total	20*	9	10	0	10*	9

AIDs: autoimmune diseases. * Two cases are counted in multiple categories (details can be found in Table 2): case 2 has both a solid tumor (esophageal carcinoma) and liver disease (alcoholic cirrhosis), and case 5 has both hematologic malignancy (lymphoid blast phase of chronic myeloid leukemia) and liver disease (chronic hepatitis B).

2.3 Distribution of diseases in patients with the CENP-F-like pattern

As illustrated in Tables 1-3, the CENP-F-like pattern was observed in a variety of diseases, including cancers, AIDs, cerebral infarction, and other conditions. Among these, cancers (31.03%) and AIDs (20.69%) were the two most frequent diagnoses, occurring in both isolated and mixed forms, with isolated CENP-F-like patterns being more common. Liver disease and cerebral infarction were only observed as isolated CENP-F-like patterns in our investigated group. Most individuals with liver disease and cerebral infarction had fluorescence titers less than or equal to 1 ∶ 320, with the exception of one patient who had both alcoholic cirrhosis and esophageal carcinoma, exhibiting a titer of 1 ∶ 1 000. In contrast, patients diagnosed with cancers and AIDs predominantly exhibited fluorescence titers ⩾ 1 ∶ 320.

Nine patients with the CENP-F-like pattern were diagnosed with cancers, including solid tumors (esophageal carcinoma, breast carcinoma, and lung cancer) and hematologic malignancies (chronic/acute myeloid leukemia and myelodysplastic syndrome). Notably, two patients with solid malignant tumors (cases 3 and 4 in Table 2) had cancer metastasis, and case 2 (Table 2) had a pancreas mass when they tested positive for the CENP-F-like pattern. Case 1 (Table 2) was discovered to have cancer metastasis a few months later. Enlargement of mediastinal and left hilar lymph nodes was observed in case 23 (Table 3), in whom ANA-IFA demonstrated the CENP-F-like pattern. These findings suggest a potential association between cancer metastasis and ANA-IFA showing the CENP-F-like pattern. Four patients with the CENP-F-like pattern were diagnosed with hematologic malignancies (cases 5 and 6 in Table 2, cases 22 and 27 in Table 3). All presented with graft-versus-host disease (GVHD) after bone marrow or stem cell transplantation.

Among the patients with AIDs, all six cases were women, with a median age of 42 years (range: 27-74 years). These patients had specific autoantibodies, such as anti-dsDNA and anti-CCP antibodies. The median age for liver disease patients was 48 years, and all had concurrent infections. Among the four liver disease cases, two also had

Table 2　Clinical characteristics of patients with isolated CENP-F-like patterns

Case	Sex	Age/yr.	Diagnosis	Complications	Titer	Specific markers
Cancers						
1	M	55	Lower esophageal squamous cell carcinoma		1∶1 000	Anti-Ro52
2	M	66	Esophageal carcinoma, alcoholic cirrhosis	Lung infection, moderate anemia	1∶1 000	Anti-Ro52
3	F	64	Invasive ductal carcinoma of the right breast with multiple metastases		1∶100	
4	F	50	Non-small cell lung cancer of the right lung with multiple metastases		1∶320	
5	M	32	Lymphoid blast phase of CML, stem cell transplantation, GVHD, CHB	Lung infection	1∶320	
6	M	46	MDS, stem cell transplantation, GVHD	Skin lichenification	1∶1 000	
Liver diseases						
2	M	66	Esophageal carcinoma, alcoholic cirrhosis	Lung infection, moderate anemia	1∶1 000	Anti-Ro52
5	M	32	Lymphoid blast phase of CML, stem cell transplantation, GVHD, CHB	Lung infection	1∶320	
7	F	36	Alcoholic cirrhosis	Urinary tract infection	1∶100	
8	F	60	Cirrhosis	Lung infection, moderate anemia	1∶100	
Cerebral infarction						
9	M	64	Cerebral infarction, Parkinsonian syndrome	Atherosclerosis	1∶320	Anti-SSB
10	F	67	Cerebral infarction	Hypertension	1∶100	
11	M	65	Cerebral infarction		1∶320	
Autoimmune diseases						
12	F	48	SLE		1∶320	Anti-dsDNA Anti-SSA Anti-Ro52 Anti-Rib-P
13	F	36	SLE	Severe anemia	1∶1 000	Anti-dsDNA Anti-Ro52
14	F	74	RA	Recurrent painful swelling of joint	1∶100	Anti-CCP (275.30 U/mL) RF (1 750.00 IU/mL) AKA
15	F	27	UCTD	Recurrent urinary tract infection	1∶100	Anti-SSA
Others						
16	F	44	Chronic nephritis	Hypertension	1∶100	
17	F	80	MND	Hypertension, atherosclerosis	1∶100	
18	F	52	Arthralgia		1∶100	
19	F	55	Renal calculi		1∶320	
20	M	77	Granulocytosis		1∶100	

M: male; F: female; CML: chronic myeloid leukemia; GVHD: graft-versus-host disease; CHB: chronic hepatitis B; MDS: myelodysplastic syndrome; SLE: systemic lupus erythematosus; RA: rheumatoid arthritis; UCTD: undifferentiated connective tissue disease; MND: motor neuron disease; Anti-dsDNA: anti-double-stranded DNA antibody; Anti-CCP: anti-cyclic citrullinated peptide antibody; RF: rheumatoid factor; AKA: antikeratin antibody.

Table 3　Clinical characteristics of patients with mixed CENP-F-like patterns

Other fluorescence patterns combined with CENP-F-like pattern	Case	Sex	Age/yr.	Titers of CENP-F-like pattern	Diagnosis or symptoms	Specific markers
Cytoplasmic speckled pattern (n = 5)	21	M	49	1∶3 200	Erythema nodosum?	
	22	M	54	1∶1 000	AML transformed from MDS, stem cell transplantation, CHB, and GVHD	
	23	M	67	1∶3 200	Small cell lung cancer of the left lung	
	24	F	52	1∶1 000	Lumbago	Anti-Ro52, HLA-B27
	25	M	65	1∶3 200	Hypoproteinemia, anemia	
Nucleolar pattern (n = 2)	26	F	37	1∶1 000	Recurrent cough, SjS?	Anti-SSA, anti-Ro52
	27	M	45	1∶1 000	CML, bone marrow transplantation, GVHD	Anti-Jo-1
Cytoplasmic reticular/AMA pattern (n = 1)	28	F	46	1∶1 000	PBC	AMA-M2
Discrete nuclear dots pattern (n = 1)	29	M	70	1∶320	Lung infection, interstitial pneumonia	

AMA: anti-mitochondrial antibody; M: male; F: female; AML: acute myeloid leukemia; MDS: myelodysplastic syndrome; CHB: chronic hepatitis B; GVHD: graft-versus-host disease; SjS: Sjogren's syndrome; CML: chronic myeloid leukemia; PBC: primary biliary cholangitis; HLA-B27: human leukocyte antigen B27.

cancer. Patients with cerebral infarction had a median age of 65 years, and two-thirds had cardiovascular complications.

2.4 Literature review

A narrative review allowed us to identify 97 additional patients with anti-CENP-F antibodies/CENP-F-like patterns from 7 studies[10, 15-20]. Regarding the distribution of age and gender, no difference was observed between our cohort and patients reported in the literature (Table 4). Consistent with previous studies on the frequency of anti-CENP-F antibodies/CENP-F-like patterns among ANA-positive patients, which ranged from 0.013% to 0.29%[16, 18, 20], the 0.05% frequency in our cohort was within this range. Furthermore, most patients in previous studies had isolated CENP-F-like patterns (23 of 32 cases, 71.9%), while the concomitant fluorescence patterns identified in the other 9 patients were nuclear dense fine speckled pattern (n = 6), centromere pattern (n = 2) and cytoplasmic discrete dots/Gw body-like pattern (n = 1)[10, 16].

Observing the disease spectrum, we found that cancer was the most common diagnosis in both our CENP-F-like pattern cohort and previous reports. However, in the present research, hematologic malignancies accounted for a significantly higher proportion compared with previous studies, where solid tumors had a larger share (P = 0.008). We also observed cancer metastases among patients with the CENP-F-like pattern, a finding previously reported only briefly by WELNER *et al*[19]. In their study, cancer metastases occurred in a breast cancer patient and an ovarian cancer patient. Additionally, GVHD was also prevalent in our findings, as all patients with hematologic malignancies developed it. Corroborating this, the sole previous case of GVHD in CENP-F-like pattern positive patients further emphasized the need for exploring the correlation between GVHD and the pattern[18]. It is also worth noting that the proportion of liver disease and cerebrovascular disorders in our cohort is higher than in previous studies. In line with our findings, AIDs were reported in only 12 patients (12.37%) in prior research, predominantly encompassing

Table 4 Clinical features of patients with anti-CENP-F antibodies/CENP-F-like patterns: a comparison between our cohort and the literature

Characteristics	Present report (n = 29)	Previous reports (n = 97)
Age/yr., mean ± SD*	55 ± 14	60 ± 11 (37 cases[15, 17])
		56 ± 7 (4 cases[20])
Female*/case (%)	16/29 (55.17)	31/47 (65.96)
Prevalence among ANA-positive patients*/%	0.05	0.046 (range: 0.013-0.29)
Isolated CENP-F-like patterns*/case (%)	20/29 (68.97)	23/32 (71.88)
Disease relevance/case (%)		
Cancer	9 (31.03)	42** (43.30)
Hematologic malignancies	4 (13.79)	2 (2.06)
Solid tumors	5 (17.24)	37 (38.14)
Lung cancer	2 (6.90)	9 (9.28)
Breast cancer	1 (3.45)	13 (13.40)
Ovarian cancer	0	3 (3.09)
Others	2 (6.90)	12 (12.37)
GVHD	4 (13.79)	1 (1.03)
AIDs	6 (20.69)	12 (12.37)
Liver disease	4 (13.79)	7 (7.22)
Cerebrovascular disorder	3 (10.34)	1 (1.03)

SD: standard deviation; ANA: antinuclear antibody; GVHD: graft-versus-host disease; AIDs: autoimmune diseases. * Due to the absence of clinical data for patients with anti-CENP-F antibodies/CENP-F-like patterns in certain studies, including age, gender, prevalence and percentage of isolated patterns, the denominator includes only the number of patients for whom this parameter was available when calculating percentages and ratios. For example, patients' gender information in ref [18-19] is unavailable, so the "Female/case (%)" in "Previous reports" is based solely on data from patients in ref [10, 15-17, 20], specifically, 31 of 47 cases with anti-CENP-F antibodies/CENP-F-like patterns were female. ** Out of 42 cases, three from ref [18] were not clearly identified as solid tumors or leukemia.

SLE, SjS and undifferentiated connective tissue disease (UCTD)[10, 15-16, 20].

3 Discussion

The CENP-F-like pattern (AC-14), part of the ANA-IFA pleomorphic patterns, is recommended for clinical reporting by ICAP-2021[7]. However, literature on its prevalence and disease association is sparse. In this study, we identified a low prevalence (0.015%) of the CENP-F-like pattern among the general population in Southwest China, based on a retrospective analysis of ANA-IFA results from 191 274 consecutive patients. Our finding aligns with a Danish study reporting a prevalence of 0.016% but contrasts with a Serbian study that reported a prevalence of approximately 0.096%[16, 19]. Population and regional differences may account for these varying prevalence rates.

Among ANA-positive patients, the prevalence of the CENP-F-like pattern was 0.05%. This is lower than the 0.29% reported by VERMEERSCH *et al.* in Belgium, who used HEp-2000 slides for ANA IFA tests, which might explain the differences, as their ANA positive rate was 13.6%. Despite these differences, our study, based on a large sample size and limited literature, indicated a low prevalence of the CENP-F-like pattern (< 1%), defining it as a rare pattern[18].

Our results demonstrated that both isolated and mixed CENP-F-like patterns could be observed in clinical practice. Isolated CENP-F-like patterns were more common than mixed patterns, and the disease spectrums appeared broadly similar between the two types. When analyzing the disease spectrum related to the CENP-F-like pattern, cancers constituted the largest diagnostic category, accounting for 31.03% (9/29). This aligns with our literature review, which reported the highest proportion of cancer patients among those with CENP-F-like patterns, reaching 43.30% (Table 4). We identified esophageal carcinoma, breast carcinoma, lung cancer, and hematologic malignancies as related malignancies. While previous studies noted breast cancer as the most common malignancy, comprising 13.40% of cases, our research found hematologic malignancies to be more frequent, especially with mixed CENP-F-like patterns, accounting for 13.79% of cases compared to only 2.06% in previous reports (Table 4).

As detailed in Tables 2 and Tables 3, cancer patients exhibited higher fluorescence titers than non-cancer patients, with more than half (5/9, 55.6%) showing medium to high titers, suggesting heightened pattern-associated autoantibody reactivity in these patients. CENP-F, an approximately 367 kDa nuclear protein, has been reported as a major/putative target antigen associated with the CENP-F-like pattern[21]. Increased CENP-F expression—demonstrated by immunohistochemistry and/or transcriptomic analyses—has been reported across multiple malignancies, including hepatocellular carcinoma, renal cancer, lung adenocarcinoma, triple-negative breast cancer, ovarian and cervical cancers, glioma, cutaneous melanoma, oral squamous cell carcinoma, and diffuse large B-cell lymphoma[21-27]. This tumor-associated overexpression may provide a biological rationale for the emergence of anti-CENP-F autoantibodies and the CENP-F-like pattern observed on ANA-IFA[9].

Metastasis was common among patients with the CENP-F-like pattern. Among our patients, four cases exhibited significant metastasis: Case 3 had metastases to lymph nodes, bone, and brain; case 4 to the mediastinum, hilum, bone, and multiple abdominal lymph nodes; case 2, with esophageal carcinoma, had a pancreas mass; and case 1, with lower esophageal squamous cell carcinoma, developed metastasis a few months after the initial CENP-F-like pattern detection. These observations suggest that a possible link between the CENP-F-like pattern and metastatic disease in solid tumors, indicating the need for careful monitoring and early intervention.

All four patients who underwent stem cell or bone marrow transplantation (three with myeloid leukemia and one with myelodysplastic syndromes) developed GVHD. This phenomenon has also been reported in previous studies[18]. Although we cannot definitively conclude that the CENP-F-like pattern predicts GVHD in hematologic malignancy transplant patients, it has been observed in chronic renal allograft rejection, suggesting a potential link. This may be due to the loss of tolerance to intracellular antigens released after severe graft destruction, viral infections, or immune dysregulation caused by immunosuppressive drugs[10]. Although more prospective studies are needed, our findings suggest the CENP-F-like

pattern's potential as an indicator for transplant rejection, warranting further investigation.

In line with previous studies, we observed a significant proportion of AID patients among those with the CENP-F-like pattern. Six of the 29 patients with the CENP-F-like pattern had AIDs (2 SLE, 1 rheumatoid arthritis, 1 UCTD, 1 SjS, and 1 primary biliary cholangitis), and all were female. Although three other patients did not receive a clinical diagnosis during our investigation, they showed AID symptoms, such as lumbago with positive HLA-B27. Consistent with a previous report, none of the patients were discovered to have scleroderma in our study[10]. The fluorescence titers of the CENP-F-like pattern were mostly higher than 1∶320 in these AID or suspected AID patients, who also had other AID-associated autoantibodies, such as anti-dsDNA and anti-CCP antibodies. This contrasts with cancer patients, who primarily showed anti-Ro52 antibodies in esophageal carcinoma patients.

In addition to the diseases mentioned above, our study also found that liver diseases and cerebral infarction are associated with the CENP-F-like pattern. The proportions of these conditions in our study were 13.79% and 10.34%, respectively, which are higher than the 7.22% and 1.03% reported in previous studies. These differences may be due to regional and ethnic variations.

Previous studies have reported that liver diseases, including HBV, HCV, and hepatocellular carcinoma (HCC)[10, 28-32], are associated with the CENP-F-like pattern or CENP-F autoantibody. In our study, three patients with cirrhosis and one with HBV infection showed the CENP-F-like pattern, all at high risk for HCC. These patients often had infections, likely due to decreased immunity, intestinal bacterial translocation, and other miscellaneous causes[33]. CENP-F, frequently overexpressed in HCC, plays a critical role in tumorigenesis[22, 28, 34], and its autoantibodies associated with HCC have been reported in several studies[29-30]. This evidence suggests that CENP-F-like patterns could present at various liver disease stages: hepatitis, cirrhosis, and HCC. For cerebral infarction, we found that patients with the CENP-F-like pattern appeared to have a higher likelihood of being diagnosed with cerebral infarction when certain conditions were met simultaneously: (1) age > 60 years; (2) presence of cardiovascular diseases such as hypertension and atherosclerosis. However, the fluorescence titers in these patients were not high (≤ 1∶320), indicating a need for further research to elucidate the role of CENP-F autoantibody in cerebral infarction.

Our large sample analysis revealed the prevalence and clinical significance of the CENP-F-like pattern in Southwest China. Although rare, this ANA-IFA pattern was associated with notable clinical implications. Cancers, including solid and hematologic malignancies, were commonly observed in patients with the CENP-F-like patterns. Additionally, our study indicated potential links between this pattern and both metastasis and GVHD. Besides cancers, AIDs constituted a notable proportion of diagnoses among patients with the CENP-F-like pattern in our cohort. We also identified age over 60 and cardiovascular diseases as common features among the cerebral infarction cases in our cohort.

The limitations of our study include its cross-sectional design, which does not allow for the assessment of long-term predictive value. Prospective studies are needed to evaluate the role of the CENP-F-like pattern in predicting cancer metastasis and GVHD. Future research should also incorporate antigen-specific assays to better understand these associations. In summary, the CENP-F-like pattern, though rare, may serve as an important marker for various diseases, including cancers, AIDs, and cerebral infarction, warranting further investigation.

* * *

Author Contribution SU Zhenzhen and ZHANG Feng are responsible for formal analysis, investigation, and writing--original draft. ZHANG Lijing and HAYISAER YEERKEN are responsible for formal analysis and investigation. YANG Bin and HU Jing are responsible for writing--review and editing. WANG Li and GAO Xuedan are responsible for investigation. ZHANG Junlong is responsible for writing--review and editing. HUANG Zhuochun is responsible for conceptualization and writing--original draft. All authors consented to the submission of the article to the Journal. All authors approved the final version to be published and agreed to take responsibility for all aspects of the work.

Declaration of Conflicting Interests All authors declare no completing interests.

References

[1] KĄDZIELA M, FIJAŁKOWSKA A, KRASKA-GACKA M, *et al*. The art of interpreting antinuclear antibodies (ANAs) in everyday practice. J Clin Med, 2025, 14(15): 5322. doi: 10.3390/jcm14155322.

[2] KUMAR N N, AHMAD DIT AI HAKIM S, GRYGIEL-GÓRNIAK B.

Antinuclear antibodies in non-rheumatic diseases. Arch Immunol Ther Exp (Warsz), 2025, 73(1): 1-20. doi: 10.2478/aite-2025-0004.

[3] 张爱萍, 陈珏. 免疫检查点抑制剂相关肺炎的发病机制及临床诊治进展. 实用临床医药杂志, 2024, 28(6): 133-138. doi: 10.7619/jcmp.20232951.
ZHANG A P, CHEN J. Progress in the pathogenesis, clinical diagnosis and treatment of immune checkpoint inhibitor-related pneumonitis. Journal of Clinical Medicine in Practice, 2024, 28(6): 133-138. doi: 10.7619/jcmp.20232951.

[4] 徐书凝, 贾珠, 张宁. 低滴度抗核抗体阳性与冻融胚胎移植妊娠结局的相关性研究. 重庆医科大学学报, 2024, 49(11): 1474-1478. doi: 10.13406/j.cnki.cyxb.003612.
XU S N, JIA Z, ZHANG N. Correlation between low anti-nuclear antibody titers and pregnancy outcomes after frozen embryo transfer. Journal of Chongqing Medical University, 2024, 49(11): 1474-1478. doi: 10.13406/j.cnki.cyxb.003612.

[5] BONROY C, VERCAMMEN M, FIERZ W, *et al*. Detection of antinuclear antibodies: recommendations from EFLM, EASI and ICAP. Clin Chem Lab Med, 2023, 61(7): 1167-1198. doi: 10.1515/cclm-2023-0209.

[6] TEŠIJA KUNA A, ĐEREK L, DRVAR V, *et al*. Assessment of antinuclear antibodies (ANAs): National recommendations on behalf of the Croatian society of medical biochemistry and laboratory medicine. Biochem Med (Zagreb), 2021, 31(2): 020502. doi: 10.11613/BM.2021.020502.

[7] CHAN E K L, Von MÜHLEN C A, FRITZLER M J, *et al*. The international consensus on ANA patterns (ICAP) in 2021-The 6th workshop and current perspectives. J Appl Lab Med, 2022, 7(1): 322-330. doi: 10.1093/jalm/jfab140.

[8] BARNADO A, MOORE R P, DOMENICO H J, *et al*. Identifying antinuclear antibody positive individuals at risk for developing systemic autoimmune disease: development and validation of a real-time risk model. Front Immunol, 2024, 15: 1384229. doi: 10.3389/fimmu.2024.1384229.

[9] ANDRADE L E C, KLOTZ W, HEROLD M, *et al*. Reflecting on a decade of the international consensus on ANA patterns (ICAP): Accomplishments and challenges from the perspective of the 7th ICAP workshop. Autoimmun Rev, 2024, 23(9): 103608. doi: 10.1016/j.autrev.2024.103608.

[10] CASIANO C A, HUMBEL R L, PEEBLES C, *et al*. Autoimmunity to the cell cycle-dependent centromere protein p330d/CENP-F in disorders associated with cell proliferation. J Autoimmun, 1995, 8(4): 575-586. doi: 10.1016/0896-8411(95)90009-8.

[11] CASIANO C A, LANDBERG G, OCHS R L, *et al*. Autoantibodies to a novel cell cycle-regulated protein that accumulates in the nuclear matrix during S phase and is localized in the kinetochores and spindle midzone during mitosis. J Cell Sci, 1993, 106(Pt 4): 1045-1056. doi: 10.1242/jcs.106.4.1045.

[12] Al-MUGHALES J A. Anti-nuclear antibodies patterns in patients with systemic lupus erythematosus and their correlation with other diagnostic immunological parameters. Front Immunol, 2022, 13: 850759. doi: 10.3389/fimmu.2022.850759.

[13] Von MÜHLEN C A, GARCIA-De La TORRE I, INFANTINO M, *et al*. How to report the antinuclear antibodies (anti-cell antibodies) test on HEp-2 cells: guidelines from ICAP initiative. Immunol Res, 2021, 69(6): 594-608. doi: 10.1007/s12026-021-09233-0.

[14] 邹红云, 晁亚妮, 白文栋, 等. 系统性红斑狼疮患者抗核抗体的表达及临床表现分析. 成都医学院学报, 2021, 16(5): 591-594. doi: 10.3969/j.issn.1674-2257.2021.05.010.
ZOU H Y, CHAO Y N, BAI W D, *et al*. Expression of antinuclear antibody and clinical manifestataion in patients with systemic lupus erythematosus. Journal of Chengdu Medical College, 2021, 16(5): 591-594. doi: 10.3969/j.issn.1674-2257.2021.05.010.

[15] RATTNER J B, REES J, WHITEHEAD C M, *et al*. High frequency of neoplasia in patients with autoantibodies to centromere protein CENP-F. Clin Invest Med, 1997, 20(5): 308-319.

[16] BONACI-NIKOLIC B, ANDREJEVIC S, BUKILICA M, *et al*. Autoantibodies to mitotic apparatus: association with other autoantibodies and their clinical significance. J Clin Immunol, 2006, 26(5): 438-446. doi: 10.1007/s10875-006-9038-y.

[17] FRITZLER M J, RATTNER J B, LUFT L A M, *et al*. Historical perspectives on the discovery and elucidation of autoantibodies to centromere proteins (CENP) and the emerging importance of antibodies to CENP-F. Autoimmun Rev, 2011, 10(4): 194-200. doi: 10.1016/j.autrev.2010.09.025.

[18] VERMEERSCH P, BOSSUYT X. Prevalence and clinical significance of rare antinuclear antibody patterns. Autoimmun Rev, 2013, 12(10): 998-1003. doi: 10.1016/j.autrev.2013.03.014.

[19] WELNER S, TRIER N H, FRISCH M, *et al*. Correlation between centromere protein-F autoantibodies and cancer analyzed by enzyme-linked immunosorbent assay. Mol Cancer, 2013, 12(1): 95. doi: 10.1186/1476-4598-12-95.

[20] BETANCUR J F, LONDOÑO A, ESTRADA V E, *et al*. Uncommon patterns of antinuclear antibodies recognizing mitotic spindle apparatus antigens and clinical associations. Medicine (Baltimore), 2018, 97(34): e11727. doi: 10.1097/MD.0000000000011727.

[21] WAN Z T, WEN M M, ZHENG C L, *et al*. Centromere protein F in tumor biology: cancer's Achilles heel. Cancer Med, 2025, 14(10): e70949. doi: 10.1002/cam4.70949.

[22] HUANG Y G, CHEN X W, WANG L, *et al*. Centromere protein F (CENPF) serves as a potential prognostic biomarker and target for human hepatocellular carcinoma. J Cancer, 2021, 12(10): 2933-2951. doi: 10.7150/jca.52187.

[23] CHEN M, TANG X, LIANG Y, *et al*. CENPF as a potential biomarker associated with the immune microenvironment of renal cancer. Technol Cancer Res Treat, 2025, 24: 15330338251330791. doi: 10.1177/15330338251330791.

[24] WANG D P, XU W, HUANG M H, *et al*. CENPF knockdown inhibits adriamycin chemoresistance in triple-negative breast cancer via the Rb-E2F1 axis. Sci Rep, 2023, 13(1): 1803. doi: 10.1038/s41598-023-28355-z.

[25] LI J, LIU L, ZONG G, *et al*. Knockdown of CENPF induces cell cycle arrest and inhibits epithelial-mesenchymal transition progression in glioma. Oncol Lett, 2024, 29(1): 61. doi: 10.3892/ol.2024.14807.

[26] XIE L L, SHEN K J, WEI C L, *et al*. Centromere protein F is a potential prognostic biomarker and target for cutaneous melanoma. Biomedicines, 2025, 13(4): 792. doi: 10.3390/biomedicines13040792.

[27] YANG D, WANG J, HU M Q, *et al*. Combined multiomics analysis reveals the mechanism of CENPF overexpression-mediated immune dysfunction in diffuse large B-cell lymphoma *in vitro*. Front Genet, 2022, 13: 1072689. doi: 10.3389/fgene.2022.1072689.

[28] YANG Z Y, CHEN W J, LIU Y H, *et al*. Recent updates of centromere proteins in hepatocellular carcinoma: a review. Infect Agent Cancer, 2025, 20: 7. doi: 10.1186/s13027-024-00630-2.

[29] LI X J, LI Y M, XU A J, *et al*. Apoptosis-induced translocation of centromere protein F in its corresponding autoantibody production in hepatocellular carcinoma. Oncoimmunology, 2021, 10(1): 1992104. doi: 10.1080/2162402X.2021.1992104.

[30] QI S P, LI J, HE X M, *et al*. Identification and validation of novel serum autoantibodies biomarkers for staging liver fibrosis in patients with chronic hepatitis B. Front Med (Lausanne), 2022, 8: 807087. doi: 10.3389/fmed.2021.807087.

[31] ZHOU J S, YANG G M, WANG Z Y, *et al*. CENPs in hepatocellular carcinoma: a comprehensive review of expression patterns, clinical correlations, and functional mechanisms. Am J Cancer Res, 2025, 15(11): 4962-4981. doi: 10.62347/DZQB2243.

[32] BONELLI P, TORNESELLO A L, TUCCILLO F M, *et al*. HCV-related hepatocellular carcinoma: gene signatures associated with TERT promoter mutations and sex. J Transl Med, 2025, 23: 639. doi: 10.1186/s12967-025-06560-w.

[33] 乔杰, 王荣琦, 南月敏. 肝硬化患者感染的易感因素、类型及处理. 中华肝脏病杂志, 2021, 29(10): 1028-1030. doi: 10.3760/cma.j.cn501113-20200908-00507.
QIAO J, WANG R Q, NAN Y M. Susceptibility factors, types and management of infection in patients with liver cirrhosis. Chin J Hepatol, 2021, 29(10): 1028-1030. doi: 10.3760/cma.j.cn501113-20200908-00507.

[34] HO D W, LAM W M, CHAN L, *et al*. Investigation of functional synergism of CENPF and FOXM1 identifies POLD1 as downstream target in hepatocellular carcinoma. Front Med (Lausanne), 2022, 9: 860395. doi: 10.3389/fmed.2022.860395.

（2025－09－25收稿, 2026－02－16修回）

编辑　余　琳

开放获取　本文使用遵循知识共享署名—非商业性使用4.0国际许可协议（CC BY-NC 4.0），详细信息请访问https://creativecommons.org/licenses/by-nc/4.0/。

OPEN ACCESS　This article is licensed for use under Creative Commons Attribution-NonCommercial 4.0 International license (CC BY-NC 4.0). For more information, visit https://creativecommons.org/licenses/by-nc/4.0/.

© 2026《四川大学学报（医学版）》编辑部

Editorial Office of *Journal of Sichuan University (Medical Sciences)*