

Case Report

Asian Pacific Journal of Tropical Medicine

apjtm.org

doi: 10.4103/apjtm.apjtm_935_23

Longitudinally extensive transverse myelitis associated with scrub typhus: A case report

Amit Kumar[1]✉, Rajesh Chetiwal[1], Shweta Tanwar[2]

[1]*Department of Medicine, ESIC Postgraduate Institute of Medical Sciences and Research, Basaidarapur, New Delhi, India*

[2]*Indian Council of Medical Research, New Delhi, India*

ABSTRACT

Rationale: Longitudinally extensive transverse myelitis (LETM) is a rare inflammatory demyelinating disease predominantly associated with autoimmune and inflammatory disorders. Scrub typhus can cause a variety of neurological complications, which may result in poor recovery and long-term disability. This report reveals a rare linkage between LETM and scrub typhus.

Patient concerns: A 24-year-old female presented with a history of fever for 10 days associated with progressive quadriparesis. Physical examination revealed bilateral lower limb weakness (grade 0/5) and bilateral upper limb weakness (grade 2/5) with reduced sensation below the T3 dermatome.

Diagnosis: Scrub typhus presenting with longitudinally extensive transverse myelitis.

Interventions: Steroid pulse therapy with antibiotics supported by early intensive rehabilitation.

Outcomes: Complete recovery was achieved.

Lessons: This case report highlights the importance of considering scrub typhus as a potential cause of LETM in endemic regions, particularly in patients presenting with febrile illness and neurological symptoms.

KEYWORDS: Longitudinally extensive transverse myelitis; Scrub typhus; *Orientia tsutsugamushi*; Case report

1. Introduction

Scrub typhus is a tropical infectious disease caused by *Orientia* (*O.*) *tsutsugamushi*. Transmission to humans occurs by bite of the larva of trombiculid mites. It is a serious public health issue that threatens one billion people worldwide, with around one million cases occurring each year. Recent serological, molecular, genetic, and culture data suggests that the disease is not just limited to the previously known endemic regions of "tsutsugamushi triangle" in Asia, Australia and islands in the Indian and Pacific Oceans[1]. The transovarial transmission in the vector and a reservoir in small mammals has maintained the infection in the nature[2]. The eschar, a painless lesion caused by the bite of infected *Leptotrombidium chigger* mite, initially presents as a small papule which later ulcerates and enlarges with central necrosis, finally turning into a black crust with erythematous halo, is considered a pathognomonic sign but is found only in two-thirds of the cases. The clinical features of scrub typhus are predominantly non-specific and the disease manifestation may range from mild febrile illness with constitutional symptoms such as fever, myalgia, headache, nausea and vomiting to severe life-threatening disease with multi organ involvement, having a high fatality rate[3]. The neurological complications are infrequent but cases describing meningitis, meningoencephalitis, cerebellitis and

✉To whom correspondence may be addressed. E-mail: dramit67@yahoo.com

This is an open access journal, and articles are distributed under the terms of the Creative Commons Attribution-Non Commercial-ShareAlike 4.0 License, which allows others to remix, tweak, and build upon the work non-commercially, as long as appropriate credit is given and the new creations are licensed under the identical terms.

For reprints contact: reprints@medknow.com

©2024 *Asian Pacific Journal of Tropical Medicine* Produced by Wolters Kluwer-Medknow.

How to cite this article: Kumar A, Chetiwal R, Tanwar S. Longitudinally extensive transverse myelitis associated with scrub typhus: A case report. Asian Pac J Trop Med 2024; 17(8): 375-378.

Article history: Received 17 December 2023 Revision 14 March 2024
Accepted 21 July 2024 Available online 30 August 2024

acute transverse myelitis associated with scrub typhus have been reported in the literature[4,5]. However, neurological involvement manifesting as longitudinally extensive transverse myelitis (LETM) is an extremely rare phenomenon in scrub typhus[6]. Recently, Garg D *et al*. conducted a literature review and searched major electronic databases in an attempt to locate all reports of neurological manifestations of scrub typhus published. They found that only four patients with acute transverse myelitis have been reported in the literature[7]. Here, we describe a case of LETM in a patient with scrub typhus, emphasizing the importance of considering infectious causes in patients presenting with LETM.

2. Case report

A 24-year-old female, resident of New Delhi, India, was admitted to the emergency department with a 10-day history of high-grade fever, myalgia and progressive weakness of both lower limbs and upper limbs, associated with urinary retention for two days. There was no history of recent travel. On examination, she was conscious and oriented with vital parameters within normal range. There was no rash, petechiae or eschar. Neurological examination revealed normal cognitive functions, isochoric and normoreactive pupils and preserved cranial nerves function. Kernig's and Brudzinski's signs were not present. Motor strength was grade 2/5 in upper extremities and 0/5 in lower extremities (Medical Research Council scale) with reduced sensation below the T3 dermatome. Hyperreflexia was present in all four limbs and Babinski sign was present bilaterally, indicative of an upper motor neuron lesion. A fundus examination found no papilloedema. Other system examination revealed no abnormality.

Laboratory tests showed a hemoglobin of 115 g/dL, hematocrit of 36%, white blood cell count of 12.6×10^9/L, with 82% neutrophils, 16% lymphocytes, 1% monocytes, and 1% eosinophils, a platelet count of 174×10^9/L, and random blood sugar of 98 mg/dL. Mild renal dysfunction was noted with blood urea level of 72 mg/dL and serum creatinine level of 1.2 mg/dL. Serum glutamic oxaloacetic transaminase and glutamic pyruvic transaminase levels were slightly elevated (84 and 126 IU/L, respectively). Total bilirubin and the coagulation profile were both within normal ranges. Chest X-ray was normal. MRI of the spine (Figure 1) demonstrated longitudinally extensive lesion with high T2 signal involving almost the entire cord extending from cervico-medullary junction until conus suggestive of longitudinally extensive transverse myelitis. MRI of the brain was normal. Cerebrospinal fluid examination showed glucose levels of 63 mg/dL, protein levels of 89 mg/dL and WBC count of 3/mm^3. The bacterial, fungal, tubercular cultures and the polymerase-chain-reaction of the cerebrospinal fluid for the detection of enterovirus,

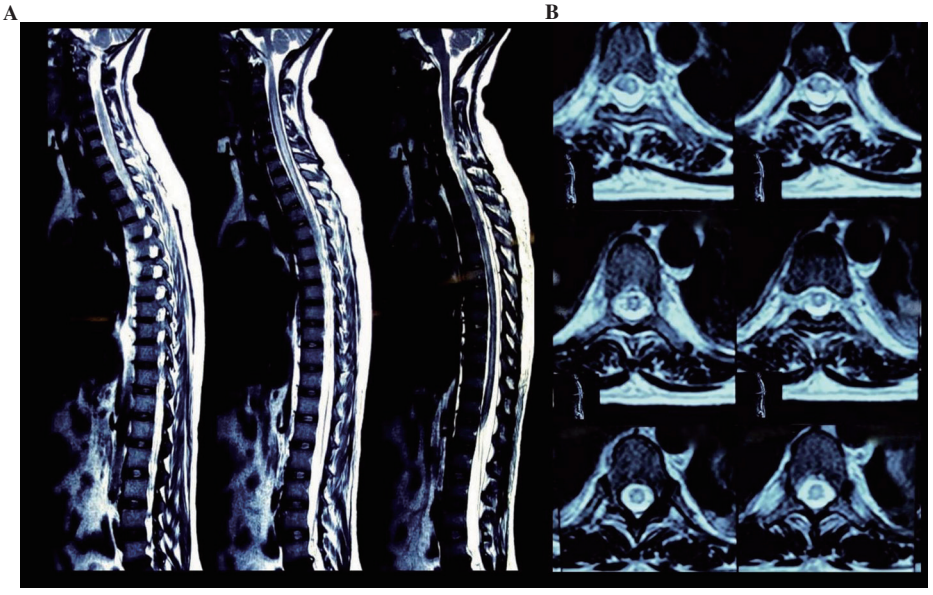

Figure 1. Magnetic resonance imaging scans of the spine of a 24-year-old female presented with a history of fever for 10 days associated with progressive quadriparesis. The pictures show hyperintense signal involving the entire cord extending from cervico-medullary junction until conus, consistent with longitudinally extensive transverse myelitis. A: T2-weighted short tau inversion recovery sequence sagittal images; B: T2-weighted axial images.

herpes simplex virus, Japanese encephalitis virus and SARS-CoV-2 came out to be negative. The peripheral blood smear was negative for malaria parasite. Blood and urine cultures were sterile. Reverse transcription-polymerase chain reaction (RT-PCR) for SARS-CoV-2 in the nasopharyngeal and oropharyngeal samples was found to be negative. Serological tests were performed for dengue, chikungunya, scrub typhus, leptospira, HIV and hepatitis A, B and C viruses, all of which came out to be negative except for IgM antibodies against scrub typhus. Other tests performed for non-infectious and immunological causes (antinuclear antibody, anti-ribonucleoprotein, anti-Ro, anti-La, anti-smith, anti-dsDNA, anti-beta-2-glycoprotein I, lupus anticoagulant and anti-cardiolipin antibodies, rheumatoid factor, complement C3 and C4 levels), including MOG-IgG and AQP4-IgG came out to be negative. Treatment with doxycycline (100 mg twice daily) was initiated. The patient was transferred to the medical intensive care unit in anticipation of potential respiratory involvement requiring ventilatory support. She received intravenous methylprednisolone pulse therapy (1 g/day for five days) along with antibiotic coverage. The patient exhibited a remarkable response to the treatment and physiotherapy. The weakness completely resolved, as evidenced by a motor strength of 5/5 in all four limbs. Following a two-week hospitalization period, the patient was discharged without having any complications or sequelae. The diagnosis of scrub typhus was confirmed with the convalescent sample taken at the time of discharge showing greater than four-fold rise in IgM antibody titer along with detection of IgG antibodies.

3. Discussion

LETM has mainly been linked with neuromyelitis optica and neuromyelitis optica spectrum disorders[8,9]. However, it can be associated with variety of other conditions such as acute disseminated encephalomyelitis, multiple sclerosis, systemic autoimmune diseases (sarcoidosis, systemic lupus erythematosus, Sjögren syndrome, *etc*.), infections, neoplastic and paraneoplastic conditions, vascular diseases and metabolic disorders (vitamin B12, copper deficiency). In our case, scrub typhus was identified as the underlying cause. Scrub typhus is endemic in certain regions, transmitted by chigger mites, and manifests as a febrile illness with multi-organ involvement. Neurological complications, such as meningitis, encephalitis, and myelitis, have been reported but are relatively rare. Lee *et al.* described a case of acute transverse myelitis that occurred along with scrub typhus[10]. Scrub typhus has been an under-reported infection in India both because of non-specificity of clinical features and lack of availability of diagnostic facilities especially in the regions where it is most prevalent such as sub-himalayan foothills. In recent years, scrub typhus has re-emerged as a major cause of acute undifferentiated febrile illnesses with high morbidity and mortality.

The pathogenesis of LETM in scrub typhus remains unclear. Several authors have suggested that *O. tsutsugamushi* has a predisposition for CNS invasion and can cause clinical picture of meningitis and encephalitis[4]. Systemic complications in scrub typhus arise from diffuse endothelial dysfunction and the subsequent development of disseminated intravascular coagulation, which ultimately leads to vasculitis. The blood vessels of the CNS and spinal cord may be affected by the inflammatory process, resulting in acute disseminated encephalomyelitis and acute transverse myelitis. The clinical progression of LETM is rapid and the patient presents with acute onset weakness, bladder dysfunction and sensory involvement. As the clinical consequences are severe and irreversible, it is critical not only to provide prompt treatment but also to establish the etiological diagnosis so as to improve the short-term and long-term outcomes and also to prevent further demyelinating episodes involving CNS and the spinal cord.

In conclusion, this case report highlights the association between scrub typhus and LETM. Scrub typhus should be considered as a potential infectious cause in patients presenting with LETM, particularly in endemic regions. A high index of clinical suspicion is key for early diagnosis and timely institution of therapy is critical for complete recovery and long-term outcome.

Conflict of interest statement

The authors declare that they have no conflict of interest.

Funding

The authors received no extramural funding for the study.

References

[1] Jiang J, Richards AL. Scrub typhus: No longer restricted to the tsutsugamushi triangle. *Trop Med Infect Dis* 2018; **3**(1): 11.

[2] Kelly DJ, Fuerst PA, Ching WM, Richards AL. Scrub typhus: The geographic distribution of phenotypic and genotypic variants of *Orientia*

tsutsugamushi. *Clin Infect Dis* 2009; **48**(Suppl 3): S203-230.

[3] Bolla T, Bhattarai S, Singh H, Suri V, Bhalla A, Chatterjee D. Myositis and rhabdomyolysis in scrub typhus infection: A case report. *Asian Pac J Trop Med* 2023; **16**(4): 187-189.

[4] Kim DE, Lee SH, Park KI, Chang KH, Roh JK. Scrub typhus encephalomyelitis with prominent focal neurologic signs. *Arch Neurol* 2000; **57**(12): 1770-1772.

[5] Ryu HS, Moon BJ, Park JY, Kim SD, Seo SK, Lee JK. Acute transverse myelitis following scrub typhus: A case report and review of the literature. *J Spinal Cord Med* 2020; **43**(4): 548-551.

[6] Mahajan SK, Kumar S, Garg M, Kaushik M, Sharma S, Raina R. Scrub typhus with longitudinally extensive transverse myelitis. *J Vector Borne Dis* 2016; **53**(1): 84-86.

[7] Garg D, Manesh A. Neurological facets of scrub typhus: A comprehensive narrative review. *Ann Indian Acad Neurol* 2021; **24**(6): 849-864.

[8] Sharma D, Sharma A, Singh B, Kumar S, Verma SK. Neglected scrub typhus: An updated review with a focus on omics technologies. *Asian Pac J Trop Med* 2022; **15**(12): 531-541.

[9] Kitley JL, Leite MI, George JS, Palace JA. The differential diagnosis of longitudinally extensive transverse myelitis. *Mult Scler* 2012; **18**: 271-285.

[10]Lee KL, Lee JK, Yim YM, Lim OK, Bae KH. Acute transverse myelitis associated with scrub typhus: Case report and a review of literatures. *Diagn Microbiol Infect Dis* 2008; **60**: 237-239.

Publisher's note

The Publisher of the *Journal* remains neutral with regard to jurisdictional claims in published maps and institutional affiliations.

Edited by Pan Y, Lei Y, Zhang Q