

Case Report

Asian Pacific Journal of Tropical Medicine

apjtm.org

doi: 10.4103/apjtm.apjtm_874_23

Borderline lepromatous leprosy: A case report

Nilshan Fernando[1]✉, Chiranthi Welhenge[1], Ranjan Premaratna[2,3], Ahamed Uwyse[4]

[1]*Registrar in Medicine, University Medical Unit, Colombo North Teaching Hospital, Ragama, Sri Lanka*

[2]*Honorary Consultant Physician in Medicine, University Medical Unit, Colombo North Teaching Hospital, Ragama, Sri Lanka*

[3]*Department of Medicine, Faculty of Medicine, University of Kelaniya, P.O Box 6, Thalagolla Road, Ragama, Sri Lanka*

[4]*Department of Dermatology, Colombo North Teaching Hospital, Ragama, Sri Lanka*

ABSTRACT

Rationale: Lepromatous leprosy can have many atypical presentations, obscuring early diagnosis. We present a case of lepromatous leprosy, presenting with atypical features, which made a diagnostic dilemma.

Patient concerns: A 48-year-old man presented with bilateral lower limb oedema and scaly "ichthyosis like" skin rash in both hands and feet, hepatosplenomegaly and pancytopenia, over a course of three months, without any classical features of leprosy. A skin biopsy revealed an unexpected diagnosis of borderline lepromatous leprosy.

Diagnosis: Lepromatous leprosy.

Interventions: Multi-drug regimen treatment with rifampicin, dapsone and clofazimine for lepromatous leprosy.

Outcomes: The patient made a good clinical recovery.

Lessons: In endemic settings, clinicians should be aware of similar atypical manifestations of leprosy to face the global challenge of eradicating this chronic deforming disease.

KEYWORDS: Lepromatous leprosy; Hepatosplenomegaly; Hemophagocytosis; Pancytopenia; Ichthyosis

1. Introduction

Leprosy, a chronic granulomatous infection caused by *Mycobacterium leprae*, predominantly involves the skin and peripheral nervous system. Globally, it remains as a major health challenge, especially in developing countries. Most of the cases reported today are from Southeast Asia[1]. Diagnosis of leprosy is mainly clinical, based on common clinical manifestations confirmed by demonstration of leprosy bacilli in tissue biopsy. The illness is classified into tuberculoid leprosy, lepromatous leprosy or borderline forms, based on the extent of clinical manifestations; usually determined by the patient's cell-mediated immunity. Rare clinical variants of leprosy include histoid leprosy, which presents with cutaneous and subcutaneous erythematous nodules; pure neuritic leprosy, where nerves are involved without skin involvement; and Lucio's leprosy, with initial diffuse skin involvement that results in a 'myxedema-like' picture[2].

Here we present a patient with lepromatous leprosy who presented solely with bilateral lower limb oedema, weight loss, a skin rash resembling ichthyosis and hepatosplenomegaly. The final diagnosis was quite unexpected and was made only through a skin biopsy.

2. Case report

A previously healthy 48-year-old male presented with progressive

✉To whom correspondence may be addressed. E-mail: nilshan.fernando@gmail.com

This is an open access journal, and articles are distributed under the terms of the Creative Commons Attribution-Non Commercial-ShareAlike 4.0 License, which allows others to remix, tweak, and build upon the work non-commercially, as long as appropriate credit is given and the new creations are licensed under the identical terms.

For reprints contact: reprints@medknow.com

©2024 *Asian Pacific Journal of Tropical Medicine* Produced by Wolters Kluwer-Medknow.

How to cite this article: Fernando N, Welhenge C, Premaratna R, Uwyse A. Borderline lepromatous leprosy: A case report. Asian Pac J Trop Med 2024; 17(7): 329-332.

Article history: Received 20 November 2023 Revision 7 March 2024
Accepted 10 July 2024 Available online 25 July 2024

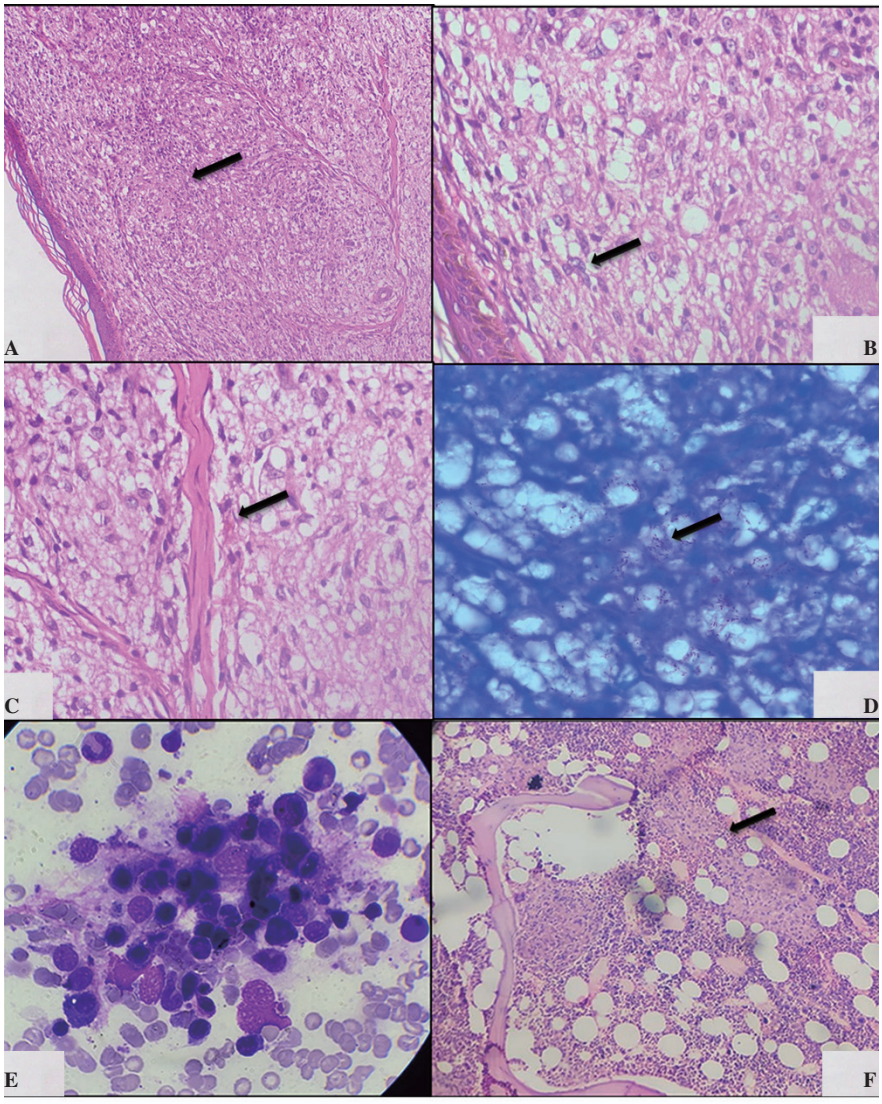

Figure 1. Skin biopsy of a 48-year-old man presented with bilateral lower limb oedema of three-month duration suggestive of borderline lepromatous leprosy. (A) Flattened epidermis with sheets of histiocytes in the dermis suggestive of leprosy (hematoxylin and eosin: magnification ×100), (B&C) Collections of histiocytes in the dermis admixed with lymphocytes, surrounding muscle fibers (hematoxylin and eosin: magnification ×400), (D) Multiple leprae bacilli within macrophages (Wade-Fite: magnification ×1 000). Bone marrow with features of (E) Haemophagocytosis (magnification ×1 000) and (F) Granuloma formation (hematoxylin and eosin: magnification ×40). Arrows indicate the abnormalities in each image.

lower limb oedema of three-month duration without associated facial, abdominal, or scrotal oedema. There was no evidence of acute or chronic renal disease, liver diseases, heart failure, anemia, or hypothyroidism. Later, he developed a symmetrical, scaly, non-itchy rash over both lower limbs, starting from the foot and spreading upwards to involve the extensor surface. A few weeks later, a similar rash appeared over the upper limbs, starting from the dorsum of the hands, and spreading upward. He denied sexual promiscuity.

He had non-pitting oedema in both lower limbs up to mid-calf. His skin was dry with a scaly rash over the extensor surfaces of both upper and lower limbs. The liver and spleen were enlarged; however, he did not have ascites. He had neither thickened ear lobes, loss of eyebrows, nasal deformities, hypopigmented patches, sensory losses over the body nor had thickened ulnar, great auricular, common peroneal or tibial nerves. There were no sensory or motor deficits in upper limbs and lower limbs and joint position sense was intact. There were no cranial nerve palsies. Ocular and fundoscopic examination was normal.

Laboratory tests revealed pancytopenia [white blood cell count (WBC): 3.87×10^3/UL, neutrophils: 3×10^3/UL, hemoglobin: 10.5 g/dL, platelets: 139×10^3/UL], alanine transaminase (ALT): 44 U/L, aspartate transaminase (AST): 41 U/L, total protein: 6 g/dL,

serum albumin: 3 g/dL, globulin: 3 g/dL and serum creatinine: 66.7 μmol/L. Urine full report showed only occasional pus cells and red cells and there was no albumin. Blood picture revealed normocytic normochromic red blood cells with mild leukopenia and mild thrombocytopenia. Ultrasound scan of the abdomen revealed hepatomegaly with fatty liver grade 2 and 17.5 cm splenomegaly. However, the fibro-scan of the liver and an upper gastrointestinal endoscopy were normal. His serum ferritin was 1 408 ng/mL, Thyroid stimulating hormone was 1.62 U/L (0.46-4.68) and serum triglyceride level was 141 mg/dL. His retroviral screening was negative. The hematoxylin and eosin stain of the skin biopsy revealed collections of foamy macrophages arranged in sheets, in the dermis with a few Langhans giant cells admixed with lymphocytes without evidence of nerve destruction. A special stain Wade-Fite showed collections of bacilli within the macrophages and in the dermis, suggestive of lepromatous leprosy (Figure 1). Slit skin smears were not performed since skin biopsy was diagnostic.

The bone marrow aspirate revealed a reactive marrow with increased macrophage activity and hemophagocytosis while the trephine biopsy revealed numerous coalescing non-caseating granulomas with occasional Langhans giant cells, which was supportive of the diagnosis of leprosy (Figure 1).

The patient was commenced on multi-drug regimen treatment with rifampicin, dapsone and clofazimine for lepromatous leprosy, with which he started to make a good recovery. One week after treatment initiation, haematological parameters started to improve (WBC: 4.53×10^3/UL, hemoglobin: 10.5 g/dL, platelets: 238×10^3/UL). Nine months after treatment all haematological parameters were improved (WBC: 8.07×10^3/UL, hemoglobin: 12.7 g/dL, platelets: 234×10^3/UL). ALT: 49 U/L while AST was 43 U/L with no evidence of haemolysis. Five months after initiation of treatment, his peripheral oedema settled and the scaly skin rash disappeared.

3. Discussion

In this case, the initial insidious onset progressive bilateral lower limb swelling mislead the clinical evaluation towards common systemic illnesses. The presence of hepatosplenomegaly with pancytopenia with ichthyotic skin rash pointed towards the possibility of a hematological malignancy, paraneoplastic skin involvement or advanced retroviral infection. However, the Wade-Fite stain of the skin biopsy was suggestive of lepromatous leprosy. Although the initial bilateral lower limb oedema in this patient may suggest Lucio's leprosy, the ichthyoid scaly skin rash is atypical for Lucio's leprosy, at the onset of the disease[2]. An association between leprosy and ichthyosis is rare[3].

The reactive bone marrow aspirate with increased macrophage activity and hemophagocytosis, in the presence of pancytopenia, organomegaly and high serum ferritin levels, pointed the possibility of secondary hemophagocytic lymphohistiocytosis (HLH). Soluble IL2R and NK cell function could not be assessed due to unavailability in the clinical setting. However, the HScore to diagnose HLH was 125 carrying only a 6.6% probability and 2009 HLH diagnostic criteria were not fulfilled. An association between leprosy and HLH has been described in few case reports[4,5], while literature review revealed only one patient with isolated hemophagocytosis[6]. However, since bone marrow examination is not a routine in patients with leprosy, the true incidence of this phenomena is not known yet, and it needs further evaluation.

The presence of numerous coalescing non-caseating granulomas with occasional Langhans giant cells in bone marrow was supportive of disseminated leprosy. The Wade-Fite stain of the bone marrow did not reveal any bacilli within the marrow. Although bone marrow involvement and cytopenia in leprosy is not uncommon as previously assumed, such involvement is seen in patients with classical clinical features and in later stages of illness or in association with leprosy related reactions[7,8].

The liver involvement in multibacillary leprosy ranges from 4%-100% while hepatomegaly is found in 30%-40% of cases[9]. Although hepatosplenomegaly has been described in few patients with leprosy, unlike our patient, these patients were generally more ill with elevated transaminases and had diffuse lepromatous leprosy or leprosy reactions[9,10]. Therefore, this patient was diagnosed solely by the presence of collections of foamy macrophages with leprosy bacilli within and multinucleated giant cells in skin biopsy.

4. Conclusions

In this case, we highlighted the importance of bilateral lower limb non-pitting oedema with an early distally distributed scaly ichthyoid skin rash as a possible early clinical manifestation of lepromatous leprosy. Furthermore, these patients may have hepatosplenomegaly, pancytopenia with bone marrow involvement and hemophgocytosis complicating its diagnosis. We believe that such information may help clinicians to diagnose this chronic deforming stigmatizing illness early.

Conflict of interest statement

The authors declare that they have no conflict of interest.

Ethics statement

Informed written consent to publish the details of the patient was taken from the patient before drafting the manuscript.

Acknowledgements

We acknowledge the support given by Dr. Prabodha Samararathne, consultant histopathologist, Dr. Shanika Fernandopulle, consultant histopathologist, Dr. Yasintha Costa, consultant haematologist, Colombo North Teaching Hospital, Ragama, Sri Lanka, Dr. Kavindya Fernando, lecturer (Department of Biochemistry and Clinical Chemistry), Prof. Gayana Mahendra, consultant histopathologist, Prof. Senani Williams, consultant haematologist, Department of Pathology, Faculty of Medicine, University of Kelaniy, and all other staff members of Department of Histopathology, Department of Haematology, Colombo North Teaching Hospital, Ragama, Sri Lanka, and Department of Pathology, Faculty of Medicine, University of Kelaniya.

Funding

The authors received no extramural funding for the study.

Authors' contributions

NF is the primary author of the article. NF and CW drafted the initial manuscript and did the literature searches. RP and AU supervised the manuscript. All authors participated in manuscript revision, agreed to submit the manuscript and approved the final version of the manuscript. All authors had full access to clinical data.

References

[1] WHO. *Global leprosy (Hansen disease) update, 2019: Time to step-up prevention initiatives.* [Online]. Available from: https://www.who.int/publications/i/item/who-wer9536. [Accessed on 20 November 2023].

[2] Kumar B, Uprety S, Dogra S. Clinical diagnosis of leprosy. In: Scollard DM, Gillis TP, eds. *International textbook of leprosy*. Greenville, SC: American Leprosy Missions; 2017. doi: https://doi.org/10.1489/itl.2.1

[3] Moulick A, Jana A, Sarkar N, Guha P, Mahapatra C, Lallawmzuala K. Non pitting edema, arthritis and ichthyosis; presenting manifestation of leprosy. *Indian J Lepr* 2013; **85**(2): 83-86.

[4] Panda PK, Prajapati R, Kumar A, Jana M, Immanuel P, Tanwar P, et al. A case of leprosy, erythema nodosum leprosum, and hemophagocytic syndrome: A continuum of manifestations of same agent-host interactions. *Intractable Rare Dis Res* 2017; **6**(3): 230-233.

[5] Høyvoll LR, Fløisand Y, Orrem HL, Gunnarsson R, Landrø L, Brevig T, et al. Hemophagocytic lymphohistiocytosis in leprosy. *Lepr Rev* 2015; **86**(4): 403-406.

[6] Zeng XZ, Wang YN, Wang JS, Wu L, Zhang J, Wei Q, et al. A case of lepromatous leprosy complicated by hemophagocytosis misdiagnosed as hemophagocytic lymphohistiocytosis. *Int J Infect Dis IJID Off Publ Int Soc Infect Dis* 2014; **23**: 28-30.

[7] Rastogi P, Chhabria BA, Sreedharanunni S, Pannu A, Varma N, Varma S. Leprosy and bone marrow involvement. *QJM* 2017; **110**(3): 189-190.

[8] Binitha MP, Saritha S, Riyaz N, Mary V. Pancytopenia due to lepromatous involvement of the bone marrow: Successful treatment with multidrug therapy. *Lepr Rev* 2013; **84**(2): 145-150.

[9] Braghiroli NA, Oliveira PD, Sadigursky M, Machado PR. Diagnosing lepromatous leprosy by liver biopsy: A case of granulomatous hepatitis. *Lepr Rev* 2018; **89**(3): 306-309.

[10]Han XY, Seo YH, Sizer KC, Schoberle T, May GS, Spencer JS, et al. A new *Mycobacterium* species causing diffuse lepromatous leprosy. *Am J Clin Pathol* 2008; **130**(6): 856-864.

Publisher's note

The Publisher of the *Journal* remains neutral with regard to jurisdictional claims in published maps and institutional affiliations.

Edited by Pan Y, Lei Y, Zhang Q