

Systematic Review

Asian Pacific Journal of Tropical Medicine

apjtm.org

doi: 10.4103/apjtm.apjtm_456_25

Oral cysticercosis: A systematic review of published case reports

Rezhat Abbas[1]✉, Nazifa Javaid[2]

[1]*Department of Oral & Maxillofacial Pathology and Microbiology, Maulana Azad Institute of Dental Sciences, BSZ Marg, New Delhi, India*

[2]*Department of Oral & Maxillofacial Pathology and Microbiology, Institute of Dental Studies and Technologies, Ghaziabad, Uttar Pradesh, India*

ABSTRACT

Objective: To consolidate the scarce and scattered evidence on oral cysticercosis, a rare and often overlooked manifestation of *Taenia solium* infection.

Methods: A comprehensive literature search was conducted in three major databases: PubMed, Scopus, and Embase. A total of 75 records were initially identified (PubMed: *n*=23; Scopus: *n*=29; Embase: *n*=23). After screening and eligibility assessment, 22 studies meeting inclusion criteria were selected for final analysis.

Results: Oral cysticercosis primarily involved the tongue, typically presenting as a painless swelling. The majority of reported cases were from India. Clinically, it was most often misdiagnosed as a mucocele or fibroma, with cysticercosis rarely considered due to its uncommon occurrence. Among the muscles affected, the masseter, mentalis, and buccinator were most frequently involved. Diagnosis was primarily made through histopathological examination. Treatment commonly included surgical excision, and albendazole was the most frequently used antiparasitic medication. Recurrence was uncommon, except in cases with disseminated or deep muscular involvement.

Conclusions: Oral cysticercosis should be considered a potential differential diagnosis, particularly in regions where pork consumption is common. Given that most reported cases originated from India, pathologists in this region should maintain a high index of suspicion. Oral pathologists, in particular, should be well-acquainted with its histopathological features to ensure accurate diagnosis and avoid diagnostic pitfalls.

KEYWORDS: Cysticercosis; *Taenia solium*; Cyst; Parasite; Oral cavity

1. Introduction

The term cysticercus originates from the Greek words kytis (meaning "cyst") and kertos (meaning "tail"). *Cysticercus* (*C.*) *cellulosae* refers to the larval form of the pork tapeworm, *Taenia* (*T.*) *solium*, which appears in the form of a cyst[1]. Cysticercosis is transmitted through contaminated food. While pigs act as intermediate hosts, humans can function as both definitive and intermediate hosts in the parasite's life cycle[2]. *T. solium* is a cestode of the order Cyclophyllidea and of the family Taeniidae. The adult

Summary

Question: What is the prevalence, clinicopathological presentation, diagnostic profile & treatment outcomes of oral cysticercosis based on currently available evidence?

Findings: In this systematic review of 22 studies, oral cysticercosis most commonly involved the tongue. It typically presented as a painless swelling & was often misdiagnosed as a mucocele or fibroma. Additionally, frequently affected muscles include the masseter, mentalis, and buccinator. Most cases originated from India, with diagnosis primarily established histopathologically. Surgical excision was the primary treatment, often supplemented with albendazole, and recurrence was uncommon except in disseminated or deep muscular cases.

Meaning: Oral cysticercosis should be considered in the differential diagnosis of oral swellings, especially in endemic regions, to prevent diagnostic delays.

✉To whom correspondence may be addressed. E-mail: writetoempire@gmail.com

This is an open access article distributed under the terms of the Creative Commons Attribution-Non-Commercial-No Derivatives License 4.0 (CCBY-NC-ND), where it is permissible to download and share the work provided it is properly cited. The work cannot be changed in any way or used commercially without permission from the journal.

For reprints contact: reprints@medknow.com

©2025 *Asian Pacific Journal of Tropical Medicine* Produced by Wolters Kluwer-Medknow.

How to cite this article: Abbas R, Javaid N. Oral cysticercosis: A systematic review of published case reports. Asian Pac J Trop Med 2025; 18(11): 480-489.

Article history: Received 7 August 2025 Revision 14 October 2025
Accepted 21 November 2025 Available online 28 November 2025

worm, 2-4 m long, resides in the human gut and consists of a scolex with four suckers, a rostellum with 22-32 hooks, and 700-1 000 proglottids, each containing approximately 40 000 eggs. It can release up to 300 000 eggs daily. Eggs, shed *via* feces, contain a 30 μm hexacanth oncosphere with six hooks. In pigs, the oncosphere becomes a fluid-filled cysticercus with an invaginated scolex. The adult worm develops from this scolex upon ingestion[3,4]. In regions with poor sanitation and oral hygiene, pigs may ingest *T. solium* eggs or proglottids shed in human feces. Within the pig's gastrointestinal tract, digestive enzymes break down the egg coverings, releasing oncospheres. These oncospheres penetrate the intestinal wall and spread *via* the blood and lymphatic systems, allowing the larvae to localize in various tissues, particularly the muscles. When humans consume undercooked pork containing these larvae, the parasites develop into adult tapeworms in the small intestine. This represents the typical life cycle of *T. solium*[5,6]. However, humans can also serve as accidental intermediate hosts. This occurs when eggs are ingested through contaminated food, water, or *via* hands soiled with feces. Once ingested, gastric juices dissolve the egg membranes, releasing larvae into the intestine. These larvae then penetrate the intestinal mucosa and disseminate through blood and lymphatic circulation, localizing in various organs and tissues. Human cysticercosis results from this larval migration and deposition, most commonly affecting the brain, muscles, skin, liver, lungs, and heart[7]. In some cases, the larvae may also settle in the oral and perioral regions, particularly within the muscles of mastication[8,9]. Oral cysticercosis is a rare and underreported condition that poses significant diagnostic challenges and is sparsely documented in English-language literature[8]. We intend to conduct a systematic review to address the limited and fragmented evidence on oral cysticercosis, a rare and underdiagnosed manifestation of *T. solium* infection. With most data confined to isolated case reports, there is a lack of comprehensive understanding of its clinical features, diagnostic challenges, and management. This review aims to consolidate existing evidence to support early recognition and informed clinical decision-making.

2. Methods

2.1. Search strategy

The review protocol was registered with the International Prospective Register of Systematic Reviews (PROSPERO) under the registration number CRD420251080588, ensuring methodological transparency and adherence to established standards. The review was conducted in accordance with the PRISMA 2020 guidelines, encompassing all stages of the identification, screening, eligibility assessment, and inclusion.

A comprehensive literature search was performed across three major electronic databases: PubMed, Scopus, and Embase. Boolean operators and Medical Subject Headings (MeSH) were employed to optimize the retrieval of relevant studies. The search string used was: ("oral cysticercosis" OR "cysticercosis") AND ("oral cavity" OR "mouth" OR "buccal mucosa" OR "tongue" OR "lips" OR "cheek" OR "floor of mouth" OR "palate" OR "maxilla" OR "mandible") AND ("case report" OR "case series" OR "case study" OR "case-based review"), which was applied consistently across all databases. The search aimed to capture all available case reports on the topic. Only English-language articles were included, with no restrictions on publication date to ensure the inclusion of both recent and historically significant data. The final search was completed before May 2025. All identified records were imported into Rayyan software, and duplicates were removed prior to screening.

2.2. Selection criteria

2.1.1. Inclusion criteria

Case reports that provided comprehensive clinical, radiological, cytological, and histopathological details of oral cysticercosis.

Articles published in the English language.

Studies that clearly described the diagnostic approach and confirmatory findings supporting the diagnosis of oral cysticercosis.

2.1.2. Exclusion criteria

Review articles, letters to the editor, conference abstracts, or proceedings.

Case reports lacking sufficient or relevant diagnostic information, such as incomplete clinical or histopathological details.

Duplicate reports of the same case.

2.3. Data extraction

Data from each included case report were systematically extracted by two independent reviewers (RA and NJ) using a structured proforma. Any disagreements or discrepancies during data extraction were resolved through discussion and consensus. The extracted parameters included the author and year of publication, country of origin, patient age and sex, anatomical location of the lesion, presenting symptoms and their duration. Additional details such as size of lesion, treatment approach, follow-up period, and final clinical outcome were also documented.

2.4. Risk of bias assessment

Risk of bias across included studies was evaluated using the Joanna Briggs Institute (JBI) Critical Appraisal Checklist for

Table 1. Risk of bias assessment.

No.	Author	Q1	Q2	Q3	Q4	Q5	Q6	Q7	Q8	Yes (%)	Risk of bias
1	Elias *et al.*, 2005	Yes	Yes	Yes	Yes	Yes	Unclear	Unclear	Yes	87.5	Low
2	Goenka *et al.*, 2016	Yes	Yes	Yes	Yes	Yes	Yes	Unclear	Yes	87.5	Low
3	Singh *et al.*, 2017	Yes	Yes	Yes	Yes	Yes	Yes	Unclear	Yes	87.5	Low
4	Chakraborty *et al.*, 2017	Yes	Yes	Yes	Yes	Yes	Yes	Unclear	Yes	87.5	Low
5	Subramanian *et al.*, 2008	Yes	Yes	Yes	Yes	Yes	Yes	Unclear	Yes	87.5	Low
6	Pinswasdi & Charoensiri, 1997	Yes	Yes	Yes	Yes	Yes	Yes	Unclear	Yes	87.5	Low
7	Krishnamoorthy *et al.*, 2012	Yes	Yes	Yes	Yes	Yes	Yes	Unclear	Yes	87.5	Low
8	Sathe *et al.*, 2011	Yes	Yes	Yes	Yes	Yes	Yes	Unclear	Yes	87.5	Low
9	Devulapalli *et al.*, 2015	Yes	Yes	Yes	Yes	Yes	Yes	Yes	Yes	100.0	Low
10	Sagar *et al.*, 2023	Yes	Yes	Yes	Yes	Yes	Yes	Yes	Yes	100.0	Low
11	Mahajan *et al.*, 2009	Yes	Yes	Yes	Yes	Yes	Yes	Unclear	Yes	87.5	Low
12	Meher *et al.*, 2006	Yes	Yes	Yes	Yes	Yes	Yes	Unclear	Yes	87.5	Low
13	Manikandan *et al.*, 2020	Yes	Yes	Yes	Yes	Yes	Yes	Unclear	Yes	87.5	Low
14	Singh *et al.*, 2018	Yes	Yes	Yes	Yes	Yes	Yes	Unclear	Yes	87.5	Low
15	Pujani *et al.*, 2018	Yes	Yes	Yes	Yes	Yes	Yes	Unclear	Yes	87.5	Low
16	Kulkarni PG *et al.*, 2015	Yes	Yes	Yes	Yes	Yes	Yes	Yes	Yes	1000	Low
17	Khare P *et al.*, 2014	Yes	Yes	Yes	Yes	Yes	Yes	Yes	Yes	100.0	Low
18	Chaurasia RN *et al.*, 2013	Yes	Yes	Yes	Yes	Yes	Yes	Yes	Yes	100.0	Low
19	Wanjari SP *et al.*, 2015	Yes	Yes	Yes	Yes	Yes	Yes	Yes	Yes	100.0	Low
20	Dysanoor S *et al.*, 2013	Yes	Yes	Yes	Yes	Yes	Yes	Yes	Yes	100.0	Low
21	Singh S *et al.*, 2011	Yes	Yes	Yes	Yes	Yes	Yes	Yes	Yes	100.0	Low
22	Kumar D *et al.*, 2011	Yes	Yes	Yes	Yes	Yes	Yes	Yes	Yes	100.0	Low

Q1: Were patient's demographic characteristics clearly described? Q2: Was the patient's history clearly described and presented as a timeline? Q3: Was the current clinical condition of the patient on presentation clearly described? Q4: Were diagnostic tests or assessment methods and the results clearly described? Q5: Was the intervention(s) or treatment procedure(s) clearly described? Q6: Was the post-intervention clinical condition clearly described? Q7: Were adverse events (harms) or unanticipated events identified and described? Q8: Does the case report provide takeaway lessons?

Case Reports. All included case reports scored either 87.5% or 100% on the checklist, indicating a consistently low risk of bias. The majority of studies clearly reported patient demographics, history, clinical condition, diagnostic methods, interventions, and outcomes. However, a few studies did not explicitly report post-intervention outcomes or adverse/unanticipated events, which were marked as "Unclear." Despite these minor omissions, the overall methodological quality was high, and no study was excluded based on risk of bias. These findings enhance the reliability of the synthesized data (Table 1).

3. Results

A total of 75 records were retrieved through database searches (PubMed: *n*=23; Scopus: *n*=29; Embase: *n*=23). After eliminating 33 duplicate entries, 42 unique records were available for screening. Titles and abstracts were screened by RA and NJ, resulting in the exclusion of 10 records. The remaining 32 full-text articles were then evaluated for eligibility by the same authors. Of these, 10 articles were excluded, and 22 studies were ultimately included in the final review (Figure 1).

3.1. Sociodemographic features

The reviewed literature comprised 25 cases from 22 articles. Of the 25 documented cases, the majority (23 cases) were reported from India[10–29], with only one case each from Brazil and Thailand[30,31]. This geographic distribution underscores the significant academic and clinical interest in this subject matter within the Indian research community.

The analysis revealed a broad age range among patients, spanning from 7 to 53 years, with a relatively equal distribution between males and females (Table 2).

3.2. Site distribution

The lesions exhibited a diverse anatomical distribution, predominantly affecting the tongue (32%) including the dorsal surface, lateral borders, and ventral aspect[10,11,17,19,20,22,28,30]. Additional involvement was noted in the labial region, encompassing the lower lip (16%), left lower labial mucosa (12%), and right maxillary anterior labial mucosa (4%). The buccal mucosa (16%) was affected bilaterally. Notably, deeper tissue infiltration was observed in the mentalis (8%)[15,21], masseter (8%)[22,27], and buccinator muscles (4%)[25] indicating both mucosal and muscular involvement (Table 2).

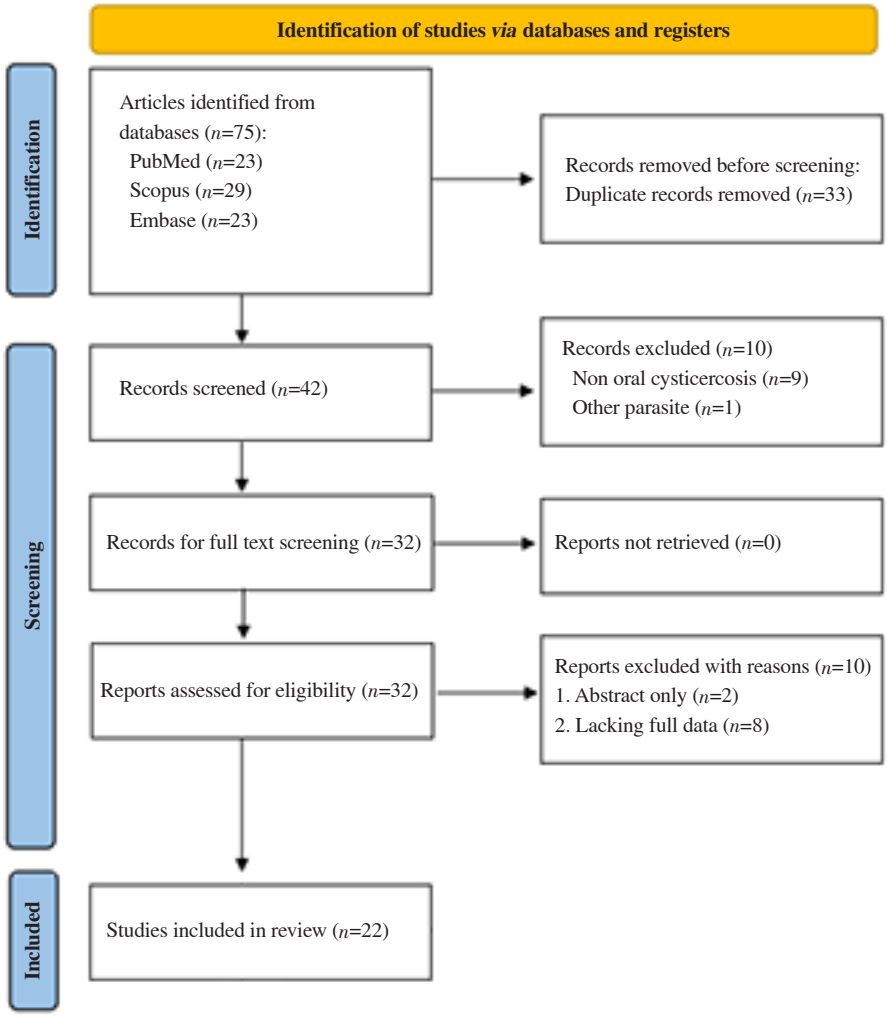

Figure 1. PRISMA flow diagram illustrating the study selection process. The diagram outlines the identification, screening, eligibility assessment, and inclusion of studies for the systematic review.

3.3. Symptoms and duration

The majority of cases presented with painless swellings (60%), frequently described as slow-growing and present for several months to years (ranging from 10 days to 10 years).

A small subset experienced discomfort (15%) difficulty in eating/speaking or recurrent pain, hinting at possible inflammatory or obstructive episodes, especially in muscular locations[23,27,29]. Only a few lesions presented with pain or tenderness, suggesting these were likely benign and of non-inflammatory origin (Table 2).

3.4. Size and consistency

Lesion sizes ranged from 3 mm to 4 cm, with most being around 1-2 cm (90%) in diameter. Firmness was commonly noted (50%), though descriptions varied from soft (28%), cystic (12%), tense, to fluctuant (16%), indicating a spectrum of underlying histological patterns, from mucoceles or fibromas to salivary gland tumors. The surface appearance was generally normal or smooth without mucosal ulceration in most cases[11,13,17,28,29,31]. However, one case exhibited partial ulceration, possibly due to trauma or secondary infection (Table 2).

3.5. Mobility and fixation

Most swellings were mobile and non-fixed, further supporting their benign nature. Some cases showed non-mobile characteristics, which may reflect deeper attachment or chronicity rather than malignancy[10,12,15,16,18](Table 2).

3.6. Diagnostic methods

The diagnostic protocols combined both non-invasive and invasive modalities, including fine-needle aspiration cytology (FNAC),

Table 2. Clinical characteristics, diagnosis, and management of reported cases.

No.	Author & year	Country	Age/sex	Site affected	Symptoms & duration	Size (cm)	Clinical appearance	Diagnosis method	Treatment	Follow-up
1.	Elias FM *et al.*, 2005[30]	Brazil	23/Female	Left dorsal tongue	Painless swelling for about 3 years, discomfort on palpation	1.5	Submucosal, soft, normal mucosa	Excisional biopsy+microscopy	Surgical excision only	Lost to follow-up
2.	Goenka P *et al.*, 2016[28]	India	10/Male	Dorsal surface of tongue	Painless, slow-growing swelling for about 3 years; difficulty eating	1.5×1.5	Oval, firm, nonmobile, nonulcerated nodule	FNAC+excisional biopsy +histopathology	Prednisolone 20 mg TID×5 days, then albendazole 600 mg OD×28 days; surgical enucleation performed	3 years; no recurrence
3.	Cheena Singh *et al.*, 2017[10]	India	45/Male	Right dorsum of tongue	Swelling for 8-9 months; gradual growth; no systemic symptoms	1×1.5	Well-defined, soft to firm, non-tender, normal mucosa	FNAC, ultrasound, Blood tests	Albendazole 200 mg BID×21 days; Wysolone (Prednisone) 20 mg×7 days tapered to 10 mg	60%-70% remission; monthly follow-ups advised
4.	Chakraborty P *et al.*, 2017[11]	India	27/Female	Dorsum of tongue	Painless, gradually enlarging swelling for 6 months	4×4	Tense cystic, nontender, normal mucosa	FNAC+CT scan	Albendazole 15 mg/kg/day×28 days	Complete resolution; no recurrence
5.	Subramanian B *et al.*, 2008[12]	India	20/Male	Lower lip	Painless swelling for 3 months	1	Smooth, non-tender, non-compressible, cystic	Surgical excision +biopsy	Surgical excision only	Lost to follow-up post-op
6.	Pinswasdi P & Charoensiri DJ, 1997[31]	Thailand	30/Male	Left lower labial mucosa	Painless swelling for 9-10 years; gradual growth	1.5×2.0	Well-defined, firm, painless, no discharge/redness	Surgical excision +biopsy	Surgical excision only	Periodic follow-up advised
7.	Krishnamoorthy B *et al.*, 2012[13]	India	12/Female	Lower lip	Painless, stable swelling for 2 months; mild eating/speaking discomfort	1.5×1.5	Solitary, spherical, tense, non-tender, nonfluctuant	FNA +excisional biopsy	Surgical excision+Albendazole 400 mg BID×15 days	Patient lost to follow-up
8.	Sathe NU *et al.*, 2011[14]	India	33/Female	Left lower labial mucosa	Swelling for 8-10 years; increased in size over last 3 months	1.5×1	Smooth, well-defined, painless cystic swelling	FNAC, Excision+Biopsy	Surgical excision only	Not mentioned
9.	Devulapalli RV *et al.*, 2015[15]	India	30/Female	Mentalis muscle	Painless swelling for 5 months; sudden onset, then stable	2×2	Subcutaneous, firm, non-tender, mobile, vestibular obliteration intraorally	USG, MRI, CT+surgical excision +histopathology	Surgical enucleation+Albendazole 400 mg BID×28 days	No recurrence; patient under follow-up
10.	Sagar *et al.*, 2023[16]	India	38/Male	Lower lip	Painless swelling, slowly increasing over 4 months	0.8×0.5	Tiny, firm, partly ulcerated nodular swelling	Excisional biopsy	Excision+Albendazole 400 mg/day×15 days	Routine follow-up to monitor neuro/ocular symptoms
11.	Mahajan *et al.*, 2009[29]	India	19/Female	Left buccal mucosa	Painful swelling for 2 months, difficulty in mastication and swallowing	1×1	Diffuse, tender swelling near mandibular third molar; firm, not fixed	FNAC+excision	Excision under GA	No recurrence in 6 months; regular follow-up
12.	Meher *et al.*, 2006[17]	India	13/Male	Left lateral tongue	Swelling for 1 year, firm, non-tender; no lymphadenopathy	1	Normal tongue movement; localized mass	FNAC+biopsy	Surgical excision+albendazole 400 mg×8 days	Advised follow-up for neuro/ophthalmologic symptoms
13.	Manikandan *et al.*, 2020[18]	India	26/Female	Right buccal mucosa	Painless swelling for 6 months, gradually increasing in size	1.5×1.8 ×1.3	Subcutaneous, soft, non-fixed swelling; well-encapsulated	MRI+USG +surgical excision	Surgical excision+Albendazole 400 mg BID×28 days	Reviewed on day 7, 3 months, 6 months-no recurrence
14.	Singh *et al.*, 2018-C1[19]	India	7/Male	Underside of tongue	Painless swelling, 3 months	0.5×0.7	Yellow, tense, firm swelling, intact mucosa	Excisional biopsy	Surgical excision	4 months-no recurrence
15.	Singh *et al.*, 2018-C2[19]	India	20/Male	Buccal mucosa	Painless swelling, 4 months	1.5×1	Soft, ill-defined swelling	Excisional biopsy	Surgical excision	1 year-asymptomatic
16.	Singh *et al.*, 2018-C3[19]	India	30/Female	Right buccal mucosa	Mild pain, swelling for 3 weeks	1×1.5	Tense, mobile, smooth surface	USG+excision	Surgical excision	Lost to follow-up
17.	Pujani *et al.*, 2018[20]	India	35/Male	Left lateral tongue	Painless swelling, slowly growing for 15 days	2×1.5	Well-defined, non-tender swelling near posterior one-third of tongue	FNAC +histopathology	Surgical excision	Not detailed
18.	Kulkarni *et al.*, 2015[21]	India	32/Female	Mentalis muscle)	Asymptomatic swelling for 5 months	2×1.5	Diffuse swelling on chin; firm, mobile, shiny skin; firm intraoral nodule	MRI +histopathology	Surgical enucleation	Not detailed
19.	Khare *et al.*, 2014[22]	India	12/Female	Right lateral tongue	Painless swelling for 8 months	2.5×2	Firm, non-mobile, non-tender swelling with intact mucosa	FNAC +histopathology	Excision+albendazole 400 mg BID×5 weeks	1 year-no recurrence or systemic signs
20.	Chaurasia *et al.*, 2013[23]	India	22/Female	Right masseter muscle	Recurrent painful cheek swelling for 3 years	1	Mobile, well-defined, non-tender cheek swelling	MRI +histopathology	Excision+post-op steroids	9 months-asymptomatic
21.	Wanjari *et al.*, 2013[24]	India	53/Male	Right cheek, lower third of face	5-6 months	0.3×0.3	Solitary, soft/fluctuant swelling	FNAC, biopsy, stool test	Surgical enucleation, corticosteroids, antihelminthics	Weekly for 3 months, monthly for 3 more; no recurrence over 1 year
22.	Wanjari *et al.*, 2013[24]	India	10/Male	Right labial mucosa (maxillary anterior)	10-12 months	3×2	Solitary, soft/fluctuant swelling	FNAC, biopsy, stool test	Surgical enucleation; no medication prescribed	Monthly for 2 months, then every 3 months; no recurrence over 1 year
23.	Sujatha Dysanoor & Jyoti Pol, 2013[25]	India	35/Female	Right buccinator muscle	10 days, painless swelling	2.0×2.5	Firm, non-tender, non-fluctuant swelling	Ultrasound, aspiration, histopathology	Albendazole 400 mg×21 days, I&D, curettage due to reinfection	Post-therapy resolution confirmed *via* ultrasound
24.	Singh *et al.*, 2011[26]	India	11/Female	Below left lower lip	6 months, painless swelling	1×1	Soft, well-defined, mobile, non-tender	FNAC	Albendazole (21 days)	Resolution after therapy
25.	Kumar *et al.*, 2011[27]	India	18/Female	Right masseter muscle	1 year, intermittent swelling with pain	1.5	Mobile, nontender, firm intraoral swelling; becomes less prominent on clenching	USG, FNAC, MRI, excisional biopsy	Surgical excision under GA; no antihelminthics used	Periodic follow-up advised

FNAC: Fine needle aspiration cytology; TID: Three times a day; OD: One time a day; BID: Twice time a day; MRI: Magnetic resonance imaging; USG: Ultrasonography; I&D: Incision and drainage; GA: General anesthesia.

Table 3. Histopathological features observed in reported cases.

No	Author & year	Scolex identified	Cystic cavity/ wall	Inflammatory infiltrate	Granulomatous inflammation	Calcification	Tegument
1.	Elias FM *et al.*, 2005[30]	Yes	Yes	Yes	NR	No	Yes
2.	Goenka P *et al.*, 2016[28]	No	Yes	Yes	NR	Yes	NR
3.	Cheena Singh *et al.*, 2017[10]	No	Yes	Yes	NR	No	NR
4.	Chakraborty P *et al.*, 2017[11]	No	Yes	Yes	NR	No	NR
5.	Subramanian B *et al.*, 2008[12]	Yes	Yes	NR	NR	NR	NR
6.	Pinswasdi P & Charoensiri DJ, 1997[31]	Yes	Yes	Yes	Yes	NR	NR
7.	Krishnamoorthy B *et al.*, 2012[13]	Yes	Yes	Yes	NR	NR	NR
8.	Sathe NU *et al.*, 2011[14]	Yes	Yes	Yes	NR	Focal	NR
9.	Devulapalli RV *et al.*, 2015[15]	Yes	Yes	Yes	NR	NR	NR
10.	Sagar *et al.*, 2023[16]	Yes	Yes	Yes	NR	NR	NR
11.	Mahajan *et al.*, 2009[29]	No	Yes	Yes	NR	NR	NR
12.	Meher *et al.*, 2006[17]	NR	NR	NR	NR	NR	NR
13.	Manikandan *et al.*, 2020[18]	Yes	Yes	Yes	NR	Yes	NR
14.	Singh *et al.*, 2018-C1[19]	Yes	Yes	NR	NR	NR	NR
15.	Singh *et al.*, 2018-C2[19]	Yes	Yes	NR	NR	NR	NR
16.	Singh *et al.*, 2018-C3[19]	NR	Yes	Yes	NR	NR	NR
17.	Pujani *et al.*, 2018[20]	NR	NR	Yes	NR	NR	Yes
18.	Kulkarni *et al.*, 2015[21]	Yes	Yes	Yes	NR	NR	NR
19.	Khare *et al.*, 2014[22]	Yes	Yes	NR	NR	NR	NR
20.	Chaurasia *et al.*, 2013[23]	NR	NR	Yes	NR	NR	NR
21.	Wanjari *et al.*, 2013[24]	Yes	Yes	Yes	NR	NR	NR
22.	Wanjari *et al.*, 2013[24]	Yes	Yes	Yes	NR	NR	NR
23.	Sujatha Dysanoor & Jyoti Pol, 2013[25]	NR	NR	Yes	NR	NR	NR
24.	Singh *et al.*, 2011[26]	No	Yes	No	NR	NR	NR
25.	Kumar *et al.*, 2011[27]	Yes	Yes	Yes	NR	Yes	Yes
	Total						
	Yes	60%	84%	76%	1%	12%	12%
	No	20%	-	4%	-	12%	-
	NR	20%	16%	20%	99%	72%	88%
	Focal	-	-	-	-	4%	-

NR=Not reported.

ultrasound, MRI, CT, and histopathology. FNAC was the most commonly employed initial diagnostic tool (52%) , used either alone or in conjunction with imaging or surgical excision. Excisional biopsy with histopathological confirmation was central to definitive diagnosis in most cases. Several cases used advanced imaging techniques such as MRI (20%) and CT (8%), particularly when deeper or muscular involvement was suspected. Stool tests and blood tests were also utilized in select cases, especially where systemic parasitic infection was part of the differential[11,14,21–24,27](Table 2).

3.7. Histopathological features

Histopathological evaluation across multiple studies consistently demonstrated characteristic features of *C. cellulosae* infection, including a fibrous capsule, presence of larval scolex (60%), and a mixed inflammatory infiltrate comprising lymphocytes, plasma cells, and eosinophils (84%). Some cases exhibit granulomatous reaction (76%), duct-like invaginations, or calcification (12%)[20,27,30], the latter indicative of a healed or degenerating parasitic cyst. Notably, scolex identification remains a definitive marker, observed in both well-preserved and degenerated cysts (Table 3). FNAC findings, though less definitive than histopathology, often reveal inflammatory cells and may suggest cysticercosis when correlated with imaging showing cysts with scolices. However, FNAC alone may lack sensitivity due to absent or non-visualized scolex or calcification[27,28,30]. Overall, histopathology remains the gold standard, providing conclusive evidence through larval morphology and associated tissue response.

3.8. Common differential diagnoses

Mucocele was the most frequently suspected lesion, cited in over 12 (48%) cases. This is likely due to its commonality, painless cystic presentation, and frequent location on the lower lip and buccal mucosa. Fibroma and lipoma were also recurrently considered, especially in cases presenting with firm, well-circumscribed, painless

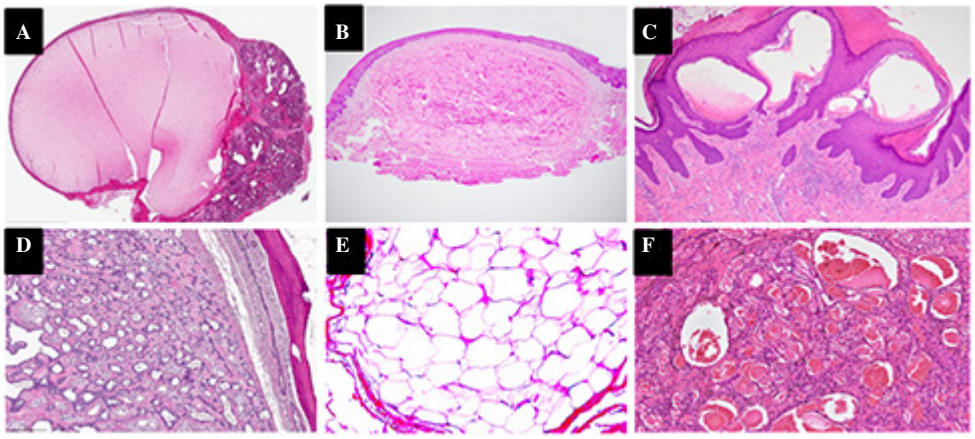

Figure 2. **A:** A mucocele represents mucin-filled cavity surrounded by granulation tissue, lacking an epithelial lining. **B:** Fibrous stroma composed of dense collagen fibers with minimal inflammatory infiltration & absence of cystic cavity. **C:** Enlarged lymphatic vessels lined by a single layer of endothelial cells lacking inflammatory reaction. **D:** Well-formed ductal and tubular structures lined by a double layer of epithelial and myoepithelial cells. No parasitic components. **E:** Lobules of mature adipocytes that are uniform in size and shape, separated by thin fibrous septa. **F:** Benign vascular tumor characterized by a proliferation of blood vessels. No larval structure.

Table 4. Differential diagnosis of oral cysticercosis based on clinical and histopathological features.

No	Differential diagnosis	Clinical features	Histological features	Differentiating points
1.	Mucocele	Fluctuant, bluish lesion on lower lip; asymptomatic	Mucin-filled cavity with granulation tissue; no epithelial lining	No parasite; mucin presence and location (lower lip); history of trauma
2.	Fibroma	Firm, painless, slow-growing nodule; mucosal colored	Dense fibrous connective tissue with sparse inflammatory cells	No cystic space or larva; firm consistency
3.	Lipoma	Soft, yellowish submucosal mass; compressible	Mature adipose tissue in lobules	Fat cells with no cyst or inflammation; typically soft and mobile
4.	Neurofibroma	Soft, painless swelling; tongue, buccal mucosa	Interlacing bundles of spindle cells with wavy nuclei	No cyst or larva; S100 positive; association with NF1
5.	Lymphangioma	Soft, translucent, pebbly surface; mostly in children	Dilated lympha tic channels; lined by endothelium	Presence of lymphatic channels; no inflammatory reaction to parasite
6.	Hemangioma	Bluish compressible mass, may blanch; seen in infants	Proliferation of vascular channels lined by endothelium	Presence of blood vessels; no larval structure
7.	Pleomorphic adenoma	Slow-growing mass in palate/lips	Mixed epithelial and mesenchymal elements; ductal structures	No parasitic components; neoplastic ductal and stromal features

nodules. Vascular lesions such as hemangioma, lymphangioma, and vascular malformations were included in the differential list when soft, fluctuant, or bluish swellings were noted. Salivary gland tumors (including pleomorphic adenoma, minor salivary gland adenoma, and myoblastoma) were suspected particularly in long-standing, slowly enlarging lesions, often located on the buccal mucosa, tongue, or cheek (Figure 2 and Table 4). Neural tumors (*e.g.*, neurofibroma, schwannoma) were considered in tongue and cheek lesions that were firm, painless, and mobile, often mimicking mesenchymal growths. Odontogenic tumors and inflammatory conditions (*e.g.*, pericoronitis-related swelling, lymphadenopathy) were occasionally suspected, particularly when lesions were located adjacent to teeth or salivary structures.

3.9. Treatment modalities

The primary mode of treatment across the board was surgical excision or enucleation. In cases confirmed or suspected as cysticercosis, antihelminthic therapy with Albendazole (44%) (typically 400 mg BID for 15-28 days) was frequently prescribed, often supplemented with corticosteroids like Prednisone or Wysolone to control inflammation and prevent adverse reactions[10,11,13].

Some patients received combination therapy (surgery+medical management), especially where imaging showed multiple or systemic lesions or where FNAC was non-diagnostic[13,15–18,26,28]. A small number of cases had no antiparasitic treatment administered, usually when surgery alone was curative or the postoperative diagnosis remained uncertain (Table 2).

3.10. Follow–up outcomes

Approximately one-third of patients were lost to follow-up, limiting long-term outcome assessment. For those followed systematically, no recurrences were noted in periods ranging from 3 months to over 1 year, affirming the effectiveness of combined surgical and pharmacological approaches. Some cases included structured post-treatment follow-up regimens (*e.g.*, weekly, monthly), particularly where there was initial recurrence, systemic involvement, or atypical presentations[10–12,17,20,21,25]. Follow-up evaluations relied on clinical review and, in some cases, repeat imaging to confirm resolution (Table 2).

4. Discussion

Infection with *C. cellulosae*, the larval form of the pig tapeworm *T. solium*, occurs through the consumption of undercooked pork, ingestion of contaminated food, or direct contact with an infected individual[16]. Cysticercosis is frequently seen in endemic regions such as India, Southeast Asia, Latin America, China, and sub-Saharan Africa. Bizhana *et al.* reported that cysticercosis is more prevalent in countries where pork consumption is common. They highlighted that factors such as increasing international travel and migration, changes in dietary habits due to food scarcity, and political instability leading to population displacement have contributed to the spread of the disease into regions where it was previously rare[32]. Wilson *et al.* noted that individuals diagnosed with cysticercosis may not necessarily reside in endemic areas or have a history of consuming beef or pork[14]. Cysticercosis can affect various parts of the body, including subcutaneous tissue, eyes, liver, peritoneum, heart, and lungs. Despite this wide distribution, skeletal muscles are the most commonly involved sites, while the central nervous system is the primary location for severe symptomatic cases. In the oral cavity, the tongue, labial or buccal mucosa, and floor of the mouth are the areas most frequently affected[14]. Oral cysticercosis remains an exceptionally rare manifestation of *T. solium* infection. The rarity of oral involvement is attributed to several anatomical and physiological factors. The oral cavity, particularly the tongue and buccal musculature, presents an unfavorable environment for the lodgment and encystment of *C. cellulosae* larvae due to constant muscular activity, speech, mastication, and swallowing movements that mechanically dislodge invading larvae before they can establish viable cysts. Moreover, the rich vascularity and robust local immune mechanisms of the oral mucosa, such as salivary enzymes, secretory antibodies, and cellular immune responses-further limit larval survival. Larvae disseminate hematogenously and preferentially lodge in tissues with abundant blood supply but relatively less motion, such as the brain, eye, and skeletal muscles. Hence, oral tissues are less likely to harbor viable cysts. Additionally, small or asymptomatic lesions may go unnoticed or be misdiagnosed as mucoceles, lipomas, or salivary gland swellings, contributing to the apparent low frequency of reported cases. These factors collectively explain why oral cysticercosis is rarely encountered despite the high systemic prevalence of the disease[33,34]. Patients with oral cysticercosis generally complain of swelling, while pain tends to arise only if a secondary infection is present[21]. Several diagnostic techniques are utilized to identify cysticercosis, including imaging studies, serological assays, and histopathological evaluation. While computed tomography and magnetic resonance imaging are highly sensitive, particularly in cases involving the central nervous system, their high cost limits routine use. Serological tests can support the diagnosis when positive; however, a negative result does not exclude the disease. FNAC has gained widespread acceptance as an effective diagnostic tool for cysticercosis. FNAC may reveal components such as fragments of the cysticercus bladder wall, characteristic hooklets, and an inflammatory infiltrate comprising eosinophils, lymphocytes, and multinucleated giant cells[35]. Histopathological examination of oral cysticercosis reveals a cystic cavity housing the larval stage of *T. solium*, known as *C. cellulosae*. This cyst is typically enclosed by a fibrous capsule originating from the host tissue and lined by a distinctive double-layered membrane. The outer membrane is eosinophilic and acellular, while the inner membrane contains sparse cellular elements. The surrounding capsule often shows infiltration by inflammatory cells such as lymphocytes, plasma cells, histiocytes, and occasionally neutrophils and eosinophils. Within the cyst lies the scolex, the larval head, characterized by four suckers and sometimes a rostellum bearing a crown of hooklets[8]. Additional diagnostic methods include testing serum, saliva, or cerebrospinal fluid for antibodies against *C. cellulosae* using enzyme-linked immunosorbent assay or enzyme-linked immunoelectrotransfer blot. Eosinophil levels may be elevated, though they can also remain within the normal range[8]. Surgical excision remains the treatment of choice for parasitic cysts in the maxillofacial region. Due to the presence of a well-defined capsule, complete removal is often achievable, significantly minimizing the risk of recurrence if the cyst is excised in its entirety[36].

When surgery is not feasible, anthelmintic medications like

praziquantel and albendazole are administered. Corticosteroids are often prescribed alongside to mitigate the inflammatory response following larval death. Additionally, anticonvulsants may be used to prevent seizure activity in affected individuals[25]. Praziquantel (administered at 50 mg/kg/day in three divided doses for 15 days) and albendazole (15 mg/kg/day in three divided doses for 1 to 4 weeks) are potent anthelmintics that have largely replaced niclosamide, previously considered the drug of choice. Albendazole, a benzimidazole compound, disrupts the formation of cytoplasmic microtubules in *T. solium* larvae by inhibiting tubulin polymerization. Although the exact mechanism of praziquantel is not fully understood, it is believed to disturb calcium regulation, leading to flaccid paralysis of the larvae. No medical intervention is necessary in patients with inactive disease or calcified cysts[37]. The prognosis of cysticercosis in the maxillofacial region is generally favorable, with low chances of recurrence. Unlike the potentially serious implications of the disease when it affects the brain, eyes, or heart, oral involvement is typically well-tolerated. However, when cysticercosis is associated with multiple or critical anatomical sites, the overall prognosis varies and may become severe, depending on the location and number of larval cysts[8].

5. Conclusions

Oral cysticercosis should be included in the differential diagnosis of solitary intraoral swellings, particularly in regions where the disease is endemic. The present review underscores the importance of all excised tissue specimens for histopathological analysis, as neither clinical examination nor patient history indicated a diagnosis beyond a routine benign lesion. Therefore, both clinicians and oral pathologists should maintain a high index of suspicion for this rare entity and consider it among potential differential diagnoses.

Conflict of interest statement

The authors declare that there is no conflict of interest.

Authors' contributions

R.A conceptualized the study, designed the review methodology, conducted the literature search, screened and extracted data, performed the analysis, and drafted the initial manuscript. N.J verified study selection and data extraction, contributed to interpretation of findings, critically reviewed the manuscript for intellectual content, and assisted in revising the final version. Both authors approved the final manuscript.

Funding

The authors received no extramural funding for the study.

References

[1] Bansal N, Mohanty S, Kadanthode M, Kumar P. Review of cysticercosis of maxillofacial region and report of two cases. *J Stomatol Oral Maxillofac Surg* 2022; **123**(6): e760-e769.

[2] Kusnoto K, Khairullah AR, Sunarso A, Suprihati E, Aryaloka S, Sawitri DH, et al. The hidden threat of cysticercosis: A neglected public health problem. *Open Vet J* 2025; **15**(3): 1101-1115.

[3] Bhardwaj S, Rather G. Fine needle aspiration cytology of cysticercosis: A study of 30 cases. *J Cytol* 2019; **36**(1): 18-21.

[4] Alroy KA, Arroyo G, Gilman RH, Gonzales-Gustavson E, Gallegos L, Gavidia CM, et al. Carotid *Taenia solium* oncosphere infection: A novel porcine neurocysticercosis model. *Am J Trop Med Hyg* 2018; **99**(2): 380-387.

[5] De Souza P, Barreto D, Fonseca LDS, De Paula AB, Silva E, Gomez R. Cysticercosis of the oral cavity: Report of seven cases. *Oral Dis* 2000; **6**(4): 253-255.

[6] Aung AK, Spelman DW. *Taenia solium* taeniasis and cysticercosis in Southeast Asia. *Am Soc Trop Med Hyg* 2016; **94**(5): 947-954.

[7] Paulus S, Abdulloh M, Wardah RI, Cindy C. Long-term albendazole therapy for diffuse parenchymal neurocysticercosis in an immunocompetent patient: A case report. *Asian Pac J Trop Med* 2023; **16**(2): 89-91.

[8] Hosur MB, Byakodi S, Puranik RS, Vanaki SS, Puranik SR, Shivakumar MS. Oral cysticercosis: A case report and review of literature. *J Maxillofac Oral Surg* 2015; **14**(3): 853-857.

[9] Sciutto E, Fragoso G, Fleury A, Laclette JP, Sotelo J, Aluja A, et al. *Taenia solium* disease in humans and pigs: An ancient parasitosis disease rooted in developing countries and emerging as a major health problem of global dimensions. *Microbes Infect* 2000; **2**(15): 1875-1890.

[10]Singh C, Devi MP, Sagar K. Tiny creature in oral cavity: A case report. *JCDR* 2017; **11**(9): ZD04-ZD05.

[11]Chakraborty P, Kumari R, Jain RK, Prasad V, Pradhan S, Joshi P. Solitary head and neck cysticercosis: A series of rare cases. *Iran J Otorhinolaryngol* 2017; **29**(95): 347-351.

[12]Subramanian B, Krishnaraj S, Agrawal K, Soundararagavan J. Cysticercosis of the oral cavity: An often misdiagnosed entity. *J Laryngol Otol* 2008; **122**(9): 1005-1007.

[13]Krishnamoorthy B, Suma GN, Dhillon M, Srivastava S, Sharma ML, Malik SS. Encysted *Tenia solium* larva of oral cavity: Case report with review of literature. *Contemp Clin Dent* 2012; **3**(Suppl 2): S228-S232.

[14]Sathe NU, Acharya RG, Patil M, Bhatia A, Chiplunkar D. An unusual case of labial cysticercosis with a natural history. *Natl J Maxillofac Surg* 2011; **2**(1): 100-102.

[15]Devulapalli R, Bangi B, Nadendla L, Pokala A. Oral cysticercosis: A rare case presentation with ultrasound and MRI findings. *J Indian Acad Oral Med Radiol* 2015; **27**(2): 322-326.

[16]Sagar M, Rawat S, Singh A, Anuragini. Lower lip cysticercosis: An unusual case report. *J Oral Maxillofac Pathol* 2023; **27**(Suppl 1): S95-S97.

[17]Meher R, Gupta B, Aggarwal S, Passey JC. Cysticercosis of tongue-A case report. *Indian J Otolaryngol Head Neck Surg* 2006; **58**(2): 185-187.

[18]Manikandan G, James V, Chandrasekaran C, Varghese S. An atypical case of cutaneous cysticercosis in buccal mucosa. *J Oral Maxillofac Pathol* 2020; **24**(3): 591.

[19]Singh A, Gautam P, Handa AC, Handa KK. Oral cysticercosis: A case series and review of literature. *J Oral Maxillofac Surg* 2018; **76**(12): 2572-2576.

[20]Pujani M, Hassan MJ, Khan S, Jetley S. Isolated lingual cysticercosis: A rare case diagnosed on cytology. *Diagn Cytopathol* 2018; **46**(3): 277-279.

[21]Kulkarni PG, Palakurthy P, Muddana K, Nandan RK. Oral cysticercosis-A diagnostic dilemma. *J Clin Diagn Res* 2015; **9**(6): ZD01-ZD02.

[22]Khare P, Chauhan N, Dogra R, Kala P, Chand P. Isolated cysticercosis of tongue: A case report. *Diagn Cytopathol* 2014; **42**(8): 716-718.

[23]Chaurasia RN, Jaiswal S, Gautam D, Mishra VN. Masseter muscle cysticercosis: A common disease with uncommon presentation. *BMJ Case Rep* 2013; **2013**: bcr2013009127.

[24]Wanjari SP, Patidar KA, Parwani RN, Tekade SA. Oral cysticercosis: A clinical dilemma. *BMJ Case Rep* 2013; **2013**: bcr2012007482.

[25]Dysanoor S, Pol J. A solitary facial nodular swelling-A case report of intramuscular cysticercosis in buccinator muscle. *Asian Pac J Trop Dis* 2013; **3**(3): 235-239.

[26]Singh S, Chhabra S, Aggarwal G, Kalra R, Duhan A, Sen R. Oral cysticercosis-a rare presentation. *Asian Pac J Trop Med* 2011; **4**(7): 587-588.

[27]Kumar Bd, Meghana S, Dave B. Cysticercosis of masseter. *Indian J Dent Res* 2011; **22**(4): 617.

[28]Asopa K, Gumber P, Sarawgi A, Dutta S, Goenka P. Oral cysticercosis in a pediatric patient: A rare case report with review. *Int J Clin Pediatr Dent* 2016; **9**(2): 156-161.

[29]Mahajan S, Agrawal P, Datarkar A, Borle R. Oral cysticercosis: A case report. *J Maxillofac Oral Surg* 2009; **8**(1): 85-87.

[30]Elias FM, Martins MT, Foronda R, Jorge WA, Araújo NSD. Oral cysticercosis: Case report and review of the literature. *Rev Inst Med Trop São Paulo* 2005; **47**(2): 95-98.

[31]Pinswasdi P, Charoensiri DJ. Cysticercosis in labial tissue. Case report. *Aust Dent J* 1997; **42**(5): 319-321.

[32]Bizhani N, Hashemi HS, Mohammadi N, Rezaei M, Rokni MB. Human cysticercosis in Asia: A systematic review and meta-analysis. *Iran J Public Health* 2020; **49**(10): 1839-1847.

[33]Nair PP, Nair KK. Oral cysticercosis: A rare occurrence. *Indian J Dent Res* 2009; **20**(1): 121-123.

[34]Mittal A, Das D, Murari A, Sharma R. Oral cysticercosis: Report of five cases and review of literature. *J Oral Maxillofac Pathol* 2013; **17**(1): 72-76.

[35]Bhardwaj S, Rather G. Fine needle aspiration cytology of cysticercosis: A study of 30 cases. *J Cytol* 2019; **36**(1): 18-21.

[36]Reddi SP, Morales MJ, Addante RR. Solitary lesion in the masseter muscle. *J Oral Maxillofac Surg* 2001; **59**(1): 71-75.

[37]Bansal N, Mohanty S, Kadanthode M, Kumar P. Review of cysticercosis of maxillofacial region and report of two cases. *J Stomatol Oral Maxillofac Surg* 2022; **123**(6): e760-e769.

Publisher's note

The Publisher of the *Journal* remains neutral with regard to jurisdictional claims in published maps and institutional affiliations.

Edited by Pan Y, Lei Y, Zhang Q