[DOI]10.12016/j.issn.2096-1456.202660014

·防治实践·

数字化设计联合多种材料修复颅颌面骨缺损1例报告及文献回顾

许誉馨，吕俊，殷楚媛，庹炎，徐帅
陆军军医大学第二附属医院口腔科，重庆（400038）

【摘要】 目的 探讨以数字化设计为核心，联合3D打印技术与钛网、聚醚醚酮（PEEK）、钛板多材料的个体化一期修复方案在因交通事故导致的复杂颅骨-颌骨-眶骨-颧骨联合缺损中的可行性、精准性及应用价值，为临床复杂颅颌面骨缺损的一期修复提供参考。**方法** 选取2021年9月收治的1例车祸致右侧颅颌面多发粉碎性骨折伴大面积骨缺损患者，以数字化设计贯穿修复全程：首先对术前CT数据进行颅颌面三维重建，再基于模型通过镜像技术复刻左侧健侧轮廓，然后采用3D打印PEEK材料重建右侧眶底及颧上颌复合体，以0.6 mm钛网修复右侧颅骨缺损，用2.0 mm钛板对下颌骨骨折行坚强内固定，同期完成一期手术；并对复杂颅颌面联合缺损的修复相关研究进行文献回顾。**结果** 术后1周CT检查显示，植入体平均贴合间隙为0.3 mm，面部轮廓对称差值< 5 mm；术后3个月，患者最大张口度达三横指，咬合关系恢复正常，复视症状消失；术后5年随访期间，未出现植入物松动、感染、移位等并发症，整形美容患者生存质量（FACE-Q）量表评分95分，患者主观满意度高。文献回顾结果表明数字化设计联合3D打印技术可显著提高复杂颅颌面骨缺损修复精准度，PEEK材料适用于眶底及颧上颌复合体修复，钛网与钛板可保障修复稳定性，多材料联合修复是此类缺损的重要治疗方向。**结论** 以数字化设计为核心，联合3D打印技术与钛网、PEEK、钛板多材料的个体化一期修复方案，可实现交通事故所致复杂颅颌面骨缺损的精准解剖复位与功能同步恢复。

【关键词】 颅颌面外伤；　颅颌面骨缺损；　数字化设计；　3D打印技术；　聚醚醚酮；　钛网；　钛板；　个体化修复方案；　一期修复
【中图分类号】 R78　**【文献标志码】** A　**【文章编号】** 2096-1456（2026）06-0565-11
【引用著录格式】 许誉馨，吕俊，殷楚媛，等. 数字化设计联合多种材料修复颅颌面骨缺损1例报告及文献回顾[J]. 口腔疾病防治, 2026, 34(6): 565-575. doi:10.12016/j.issn.2096-1456.202660014.

微信公众号

Digital design combined with multi-materials for the repair of craniofacial bone defects: a case report and literature review

XU Yuxin, LV Jun, YIN Chuyuan, TUO Yan, XU Shuai.　Department of Stomatology, Second Affiliated Hospital of Army Medical University, Chongqing 400038, China
Corresponding author: XU Shuai, Email: xushuai87@tmmu.edu.cn

【Abstract】 Objective To explore the feasibility, precision, and clinical value of a personalized primary repair approach centered on digital design, integrating 3D printing technology with multiple materials such as titanium mesh, polyetheretherketone (PEEK), and titanium plates, for complex craniofacial bone defects involving the skull, mandible, orbit, and zygoma resulting from traffic accidents, providing a reference for primary repair of clinically complex craniofacial bone defects. **Methods** One patient who was admitted in September 2021 with multiple comminuted fractures of the right craniomaxillofacial region and large-area bone defects caused by a traffic accident was selected. Digital design was integrated throughout the entire repair process. First, preoperative computed tomography (CT) data were used for 3D reconstruction of the craniomaxillofacial region; then, based on the model, the anatomical contour of the healthy left side was reproduced via mirroring technology for the defects on the right side. A targeted repair plan was designed: 3D-

【收稿日期】2026-01-09；　**【修回日期】**2026-03-31
【基金项目】中国博士后基金面上项目（2023M734255）
【作者简介】许誉馨，住院医师，本科，Email：179274344@qq.com
【通信作者】徐帅，副教授，博士，Email：xushuai87@tmmu.edu.cn

printed PEEK material was used to reconstruct the right orbital floor and zygomaticomaxillary complex, a 0.6-mm-thick titanium mesh was adopted to repair the right skull defect, and a 2.0-mm-thick titanium plate was applied for rigid internal fixation of the mandibular fracture. A one-stage repair surgery was completed simultaneously. In addition, a literature review was conducted on studies related to the repair of complex combined craniomaxillofacial defects. **Results** CT examination at 1 week postoperatively showed that the average fitting gap of the implants was 0.3 mm, and the symmetry difference of the facial contour was less than 5 mm. At 3 months postoperatively, the patient's maximum mouth opening reached 38 mm, the occlusal relationship returned to normal, and the diplopia symptom completely disappeared. During the 6-month postoperative follow-up, no complications such as implant loosening, infection, or displacement occurred; the FACE-Q scale score was 91, indicating a high level of subjective patient satisfaction. The literature review indicated that digital design combined with 3D printing technology can significantly improve the accuracy of complex craniomaxillofacial bone defect reconstruction. PEEK material is suitable for the reconstruction of the orbital floor and zygomaticomaxillary complex. Titanium mesh and plates can ensure the stability of the reconstruction. Multimaterials combined reconstruction represents an important therapeutic strategy for such defects. **Conclusion** The individualized one-stage repair scheme, centered on digital design and combined with 3D printing technology and multimaterials (titanium mesh, PEEK, and titanium plates), can achieve precise anatomical reduction and simultaneous functional recovery for complex combined craniomaxillofacial bone defects caused by traffic accidents.

【Key words】 craniofacial trauma; craniomaxillofacial bone defect; digital design; 3D printing technology; polyetheretherketone; titanium mesh; titanium plate; individualized repair scheme; one-stage repair

J Prev Treat Stomatol Dis, 2026, 34(6): 565-575.

【Competing interests】 The authors declare no competing interests.

This study was supported by the grants from the China Postdoctoral Science Foundation (No. 2023M734255).

交通事故所致的颅颌面多发性粉碎性骨折伴骨缺损是口腔颌面外科极具挑战性的临床难题[1-2]，常累及颅骨、上颌骨、颧骨及眼眶等多个解剖区域，不仅造成严重的面部轮廓畸形，还会导致张口受限、咬合紊乱、复视等功能障碍，甚至出现颅内压异常、脑组织损伤等危及生命的并发症，严重威胁患者的身心健康[3-4]。

目前针对颅颌面骨缺损的临床修复方案主要包括自体骨移植与人工合成材料植入。自体骨移植因良好的骨整合能力与组织相容性，曾是该领域的金标准方案[5-6]。但在复杂缺损场景中存在解剖匹配度低、术后并发症发生率高（约40.0%的患者需二次手术）等局限[7-8]。人工合成材料包括聚甲基丙烯酸甲酯、钛网、羟基磷灰石、聚醚醚酮（polyetheretherketone，PEEK）及钛板等，虽广泛应用[9-11]，但单一材料难以满足复杂颅颌面缺损的多重需求：钛网易发生术后翘曲变形，约15.8%患者需二次手术取出[12-13]；PEEK材料适配性高但成本高昂[14-15]；传统钛板过度使用易导致局部应力集中[16]。如何实现材料性能与缺损需求的精准匹配，成为临床亟待解决的关键问题。

数字外科技术的发展为突破该困境提供了新方向[17-18]，基于术前CT数据三维重建与镜像技术复刻健侧解剖轮廓，可实现修复方案的精准规划，结合3D打印制备的个性化植入体，可显著提升修复精度与手术效率[19]。

本文拟报道1例采用数字化设计驱动的多材料协同修复策略，整合预成型钛网、3D打印PEEK个体化植入体及下颌骨固定钛板，实现多解剖区域的一期精准修复重建的车祸致右侧颅骨-颌骨-眶骨-颧骨联合缺损患者，并进行相关文献复习，旨在探讨该策略的临床可行性，为复杂颅颌面创伤骨缺损的一期修复重建提供更具针对性的临床思路。

1　病例资料

本研究获得患者知情同意并签署《患者知情同意书》。选取2021年9月陆军军医大学第二附属医院口腔颌面外科收治的1例38岁女性患者，患者因车祸致头面部严重多发伤后于外院急诊首诊，家属代诉：车祸致头面部外伤伴意识丧失、呼吸困难2 h；外院诊断为“开放性多发颌面骨折、颅底骨折、创伤性蛛网膜下腔出血”，给予颅骨去骨瓣减压术、清创缝合术及镇痛、解痉、抗感染对症治疗。伤后第9天患者意识逐渐恢复（Glasgow Coma Scale昏迷评分12分），病情趋于稳定后转入

我院接受专科诊疗，患者既往体健，无明确器质性疾病史。

1.1　术前检查与评估

1.1.1　全身情况与专科查体　患者入院时生命体征平稳，神志淡漠，气管导管固定在位，无法言语应答；双侧瞳孔等大等圆，瞳孔直径约3 mm，对光反射正常；四肢肌力、肌张力正常，生理反射存在，病理征未引出，未查及偏瘫、失语等神经功能缺损体征；其余全身系统查体未见明显异常。

专科查体：患者右侧颜面部塌陷，上唇部、右侧鼻唇沟、眶下缘及额顶颞部可见清创术后瘢痕，伴右侧眶周肿胀、结膜充血，眼球运动受限；右侧颅骨凹陷明显；张口轻度受限（最大张口度约为两横指）[20]，咬合关系紊乱呈开𬌗状态，伴偏侧咀嚼倾向；未查及脑脊液耳漏、鼻漏体征（图1）。

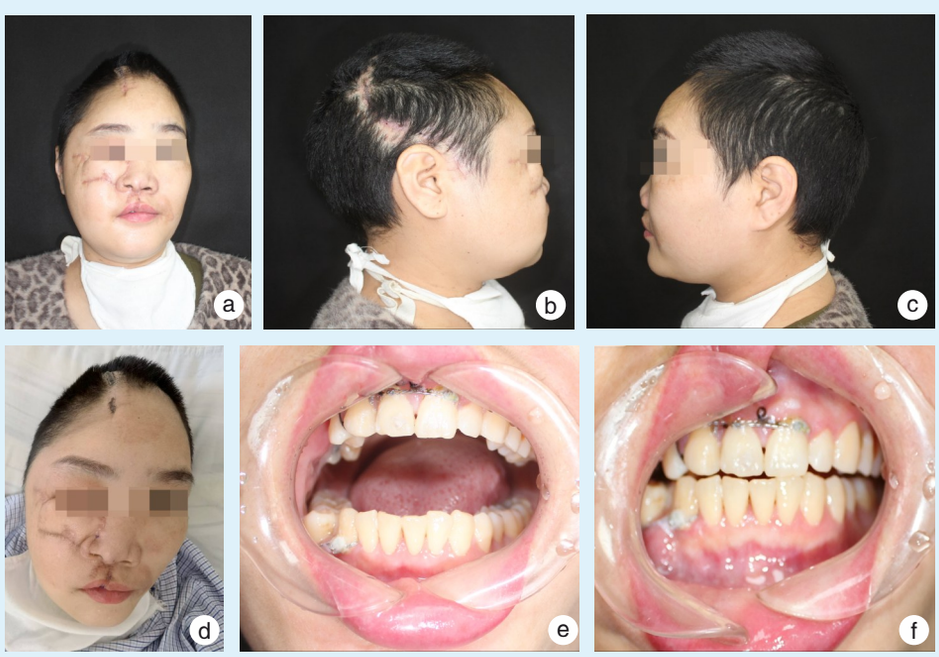

a-c: frontal and lateral views showing obvious collapse of the right facial region. Note the debridement scars on the upper lip, right nasolabial fold, infraorbital margin, and frontoparietotemporal region. Right periorbital swelling, conjunctival congestion, and restricted eye movement were also observed. A tracheal tube was fixed in situ; d: significant depression of the right cranial vault; e: mild restriction of mouth opening (maximum mouth opening approximately two finger-breadths); f: malocclusion manifesting as open bite and signs of unilateral mastication

Figure 1　Preoperative physical examination of a patient with complex craniomaxillofacial bone defects caused by a traffic accident

图1　因交通事故导致的复杂颅颌面骨缺损患者术前专科查体情况

1.1.2　影像学与模型制备　入院后行头颈部64排螺旋CT检查（PHILIPS，荷兰），扫描参数设定为层厚1 mm，层间距0.625 mm，像素矩阵512×512，CT影像示：右侧额顶颞部骨缺损（范围约12 cm×9 cm）；右侧上颌骨体及颧弓粉碎性骨折伴骨缺损；右侧眶底壁缺失；右侧下颌骨体部斜行骨折；右侧颅底粉碎性骨折。为辅助手术规划与术中操作，采用光敏树脂材料通过3D打印技术制备1∶1头颅实体模型（精度误差<0.2 mm），用于引导定位导板精准就位及植入体预弯塑形（图2）。

1.1.3　实验室检查与入院诊断　患者入院后完善血常规、肝肾功能、电解质、凝血功能、传染病筛查及血气分析等相关检查，所有检验结果均未见明显异常，无明确手术禁忌证。结合患者外伤史、全身系统查体、颌面部专科查体、影像学检查及实验室检查结果，明确入院诊断为：①开放性颅脑损伤（重型）；②右侧脑外伤去骨瓣减压术后；③右侧颅底粉碎性骨折；④右侧颌面部多发性骨折（上颌骨骨折、颧弓骨折、下颌骨体部斜行骨折）；⑤右侧眼眶骨折；⑥鼻骨骨折。

1.2　数字化设计与修复方案制定

患者入院后遵循创伤救治“先救命、后治伤”

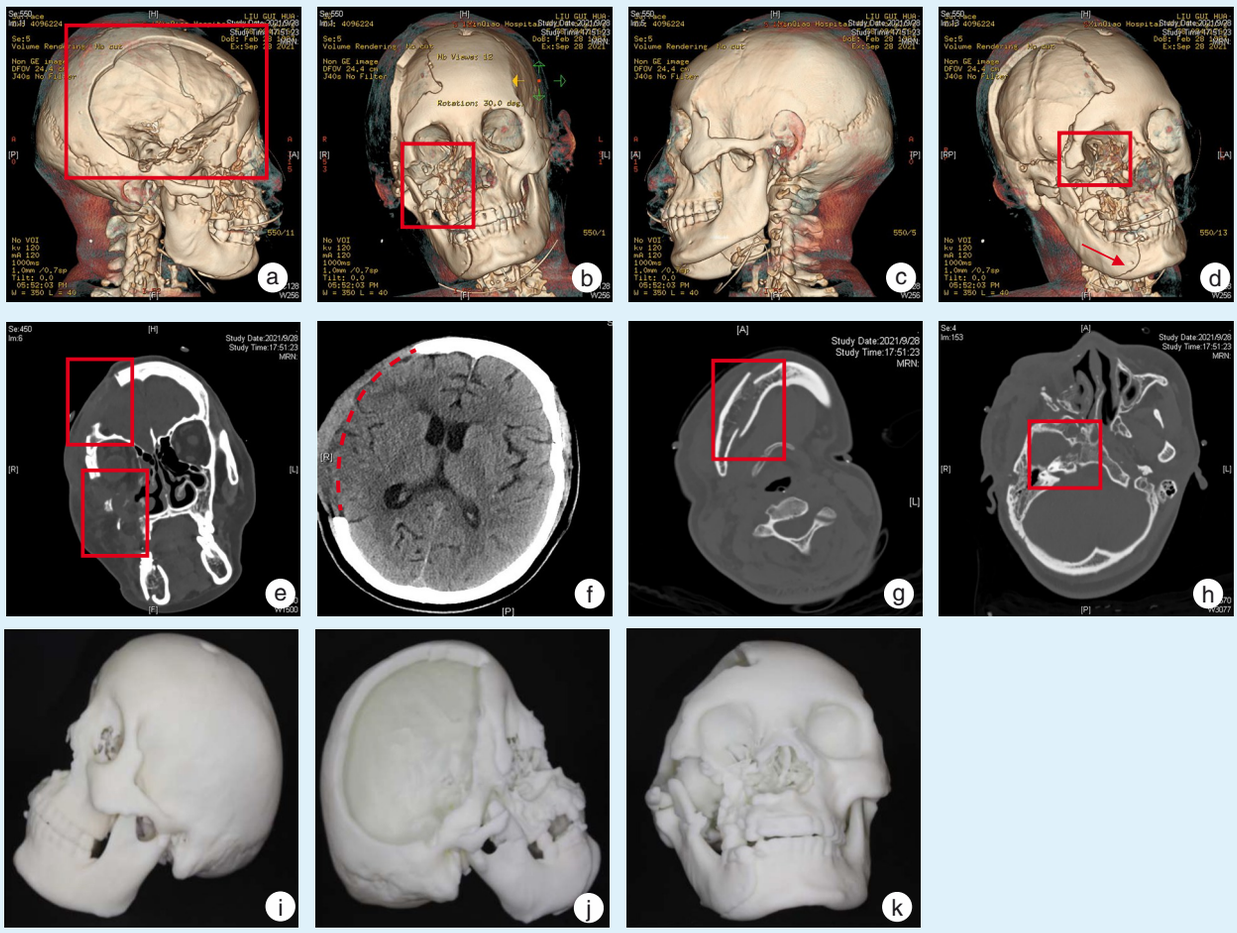

a-d: preoperative head and neck 3D CT reconstruction images, showing a large bony defect (approx. 12 cm × 9 cm) in the right frontoparietotemporal region, comminuted fractures of the right maxillary body and zygomatic arch with bone loss, absence of the right orbital floor, and an oblique fracture of the right mandibular body; e: coronal CT scan revealing the calvarial defect on the right side and comminuted fractures of the right maxillary body and zygomatic arch; f-h: axial CT scans displaying the right front oparietotemporal bone defect (f), oblique fracture of the right mandibular body with displacement (g), and comminuted fracture of the right skull base (h); i-k: left lateral, right lateral, and anterior views of the 1: 1 3D-printed skull model (fabricated from photosensitive resin), used for surgical planning and implant pre-contouring

Figure 2　Preoperative imaging findings and 3D-printed skull physical model of a patients with complex craniomaxillofacial bone defects caused by a traffic accident

图2　因交通事故导致的复杂颅颌面骨缺损患者术前影像学检查结果及3D打印头颅实体模型

的核心原则，于急诊行颅骨去骨板减压术、清创缝合术，同时予以镇痛、解痉、抗感染等对症支持治疗，待患者生命体征平稳，电解质、血常规、凝血功能等实验室指标复查无明显异常，颅脑影像学检查排除颅内迟发性出血，经多学科评估确认无严重全身并发症、具备择期手术耐受条件后，转入口腔颌面外科行颅颌面缺损修复治疗。修复的核心治疗目标为优先重建咬合、咀嚼等口腔生理功能，同步精准恢复颅颌面三维解剖形态，整体治疗以“数字化设计驱动精准修复”为核心理念，全程遵循“以咬合为导向”的设计原则，通过虚拟建模、咬合复位、镜像复刻及多材料适配设计，实现骨折精准复位与骨缺损有效修复，最终达成形态与功能的双重重建。基于上述治疗目标与数字化设计理念，本例患者全流程个体化修复方案分三步制定（图3）：

三维建模与咬合关系分析：将CT数据以DICOM格式导入Mimics 21.0软件（Materialise公司，比利时），重建颅颌面骨骼及牙列数字化模型并导出为STL格式，清晰呈现多部位骨折、骨缺损的解剖关系及牙弓形态异常；基于模型精准分析骨折移位对髁状突位置、牙弓连续性及咬合关系的影响。

咬合导向复位、镜像复刻及缺损边界界定：数

字化模型构建完成后，首先以患者伤前牙尖交错位为导向，采用虚拟复位技术恢复咬合关系，为术后理想咬合奠定基础；以该咬合关系为基准，镜像复刻左侧健侧颅颌面轮廓及正常牙列咬合关系，精准界定右侧缺损边界与范围，明确眶底-颧上颌复合体骨性支撑缺失范围及下颌骨骨折线走向；最终依托预设的理想咬合关系及镜像获取的缺损信息，完成骨折块精准复位与牙列对位调整，实现术后理想咬合状态的数字化预设，确保修复方案与咬合功能恢复目标高度契合。

多材料适配设计：针对不同缺损区域特性及咬合功能需求，选择适配材料并优化修复体形态。①右侧额顶颞部大面积骨缺损：选用0.6 mm厚医用钛网（180 mm×180 mm×0.6 mm，深圳沃尔德，中国），在数字化模型上预演贴合度[21]，确保覆盖缺损区域并与周围颅骨曲面适配；②右侧眶底及颧上颌复合体缺损：设计孔隙率30%[22]、弹性模量3.5 GPa的个体化PEEK植入体（L3W5-S1T1，广州迈普，中国），以镜像后的健侧眶颧颌轮廓及咬合导向下的面中部高度为标准，精准匹配面中部骨性支撑需求，避免因植入体形态偏差导致咬合关系代偿性异常；③右侧下颌骨体部斜行骨折：选用2.0 mm厚6孔直型钛板（447.223，强生，美国），按骨折线走向及咬合复位后的骨块位置设计固定路径，确保骨折端解剖对位，为稳定咬合关系提供骨性支撑。同时，以健侧解剖结构为参照，采用镜像技术虚拟重建患侧眶颧颌区域正常解剖轮廓，设计采用4孔直型钛板（447.222，强生，美国）固定颧弓根，并标记影响面中部缺损修复的骨性高点及游离骨碎片，为术中精准清理提供解剖依据。

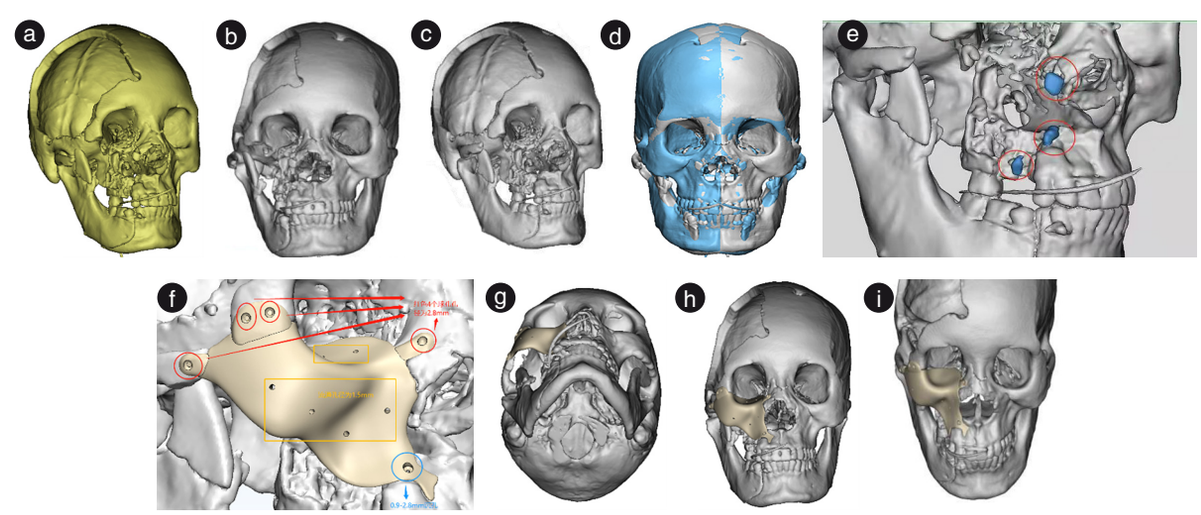

a: original digital reconstruction model of the craniomaxillofacial bones; b & c: anterior and 45° right anterior oblique views of the digital model of the craniomaxillofacial bones after occlusal relationship reduction; d: mirror reconstruction model (blue indicates the mirror bone window, while white indicates the original bone window); e: blue annotation indicates free bone fragments to be removed during surgery (affecting the placement of the PEEK implant); f: design of titanium screws for fixing peek implant (red circles indicate maxillary screw implantation sites, yellow frames indicate flow hole positioning, and blue circle indicate counterbore positioning); g-i: floor of mouth, anterior, and 30° cephalic tilt superior views of the craniomaxillofacial digital model after PEEK implant placement

Figure 3　Preoperative digital repair design for combined skull-maxilla-orbital-zygomatic bone defects

图3　颅骨-颌骨-眶骨-颧骨联合缺损术前数字化修复设计

1.3　模型验证与手术过程

1.3.1　修复体预塑形与适配验证　在1∶1的3D打印头颅实体模型上，结合预设咬合关系完成钛网预弯、钛板塑形及PEEK植入体的匹配性验证（图4），重点核查修复体就位后上下颌牙列的咬合对位情况，调整修复体形态至与缺损区完全适配且不干扰正常咬合运动，所有个性化修复体术前均经高温高压灭菌处理。

1.3.2　一期修复手术　患者全麻下采用联合切口入路（头皮冠状切口+鼻唇沟-睑缘下-耳屏前切口+右下唇龈沟切口），充分显露术区解剖结构后，以术前预设的咬合关系为导向分步操作：

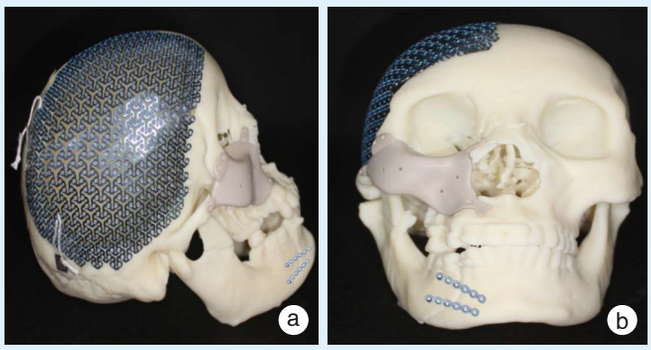

a: right lateral view; b: anterior view

Figure 4　Repair and reconstruction model of the craniomaxillofacial bone defects

图4　颅颌面骨缺损修复重建模型

①颅骨缺损修复：于头皮冠状切口置入预塑形钛网（图5a），覆盖右侧额顶颞部缺损区域，采用16枚钛钉（2.0 mm×0.5 mm，深圳沃尔德，中国）固定。

②下颌骨骨折固定：经下唇龈沟切口显露骨折端，清除骨痂与肉芽组织后按咬合导向完成解剖复位，以颌间牵引钉维持预设咬合稳定，植入预塑形钛板2枚（图5b），用8枚钛钉（411.908，强生，美国）完成固定。

③眶底与颧上颌复合体重建：经鼻唇沟及耳屏前切口显露缺损区，复位骨折块后用4孔直型钛板（447.222，强生，美国）固定颧弓根，按照术前设计去除骨性高点后，再植入PEEK植入体（图5c），通过4枚上颌钉（钉帽直径2.3 mm，高度0.5 mm，钉身直径1.1 mm，长度0.5~0.6 mm）固定于眶外侧壁、颧弓根及鼻骨，术后即时核查咬合关系，确保符合术前设计。

术毕于术区留置负压引流管，按解剖层次分层缝合切口，术后24~48 h根据引流情况拔除引流管，术后1周指导患者开展早期张口功能训练，配合3D打印咬合导板辅助咬合关系维持。本次手术时长11 h10 min，术中出血约1 200 mL，输注A型全血1 650 mL；术后第1天复查血常规未达到术后输血指征，未予输血。

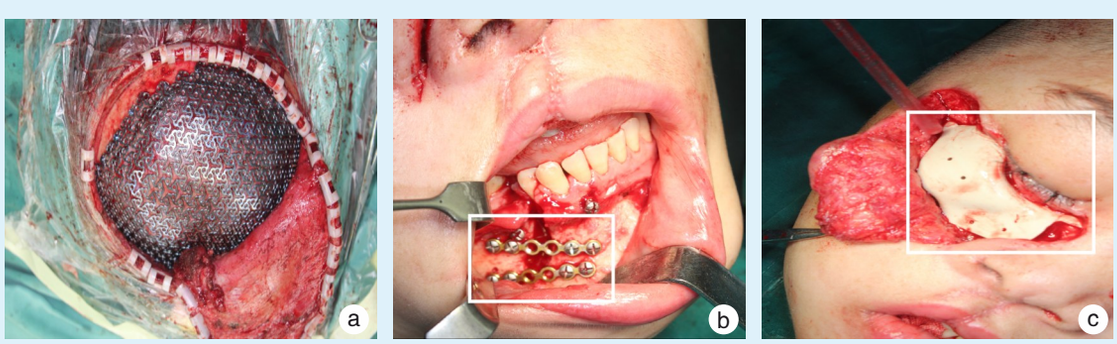

a: internal fixation with medical titanium mesh; b: internal fixation with a titanium plate; c: PEEK implant placement

Figure 5　Intraoperative scenarios of digital design combined with multi-materials for craniofacial bone defect repair

图5　数字化设计联合多种材料修复颅颌面骨缺损的术中情况

2　治疗结果

本病例一期修复手术顺利完成，术中未出现大出血、重要神经血管损伤等严重并发症，术后患者生命体征平稳，术区引流管通畅，24~48 h引流液量逐渐减少至<10 mL/d，遂拔除引流管，切口愈合良好，未发生感染、裂开等情况，术后14 d顺利拆线。

2.1　解剖复位精度评估

术后1周行头颈部CT三维重建复查，结果显示：各植入体位置精准，与受区骨面贴合紧密，钛

网、PEEK植入体及钛板均无移位、变形，右侧额顶颞部颅骨缺损被钛网完整覆盖，颅腔形态恢复正常；眶底及颧上颌复合体骨性支撑结构重建稳定，双侧颧部高度、眶周轮廓基本对称；下颌骨骨折端解剖对位良好，下颌骨下缘连续性恢复（图6a-6c）。采用Geomagic Control X软件进行3D偏差分析，以受区骨面关键解剖标志点配准模型，布设测点并计算相关指标，结果显示，平均贴合间隙为0.3 mm；面部轮廓对称差值最大<5 mm，同步生成偏差云图以提升结果可信度，各项指标均达到精准解剖复位标准（图6d&6e）。

2.2　术后功能恢复情况

术后3个月随访，患者张口功能显著改善，最大张口度达三横指，满足正常进食、言语等生理需求（图6f）；咬合关系恢复正常，开𬌗畸形完全纠正，无偏侧咀嚼倾向，上下颌牙列对位良好（图6g）。眼部功能同步恢复，右侧眶周肿胀、结膜充血消退，眼球运动灵活，复视症状完全消失，视力未出现进一步下降。

术后6个月随访，患者面部外形对称自然，右侧颜面部塌陷、颅骨凹陷等畸形彻底改善，术区瘢痕逐渐淡化，外观满意度较高（图6h）；咀嚼、吞咽、言语功能均恢复正常，无进食呛咳、言语含糊等情况。

术后5年随访，患者咬合关系稳定，张口、咀嚼、吞咽及言语功能稳定良好，最大张口度达三横指，开𬌗畸形无复发，无颞下颌关节不适及偏侧咀嚼等异常；面部外形对称自然，颜面部及颅骨缺损区凹陷无复发，术区瘢痕软化平整，远期疗效稳定可靠。

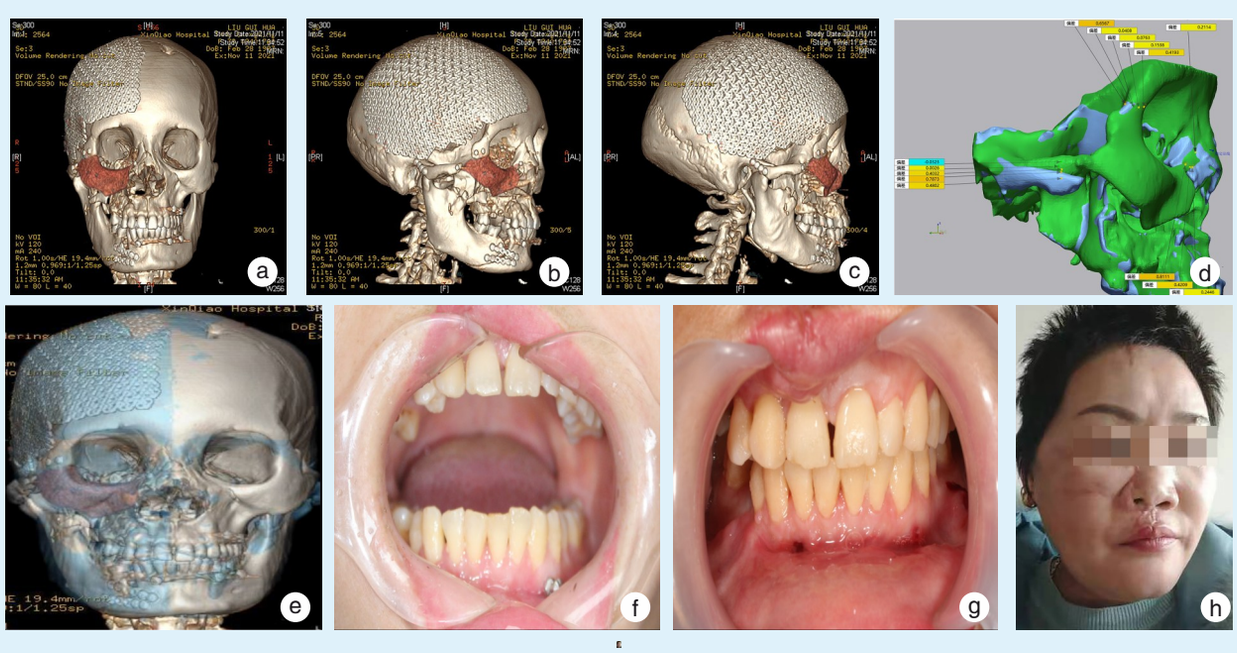

a-c: anterior, oblique, and right lateral views of the maxillofacial CT 3D reconstruction 1 week after surgery; d: three-dimensional deviation analysis of the interfacial fit gap for the PEEK implant reconstructed region; e: schematic of craniofacial symmetry deviation; f: maximum mouth opening up to three finger-breadths 3 months after surgery; g: occlusal relationship returned to normal 3 months after surgery; h: anterior view of the craniomaxillofacial region, with no depression and symmetrical face 6 months after surgery

Figure 6　Postoperative flow-up and evaluation of digital design combined with multi-materials for craniofacial bone defect repair

图6　数字化设计联合多种材料修复颅颌面骨缺损的术后复查及评估

2.3　并发症与患者满意度评估

术后5年随访期间，患者未出现植入物松动、移位、感染、排斥反应等并发症；亦无脑脊液耳漏、鼻漏等迟发性并发症发生，头颅CT复查示植入体周围无明显骨吸收、组织肿胀等异常表现。

采用整形美容患者生存质量（FACE-Q）量表对患者术后6个月及5年的主观满意度进行评估，量表总得分分别为91分和95分[23]，其中面部外形满意度、功能恢复满意度、生活质量影响评分3项核心维度得分均≥88分，提示患者对术后外形改善及

功能恢复效果认可度高，心理状态明显好转，已能正常回归家庭及社会生活。

3　讨　论

颅颌面严重多发伤常合并颅脑损伤，救治核心必须遵循“先全身，后局部；先颅脑，后颌面”的阶梯化原则。本病例在急诊阶段优先评估全身状况，重点监测并控制颅脑损伤，在生命体征及颅内情况完全稳定后，再实施颅颌面专科手术治疗，既保证救治安全，也为后期精准修复奠定基础。

复杂颅骨—颌骨—眶骨—颧骨联合缺损修复是口腔颌面外科的重点与难点，其核心在于实现力学支撑、外形重建、功能恢复三者的动态平衡。通过系统梳理2022—2026年间国际高证据级别文献及专家共识[24-26]，本研究进一步明确：此类复杂损伤常合并全身多系统创伤，尤以颅脑损伤最为危急，临床必须坚持“先救命，后治伤”，待全身状况稳定后方可开展颅颌面骨折复位与缺损修复。在此基础上，本病例在生命体征平稳后，依托数字化设计与3D打印技术，采用“医用钛网 + PEEK植入体 + 钛板”多材料联合修复策略，完成复杂缺损的个体化一期修复，并首次在同一病例中同期应用三种植入材料实现功能性重建，践行“个体化设计、多材料适配、精准修复”的理念。治疗中采用咬合导向的数字化方案，经三维建模与咬合分析、缺损边界界定、多材料适配设计三步完成术前规划，并利用1∶1模型完成植入体预成型与匹配验证。

结果显示，该方案显著优化手术流程、缩短操作时间，较传统分期修复具有更高的可行性，提示数字化术前规划在复杂颅颌面缺损的精准修复与风险管控中具有重要应用价值。综上，合并颅脑损伤的复杂颅颌面创伤，只有在全身及颅脑情况稳定的前提下实施专科修复，才能在保障安全的基础上，实现外形与功能的一体化恢复。

3.1　数字化设计结合咬合导向：提升复杂颅颌面骨缺损修复精准性的核心逻辑

精准解剖复位与功能恢复是颅颌面骨缺损修复的核心，咬合关系直接影响疗效[27-28]。本研究将“咬合导向”贯穿数字化设计全程：术前通过CT数据重建模型，结合镜像技术复刻健侧轮廓与咬合关系，预设理想咬合状态并优化修复体形态，规避了传统手术“先塑形后调咬合”的被动性[29]。结果显示，术后植入体平均贴合间隙0.3 mm，面部对称差值<5 mm，3个月咬合关系恢复正常，复视消失，印证该设计可提升手术精准性与可预测性，与其他研究[30]结论一致。此外，3D打印PEEK植入体预设多孔结构促进组织长入，术前1∶1模型预验证进一步保障修复精度，克服传统手工塑形误差大的弊端[31-32]。

3.2　多材料协同应用：适配颅颌面不同区域骨缺损的功能性修复需求

颅颌面多区域骨缺损因解剖结构复杂、生物力学需求差异显著，单一修复材料难以同时满足不同部位的力学支撑、外形恢复及功能重建目标，多材料协同应用可能成为应对这一难题的关键路径。本研究基于各骨缺损区域的解剖特性与功能需求，精准匹配钛网、PEEK植入体及钛板的材料性能，构建个性化修复策略，实现“材料特性—解剖需求—功能目标”的精准适配，其核心应用价值及优势如下：

医用钛网适配颅骨大面积缺损修复，是目前临床该部位修复的优选材料之一[33]。其核心优势体现在3个方面：一是力学性能优异，钛网抗压强度可达210~250 MPa，与人体颅骨抗压强度（160~180 MPa）高度匹配，能够有效抵御外力冲击，为缺损下方脑组织提供可靠的力学保护，降低二次损伤风险[33]；二是塑形能力强，可根据颅骨缺损的不规则形态进行精准塑形[34]，确保与缺损边缘及周围颅骨曲面紧密贴合，保障颅腔完整性；三是临床安全性高，相关研究显示，钛网在各类颅骨成形术材料中的感染率最低，仅为2.6%，且生物相容性良好，长期植入后排斥反应发生率低[35-36]。这些特性使其能够完美适配颅骨大面积缺损对力学支撑和安全性的核心需求。

PEEK植入体在眶底、颧上颌复合体等面中部骨缺损修复中展现出不可替代的优势，尤其适配该区域对功能恢复和外形精度的高要求。从生物力学角度，PEEK材料弹性模量为3~4 GPa，与面部皮质骨弹性模量（7~30 GPa）高度接近，可有效缓解“应力屏蔽效应”，减少修复体周围正常骨组织的吸收，保障修复的长期稳定性[37-39]。从临床实用性来看，PEEK材料具有3大显著优势：一是射线可透性，术后行CT、MRI等影像学检查时无金属伪影干扰，可清晰地评估眶内容物、脑组织及修复体周围组织的愈合情况，这对眶底修复后眼部功能监测至关重要[14, 40]；二是低导热性，环境温度变化时不易发生明显热胀冷缩，可减少对眶周敏感皮肤、

黏膜的刺激，提升患者术后舒适度[14]；三是术中可修整性，可根据术区实际情况通过专用器械精准修剪[41]，进一步提升修复体与骨缺损区域的适配度，同时其预设的300~500 μm多孔结构可引导血管及软组织长入，形成生物学稳定固定，降低术后移位风险[31]。本研究选用孔隙率约30%的PEEK材料，符合口腔颌面外科植入体应用标准，可实现力学性能与生物学性能的良好平衡，契合本研究颅颌面骨缺损修复植入体的设计需求。其核心优势如下：①有效维持植入体结构强度及长期临床稳定性，增强机械固位力，降低术后移位、松动等并发症发生率；②孔隙结构可提供组织长入的适宜微环境，促进软组织生长及细胞黏附、增殖，减少术后感染；③提升材料生物相容性，减轻异物反应，促进植入体与周围组织的界面整合，降低排斥反应发生率。

钛板适配下颌骨线性骨折固定，核心优势在于其良好的生物相容性与充足的机械刚性[42]。下颌骨作为主要咀嚼器官，骨折固定后需快速恢复其力学稳定性，以保障咀嚼、言语等功能的早期恢复。钛板机械强度充足，能够稳固维持骨折端的解剖对位，有效抵御咀嚼过程中产生的咬合力，避免骨折端移位，为骨折愈合提供稳定环境[43]。同时，钛板临床应用成熟，操作便捷，可根据骨折线走向灵活选择固定位置与固定方式，适配不同类型的下颌骨骨折。此外，钛板生物相容性良好，短期植入后引发的软组织刺激、感染等并发症发生率较低，能够满足下颌骨骨折一期固定与功能恢复的临床需求[44-45]。

3.3　本研究的局限性与未来展望

本研究存在以下局限性：其一，样本量受限，本研究为单病例报告，仅观察分析1例患者，虽能详细呈现新技术应用流程及初步效果，但无法排除个体差异对修复效果的影响，循证医学证据等级较低，结论普适性需进一步验证；其二，成本与可及性较差，PEEK材料昂贵，加之数字化设计需专业软件及高精度3D打印设备，且操作流程复杂、对专业人员要求高，限制了其在基层医疗机构的普及。

针对上述局限性，未来研究展望如下：①扩大样本量，开展多中心前瞻性队列研究，纳入不同颅颌面骨缺损类型、年龄层次患者，必要时设计随机对照试验，对比该方案与传统修复方案的疗效，提供高级别循证医学证据。②优化技术方案，依托3D打印产业化降低材料及设备成本，开发智能化设计软件简化流程，降低应用门槛。

【Author contributions】 Xu YX processed the research and wrote the article. Lv J reviewed and revised the article. Yin CY and Tuo Y conducted literature investigation. Xu S supervised the research and coordinated resources. All authors read and approved the final manuscript as submitted.

参考文献

[1] Bavestrello Piccini G ,Sfondrini D ,Tomulescu AS , et al. Modern management of maxillofacial trauma in the emergency department [J]. World J Emerg Med, 2026, 17(1):15-27. doi: 10.5847/WJEM.J.1920-8642.2026.003.

[2] Yari A, Hasheminasab M, Fasih P, et al. The pattern of maxillofacial fractures associated with rollover accidents: a 7-year retrospective study[J]. Dent Traumatol, 2024, 40(2): 213-220. doi: 10.1111/edt.12900.

[3] Chuang KT, Chu YY, Chen CT, et al. Facial fracture patterns and severity of associated injuries after motorcycle accidents[J]. Ann Plast Surg, 2023, 90(1 Suppl 1): S26-S31. doi: 10.1097/SAP.0000000000003355.

[4] Goh EZ, Beech N, Johnson NR. Traumatic maxillofacial and brain injuries: a systematic review[J]. Int J Oral Maxillofac Surg, 2021, 50(8): 1027-1033. doi: 10.1016/j.ijom.2020.12.003.

[5] Schmidt AH. Autologous bone graft: is it still the gold standard? [J]. Injury, 2021, 52 Suppl 2: S18-S22. doi: 10.1016/j.injury.2021.01.043.

[6] Bicak A, Hale J, Day KM. Bilateral orbital reconstruction with autologous bone graft after gunshot wound to upper midface[J]. Cureus, 2021, 13(2): e13611. doi: 10.7759/cureus.13611.

[7] Piitulainen JM, Kauko T, Aitasalo KM, et al. Outcomes of cranioplasty with synthetic materials and autologous bone grafts[J]. World Neurosurg, 2015, 83(5): 708-714. doi: 10.1016/j.wneu.2015.01.014.

[8] Ritter L, Strohhäcker K, Schebesch KM, et al. Complication rates after autologous cranioplasty following decompressive craniectomy [J]. Acta Neurochir (Wien), 2024, 166(1): 380. doi: 10.1007/s00701-024-06282-w.

[9] Chen L, Gao L, Cui H, et al. Finite element comparison of titanium and polyetheretherketone materials for mandibular defect reconstruction[J]. Am J Transl Res, 2024, 16(10): 6097-6105. doi: 10.62347/OXAO9041.

[10] Łuczak W J ,Palusińska M ,Matak D , et al. The future of bone repair: emerging technologies and biomaterials in bone regeneration [J]. Int J Mol Sci, 2024, 25(23): 12766. doi: 10.3390/IJMS252312766.

[11] Wang H, Kang J. Bone grafts and synthetic substitutes in dental applications: a comprehensive review of molecular mechanisms, materials evolution, and clinical perspective [J]. Frontiers in bioengineering and biotechnology, 2025, 13: 1759864. doi: 10.3389/fbioe.2025.1759864.

[12] Kaur N, Kaur T, Kaur J, et al. Efficacy of titanium mesh osteosyn-

thesis in maxillofacial fractures[J]. J Maxillofac Oral Surg, 2018, 17(4): 417-424. doi: 10.1007/s12663-017-1043-6.

[13] Arman SS, Shetty A, Ahmed N, et al. Versatility of titanium mesh in comminuted maxillofacial fractures. a retrospective study[J]. J Maxillofac Oral Surg, 2024, 23(2): 387-393. doi: 10.1007/s12663-022-01745-y.

[14] Sikder P. A comprehensive review on the state of the art in the research and development of poly-ether-ether-ketone (PEEK) biomaterial-based implants[J]. Acta Biomater, 2025, 191: 29-52. doi: 10.1016/j.actbio.2024.11.033.

[15] Peng YN, Liu ZZ, Qiao L. The applicability of polyetheretherketone and titanium mesh in cranioplasty: a retrospective comparative analysis[J]. J Craniofac Surg, 2024, 35(6): 1809-1813. doi: 10.1097/SCS.0000000000010432.

[16] Eliseo S, Mansour A, Miles MG. New innovation: custom titanium zygomaticomaxillary complex (ZMC) plate for facial reconstruction [J]. Cureus, 2024, 16(4): e59379. doi: 10.7759/cureus.59379.

[17] 李劲松, 李群星. 3D打印技术在颌骨精确功能性重建的应用[J]. 口腔疾病防治, 2023, 31(6): 381-388. doi: 10.12016/j.issn.2096-1456.2023.06.001.
Li JS, Li QX. Application of 3D printing technology in the precise functional reconstruction of jaws[J]. J Prev Treat Stomatol Dis, 2023, 31(6): 381-388. doi: 10.12016/j. issn. 2096-1456.2023.06.001.

[18] Wang H, Chi Y, Huang H, et al. Combined use of 3D printing and computer-assisted navigation in the clinical treatment of multiple maxillofacial fractures[J]. Asian J Surg, 2023, 46(6): 2284-2292. doi: 10.1016/j.asjsur.2022.09.116.

[19] 孙坚, 沈毅. 虚拟手术计划辅助颌骨肿瘤切除及缺损精确重建[J]. 口腔疾病防治, 2018, 26(1): 2-9. doi: 10.12016/j.issn.2096-1456.2018.01.002.
Sun J, Shen Y. Using virtual surgical planning for resection of jaw tumor and accurate reconstruction[J]. J Prev Treat Stomatol Dis, 2018, 26(1): 2-9. doi: 10.12016/j.issn.2096-1456.2018.01.002.

[20] 张志愿. 口腔颌面外科学[M]. 8版. 北京: 人民卫生出版社, 2020.
Zhang ZY. Oral and maxillofacial surgery[M]. 8th ed. Beijing: People′s Medical Publishing House, 2020.

[21] 贺文鹏, 张益, 贺洋, 等. 导航辅助眼眶骨折继发眼球内陷的治疗[J]. 中华口腔医学杂志, 2014, 49(11): 641-644. doi: 10.3760/cma.j.issn.1002-0098.2014.11.001.
He WP, Zhang Y, He Y, et al. Correction of enophthalmos following orbital fracture with computer-assisted navigation system[J]. Chin J Stomatol, 2014, 49(11): 641-644. doi: 10.3760/cma.j.issn.1002-0098.2014.11.001.

[22] Du X, Ronayne S, Lee SS, et al. 3D-printed PEEK/silicon nitride scaffolds with a triply periodic minimal surface structure for spinal fusion implants[J]. ACS Appl Bio Mater, 2023, 6(8): 3319-3329. doi: 10.1021/acsabm.3c00383.

[23] Klassen AF, Cano SJ, Schwitzer JA, et al. FACE-Q scales for health-related quality of life, early life impact, satisfaction with outcomes, and decision to have treatment: development and validation[J]. Plast Reconstr Surg, 2015, 135(2): 375-386. doi: 10.1097/PRS.0000000000000895.

[24] Othman A, Al-Mofreh Al-Qahtani F, Al-Qahtani H, et al. Traumatic brain injuries and maxillofacial fractures: a systematic review and meta-analysis[J]. Oral Maxillofac Surg, 2023, 27(3): 373-385. doi: 10.1007/s10006-022-01076-9.

[25] 世界华人神经外科协会颅脑创伤专业委员会, 颅骨缺损修补术专家共识协作组. 颅骨缺损修补术专家共识(2025版)[J/OL]. 中华神经创伤外科电子杂志, 2025, 11(4): 210-219. doi: 10.3877/cma.j.issn.2095-9141.2025.04.002.
Professional Committee of Traumatic Brain Injury, World Association of Chinese Neurosurgeon, Collaborative Group for Expert Consensus of Cranioplasty for Skull Defect. Expert consensus of cranioplasty for skull defect (2025 version)[J]. Chin J Neurotraumatic Surg Electron Ed, 2025, 11(4): 210-219. doi: 10.3877/cma.j.issn.2095-9141.2025.04.002.

[26] 中华口腔医学会口腔颌面修复专业委员会. 下颌骨缺损修复重建治疗专家共识[J]. 中华口腔医学杂志, 2019, 54(7): 433-439. doi: 10.3760/cma.j.issn.1002-0098.2019.07.001.
Society of Oral Maxillofacial Rehabilitation, Chinese Stomatological Association. Expert consensus statement on reconstruction principle for mandibular defect[J]. Chin J Stomatol, 2019, 54(7): 433-439. doi: 10.3760/cma.j.issn.1002-0098.2019.07.001.

[27] Wang H, Chi Y, Hu Y, et al. Accuracy analysis of the digital occlusal relationship reconstruction workflow in patients with maxillofacial fractures: an *in vitro* retrospective cohort study[J]. J Dent, 2025, 154: 105590. doi: 10.1016/j.jdent.2025.105590.

[28] Watanabe T, Hirota M. Revision surgery for malocclusion after open reduction of mandibular fracture: a case report[J]. J Korean Assoc Oral Maxillofac Surg, 2025, 51(1): 54-58. doi: 10.5125/jkaoms.2025.51.1.54.

[29] Qiu F, Xin Y, Jiang Q, et al. Application of digital surgical techniques of trauma-induced occlusal disorder[J]. Int Dent J, 2025, 75 (S1): 105844. doi: 10.1016/j.identj.2025.105844.

[30] 明华伟, 何芸, 周翊飞, 等. 数字化外科技术辅助下颌骨陈旧性骨折复位重建的临床应用[J]. 中国美容医学, 2020, 29(1): 75-78. doi: 10.15909/j.cnki.cn61-1347/r.003481.
Ming HW, He Y, Zhou YF, et al. The clinical application in the reconstruction of old mandible fracture with digital surgical technique[J]. Chin J Aesthetic Med, 2020, 29(1): 75-78. doi: 10.15909/j.cnki.cn61-1347/r.003481.

[31] Moiduddin K , Mian H S , Elseufy M S , et al. Polyether-ether-ketone (PEEK) and its 3D-printed quantitate assessment in cranial reconstruction [J]. J Funct Biomater,2023,14(8):429. doi: 10.3390/JFB14080429.

[32] Wei X, Zhou W, Tang Z, et al. Magnesium surface-activated 3D printed porous PEEK scaffolds for *in vivo* osseointegration by promoting angiogenesis and osteogenesis[J]. Bioact Mater, 2022, 20: 16-28. doi: 10.1016/j.bioactmat.2022.05.011.

[33] Figueroa-Sanchez JA, Martinez HR, Riaño-Espinoza M, et al. Partial cranial reconstruction using titanium mesh after craniectomy: an antiadhesive and protective barrier with improved aesthetic outcomes[J]. World Neurosurg, 2024, 185: 207-215. doi: 10.1016/j.wneu.2024.02.096.

[34] Xie Y, Li S, Zhang T, et al. Titanium mesh for bone augmentation in oral implantology: current application and progress[J]. Int J Oral Sci, 2020, 12(1): 37. doi: 10.1038/s41368-020-00107-z.

[35] Abu-Ghname A, Banuelos J, Oliver JD, et al. Outcomes and complications of pediatric cranioplasty: a systematic review[J]. Plast Reconstr Surg, 2019, 144(3): 433e-443e. doi: 10.1097/PRS.0000000000005933.

[36] Chang KW, Zhong LM, Lee DS, et al. Outcomes of mesh cranioplasty in scalp-free tissue reconstruction: a systematic review and meta-analysis[J]. Otolaryngol Head Neck Surg, 2023, 168(5): 970-978. doi: 10.1002/ohn.199.

[37] 林晨官璐, 倪杰, 高忆雪. 聚醚醚酮粘接桥修复牙周炎患者切牙缺失的临床研究[J]. 口腔疾病防治, 2024, 32(4): 266-272. doi: 10.12016/j.issn.2096-1456.2024.04.004.
Lin CGL, Ni J, Gao YX. Clinical study of polyetheretherketone resin-bonded bridge for restoring anterior missing teeth in patients with periodontitis[J]. J Prev Treat Stomatol Dis, 2024, 32(4): 266-272. doi: 10.12016/j.issn.2096-1456.2024.04.004.

[38] AlOtaibi N, Naudi K, Conway D, et al. The current state of PEEK implant osseointegration and future perspectives: a systematic review[J]. Eur Cell Mater, 2020, 40: 1-20. doi: 10.22203/eCM.v040a01.

[39] Zheng W, Wu D, Zhang Y, et al. Multifunctional modifications of polyetheretherketone implants for bone repair: a comprehensive review[J]. Biomater Adv, 2023, 154: 213607. doi: 10.1016/j.bioadv.2023.213607.

[40] Muthiah N, Yolcu YU, Alan N, et al. Evolution of polyetheretherketone (PEEK) and titanium interbody devices for spinal procedures: a comprehensive review of the literature[J]. Eur Spine J, 2022, 31(10): 2547-2556. doi: 10.1007/s00586-022-07272-1.

[41] Järvinen S, Suojanen J, Kormi E, et al. The use of patient specific polyetheretherketone implants for reconstruction of maxillofacial deformities[J]. J Craniomaxillofac Surg, 2019, 47(7): 1072-1076. doi: 10.1016/j.jcms.2019.03.018.

[42] Bharti S. Stainless steel versus titanium miniplates in the treatment of mandibular fractures: a comparative study[J]. Cureus, 2025, 17(3): e79912. doi: 10.7759/cureus.79912.

[43] Graillon N, Guyot L, Thollon L, et al. Do mandibular titanium miniplates affect the biomechanical behaviour of the mandible? A preliminary experimental study[J]. J Stomatol Oral Maxillofac Surg, 2022, 123(6): e675-e681. doi: 10.1016/j.jormas.2022.02.007.

[44] Xu G, Zhang X, Wang P, et al. Application of optimized three-dimensional digital surgical guide plates for complex midfacial fractures[J]. Injury, 2022, 53(6): 2005-2015. doi: 10.1016/j.injury.2022.03.014.

[45] Song LM, Wang GX, Wang L. Comparison between CFR-PEEK and titanium plate for proximal humeral fracture: a meta-analysis[J]. Jt Dis Relat Surg, 2024, 35(3): 483-490. doi: 10.52312/jdrs.2024.1611.

（编辑　周春华，刘曙光）

Open Access
This article is licensed under a Creative Commons Attribution 4.0 International License.
Copyright © 2026 by Editorial Department of Journal of Prevention and Treatment for Stomatological Diseases

官网