OPEN ACCESS

[DOI]10.12016/j.issn.2096-1456.202660212

·正畸学专栏 临床研究·

上颌快速扩弓对下颌第一磨牙硬组织局部影响的三维研究

杨洁[1]，　侯向刚[1]，　曹雅妮[1]，　秦佳[1]，　白明海[2]
1.湖南中医药大学口腔医(学)院,湖南 长沙(410208)；　2.长沙市口腔医院口腔正畸科,湖南 长沙(410004)

【摘要】 目的　探讨上颌横向发育不足患者上颌快速扩弓(RME)后下颌第一磨牙矜面最大磨耗深度与牙根表面最大吸收深度变化之间的关联,为正畸临床的风险防范提供依据。**方法**　本研究为回顾性自身对照研究,已获得医院伦理审查委员会批准及患者书面知情同意。本研究按照STROBE指南进行报告。采用回顾性自身前后对照设计,应用三维数字化分析技术,评估RME后患者短期下颌第一磨牙矜面及牙根表面发生的最大病理性变化。根据纳入和排除标准,选取于2023年1月至2025年12月于长沙市口腔医院正畸科采用Hyrax螺旋扩弓器完成RME治疗的55例上颌横向发育不足患者治疗前(T0)与被动保持结束约4个月后(T1)的锥形束CT(CBCT)数据。本研究统一选取患者右侧下颌第一磨牙作为观测牙位,共计55颗牙齿纳入分析。通过三维模型配准技术,测量下颌第一磨牙矜面最大磨耗深度与牙根表面最大吸收深度的变化量作为核心分析指标。采用Wilcoxon符号秩检验、配对t检验比较治疗前后差异;分析变量关系时,采用Pearson相关分析初步评估年龄、性别以及牙根表面最大吸收深度与矜面最大磨耗量的相关性;多元线性回归分析控制混杂因素影响,进一步探讨变量间的预测价值。**结果**　治疗后,下颌第一磨牙矜面最大磨耗深度与治疗前比显著增加:增加量中位数0.349 mm,$P<0.001$;牙根表面最大吸收深度与治疗前比亦显著增加:平均增加(0.453±0.202)mm,$P<0.001$。Pearson相关分析显示,最大磨耗量的对数值与牙根表面最大吸收量呈显著正相关($r=0.343$,$P=0.005$)。多元线性回归分析表明,在控制年龄与性别变量后,矜面最大磨耗量是牙根表面最大吸收量的独立预测因子($\beta=0.342$,$P=0.011$),矜面最大磨耗深度每相对增加10%,牙根表面最大吸收量平均增加约0.037 mm。**结论**　RME治疗引发的异常应力会导致下颌第一磨牙发生局部的病理性矜面磨耗与牙根表面吸收。矜面最大磨耗量是牙根表面最大吸收量的重要独立正向预测因子。对下颌第一磨牙矜面磨耗深度的临床监测可作为预警深层牙根表面吸收风险的有效可视化指标。

【关键词】 快速扩弓；　下颌第一磨牙；　锥形束CT；　三维数字化分析；　3D Slicer；　三维重叠；　磨耗；　牙根表面吸收；　预测模型
【中图分类号】 R78　**【文献标志码】** A　**【文章编号】** 2096-1456(2026)11-1099-10
【引用著录格式】 杨洁,侯向刚,曹雅妮, 等. 上颌快速扩弓对下颌第一磨牙硬组织局部影响的三维研究[J]. 口腔疾病防治, 2026, 34(11): 1099-1108. doi:10.12016/j.issn.2096-1456.202660212.

微信公众号

A three-dimensional study on the local impact of rapid maxillary expansion on hard tissues of mandibular first molars

YANG Jie[1], HOU Xianggang[1], CAO Yani[1], QIN Jia[1], BAI Minghai[2].　1. School of Stomatology, Hunan University of Chinese Medicine, Changsha 410208, China;　2. Department of Orthodontics, Changsha Stomatological Hospital, Changsha 410004, China
Corresponding author: BAI Minghai, Email: 429526876@qq.com

【Abstract】 Objective　To explore the correlation between the maximum occlusal wear depth and the maximum root surface resorption depth of the mandibular first molar after rapid maxillary expansion (RME) in patients with maxillary transverse deficiency, providing a basis for risk prevention in orthodontic clinical practice. **Methods**　This study is a

【收稿日期】2026-06-12；　**【修回日期】**2026-09-04
【基金项目】湖南省卫健委卫生科研课题项目(W20243152)
【作者简介】杨洁,医师,硕士,Email:2459383533@qq.com
【通信作者】白明海,主任医师,博士,Email:429526876@qq.com

retrospective self controlled study that has been approved by the hospital ethics review committee and received written informed consent from patients. This study was reported in accordance with the STROBE guidelines. Using a retrospective self-comparison design and three-dimensional digital analysis technology, the maximum pathological changes on the surface of each patient's mandibular first molar were evaluated shortly after RME treatment. Based on the inclusion and exclusion criteria, cone beam computed tomography (CBCT) data were collected from 55 patients with maxillary transverse deficiency who underwent RME treatment using a Hyrax spiral arch expander in the Orthodontic Department of the Stomatological Hospital, Hunan University of Chinese Medicine from January 2023 to December 2025, pretreatment (T0) and approximately 4 months after the completion of passive retention (T1). This study selected the first mandibular molar on the right side as the uniform observational tooth position, with a total of 55 teeth included in the analysis. Using three-dimensional model registration technology, the changes in the maximum occlusal wear depth and the maximum root surface resorption depth of the mandibular first molars were measured as the primary outcome measures. The Wilcoxon signed-rank test and paired *t*-test were utilized to compare the intra-individual differences before and after treatment. When analyzing the relationship between variables, Pearson correlation analysis was used to preliminarily evaluate the correlation between age, sex, maximum root surface absorption, and maximum occlusal wear. Multiple linear regression analysis was used to control for confounding factors and further explore the predictive value between variables. **Results**　After treatment, the maximum occlusal wear depth of the mandibular first molars increased significantly compared to pretreatment (median increase: 0.349 mm, $P < 0.001$), and the maximum root surface resorption depth also increased significantly compared to pretreatment (mean increase: (0.453±0.202) mm, $P < 0.001$). Pearson correlation analysis revealed a significant positive correlation between the log-transformed maximum occlusal wear and the maximum root surface resorption ($r = 0.343$, $P = 0.005$). Multiple linear regression analysis indicated that after controlling for age and sex, the maximum occlusal wear was an independent predictor of the maximum resorption ($\beta = 0.342$, $P = 0.011$). For every 10% relative increase in the maximum occlusal wear depth, the maximum root surface resorption depth increased by an average of approximately 0.037 mm. **Conclusion**　The abnormal stress induced by RME treatment leads to localized pathological occlusal wear and root surface resorption in mandibular first molars. The maximum occlusal wear is a significant independent positive predictor of the maximum root surface resorption. Clinical monitoring of the occlusal wear depth can serve as an effective visual indicator for predicting the risk of deep root surface resorption.

【Key words】 rapid maxillary expansion; mandibular first molar; cone beam computed tomography; three-dimensional digital analysis; 3D Slicer; three-dimensional superimposition; occlusal wear; root surface resorption; predictive model

J Prev Treat Stomatol Dis, 2026, 34(11): 1099-1108.

上颌快速扩弓(rapid maxillary expansion,RME)是正畸临床中常用于纠正青少年上颌横向发育不足的有效方法之一[1]。然而,RME不仅作用于上颌,还会显著改变咬合关系[2-3],导致上下颌牙齿间的接触模式发生瞬时及长期的改变[4]。这种咬合失调会引发异常的咬合应力集中。研究证实,长时间的异常应力会增加牙冠接触面进行性的磨耗甚至缺损[5],也被认为是诱发牙根外吸收的重要力学因素之一[6]。随着由咬合失调引起的牙体组织适应性或病理性组织损伤逐渐受到关注,明确其发生规律对于正畸治疗的安全监控具有重要意义。既往对这种微小硬组织损伤的评估仍存在明显的方法学不足。多依赖于传统二维影像投影,受限于结构重叠和标志点定位不准等问题,无法实现空间上的精准量化,导致RME治疗引起的下颌牙体硬组织动态关联变化问题一直未得到有效解决。近年来,锥形束CT(cone beam CT,CBCT)结合数字化三维配准技术的出现弥补了这一短板,实现三维方向上的精准量化分析[3],目前常用于牙根表面吸收的定量研究中[7-8]。特别是基于开源平台3D Slicer[9-10],已广泛应用于医学领域的三维测量分析[11-12],与逆向工程软件Geomagic的联合应用,能够实现1∶1无重叠的三维结构还原与微米级形态学偏差计算[13]。然而,目前尚缺乏RME治疗下,下颌牙体硬组织的变化趋势相关性研究。

本研究采用三维数字化分析技术测量RME治疗前后下颌第一磨牙牙体硬组织形态学改变,并探讨下颌第一磨牙矜面最大磨耗深度与牙根表面

最大吸收深度的相关性，以期为正畸临床的风险防范提供新的方法学验证与循证医学支持。

1　资料和方法

1.1　研究对象

本研究为回顾性自身对照研究，已通过长沙市口腔医院医学伦理审查委员会审批（No. 2025-085），所有患者及其法定监护人均已签署知情同意书。本研究按照Strengthening the Reporting of Observational Studies in Epidemiology（STROBE）指南[14]进行报告。

本研究选取2023年1月至2025年12月于长沙市口腔医院正畸科采用Hyrax螺旋扩弓器完成RME治疗的上颌横向发育不足患者。基于G*Power 3.1软件进行样本量估算，设定中等效应量（d = 0.5）、检验水准（α = 0.05）及统计效能（1—β = 0.8），计算得出所需最小样本量为34例。纳入标准：①年龄10~15岁的青少年患者；②符合上颌RME治疗适应证；③均佩戴带环式Hyrax螺旋扩弓器；④下颌第一磨牙完全萌出者；⑤在扩弓治疗前后均拍摄了CBCT影像的患者；⑥依从性好的患者，扩弓器连续每天早晚各加力1次，每次转动1/4圈，主动扩弓至少2周，被动保持3个月。排除标准：①分辨率低、软硬组织界限不清、存在伪影等CBCT不合格情况；②扩弓治疗前存在牙根吸收者；③观测牙龋坏、缺损、缺失，存在修复治疗、牙髓治疗或牙外伤史；④治疗期间有中断治疗或未拍摄影像学资料者；⑤颌骨内存在骨岛、牙骨质瘤、根尖囊肿等影响观测牙移动；⑥有正畸治疗史（含正在接受治疗者）。最终严格纳入符合纳排标准的55例患者，其中男性26例，女性29例，年龄10~15岁（中位数12岁）。纳入患者的诊疗工作均由同一名具有10年以上临床经验的正畸专科主任医师完成。既往研究证实偏侧咀嚼导致下颌运动轨迹不对称，会导致左右两侧承受咬合力不均[15]，为消除双侧不对称咀嚼习惯的潜在干扰，同时避免同源数据聚集效应的影响[16]，本研究统一选取患者右侧下颌第一磨牙作为观测牙位，共计55颗牙齿纳入分析，患者平均主动扩弓加力周期为（14.5±2.3）d，被动保持期平均持续（3.7±0.4）个月。

1.2　测量设备

CBCT（KaVo 3D Exam Vision，德国）；3D-Slicer 5.9.0三维重建软件；Geomagic Studio 2014三维模型处理软件；Geomagic Control X 2020.1三维重叠软件。

1.3　研究方法

1.3.1　矫治过程　治疗前，所有患者均采集初始CBCT影像资料，结合牙根发育阶段，全身生长发育情况及腭中缝融合状态[17-18]，确认符合RME治疗的适应证。具体临床操作与管理流程如下：①初戴与加力阶段：为患者粘固上颌Hyrax螺旋扩弓器，指导其每日早晚各旋转螺旋孔1/4圈。考虑到部分患者可能出现加力疼痛等个体反应，可在症状明显时暂停加力2~3 d，随后继续完成加力周期。主动加力阶段持续2周，其间若扩弓器发生松脱，患者需及时复诊重新粘接。②复诊评估与保持阶段：加力2周后患者首次复诊，检查扩弓器稳定性、螺旋打开程度及上颌中切牙间间隙。治疗目标为达到上颌磨牙舌尖与下颌磨牙颊尖咬合接触[19]，或达到预期宽度后再扩2 ~ 3mm[20-21]（图1），预期宽度指上下颌磨牙达到正常咬合关系，即上颌磨牙舌尖刚好咬在下颌磨牙中央窝中。此时停止主动加力，转入被动保持阶段，持续约3~4个月。保持期结束后拆除扩弓器，并拍摄治疗后CBCT影像资料。

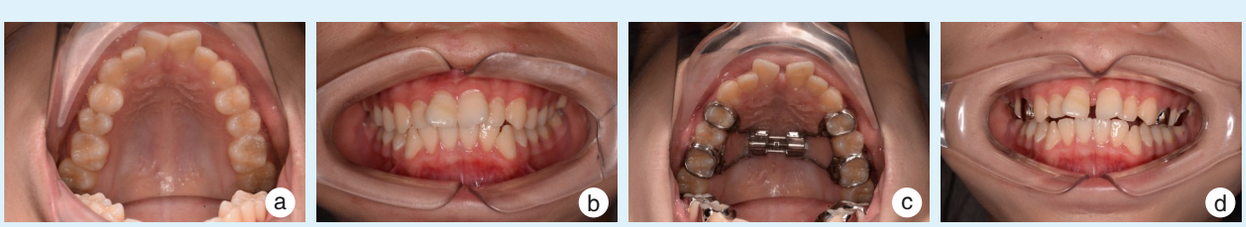

a-b: pre-RME treatment, in which the maxillary dentition presented with transverse deficiency and constriction; c-d: clinical stage post-RME, performed using a banded Hyrax expander, transitioning into the passive retention phase. RME: rapid maxillary expansion

Figure 1　Intraoral photographs of the rapid maxillary expansion process in an adolescent patient

图1　青少年患者上颌快速扩弓过程口内照

1.3.2　数据采集及偏倚控制　本研究提取了两个观测节点的CBCT影像数据，分别为上颌RME治疗前（T0）与被动保持阶段结束、拆除扩弓器时（T1）。所有纳入病例的CBCT数据由同一操作者导入3D-Slicer软件，经三维重建后以STL格式导出（图2），随后导入Geomagic Studio软件中进行模型处理（光滑、降噪）。所有影像数据均来源于同一设备，扫描参数与坐标系保持一致，处理过程中使用相同的操作参数以控制变量。为评估操作者及配准算法可能引入的随机误差，本研究随机抽取20%的样本进行重复性验证。具体流程为：间隔1周后，由同一研究者重新对同一DICOM格式的原始数据进行三维重建与模型重叠操作。原始数据经质量控制审查合格后[22]，以医学数字影像与通讯格式（digital imaging and communications in medicine，DICOM）存档并导入本研究。在Geomagic Studio软件中，模型经初步对齐后，采用迭代最近点算法（iterative closest point，ICP）进行最佳拟合配准[23-24]。两次重叠结果对应点云的均方根误差（root-mean-square error，RMS）为0.03 ± 0.01 mm，表明三维重建与重叠处理过程具有良好的一致性与可重复性[25]。组内相关系数和三维测量数据稳定性（ICC）均大于0.85。

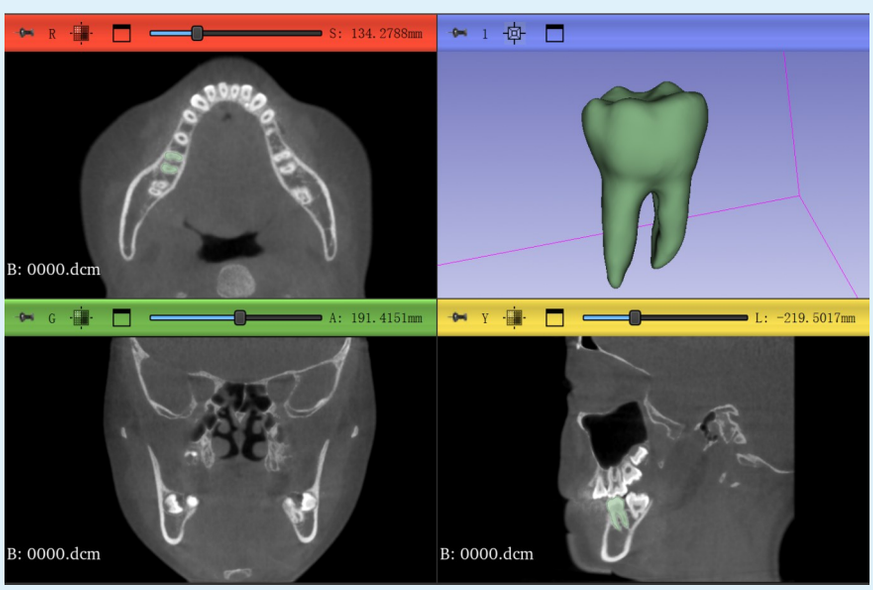

A high-definition, three-dimensional reconstruction scenario for extracting an individual target tooth based on pre-RME cone beam computed tomography scans. The top-left, bottom-left, and bottom-right windows represent the axial, coronal, and sagittal views of the image, respectively; the top-right window displays the high-resolution three-dimensional solid model of the individually extracted right mandibular first molar (green area), which features a smooth surface and clearly reproduces the anatomical morphology of the crown and root surfaces. RME: rapid maxillary expansion. Figures were generated by 3D Slicer(5.9.0) software

Figure 2　Three-dimensional reconstruction scenario of cone beam computed tomography images of the target mandibular first molar

图2　目标下颌第一磨牙锥形束CT影像的三维重建场景

1.4　观察指标

首先将在Geomagic Studio软件中处理好的治疗前后（T0、T1）三维模型，选取釉牙骨质界（cemento-enamel junction，CEJ）以上全冠部分为参考基准初步对齐，设置30%网络重叠度，执行ICP功能，可以确保三维模型匹配的精准性与金标准高度一致[26-27]（图3），最后将重叠模型以STL格式导入Geomagic Control X软件生成偏差色谱图模型选取下颌第一磨牙𬌗面和牙根表面偏差最大位点获取𬌗面最大磨耗量、牙根表面最大吸收量（图4）。

1.5　统计学分析

使用SPSS27.0软件进行统计学分析。患者年龄、治疗时间等基线资料符合正态分布以均数±标准差（$\bar{x}\pm s$）表示，不服从正态分布数据用中位数及四分位数间距[$M(Q1,Q3)$]进行描述，计数资料以频数及构成比[n（%）]表示。正态性经Shapiro-Wilk检验，𬌗面最大磨耗量的治疗前后差值为非正态分布，采用Wilcoxon符号秩检验比较治疗前后

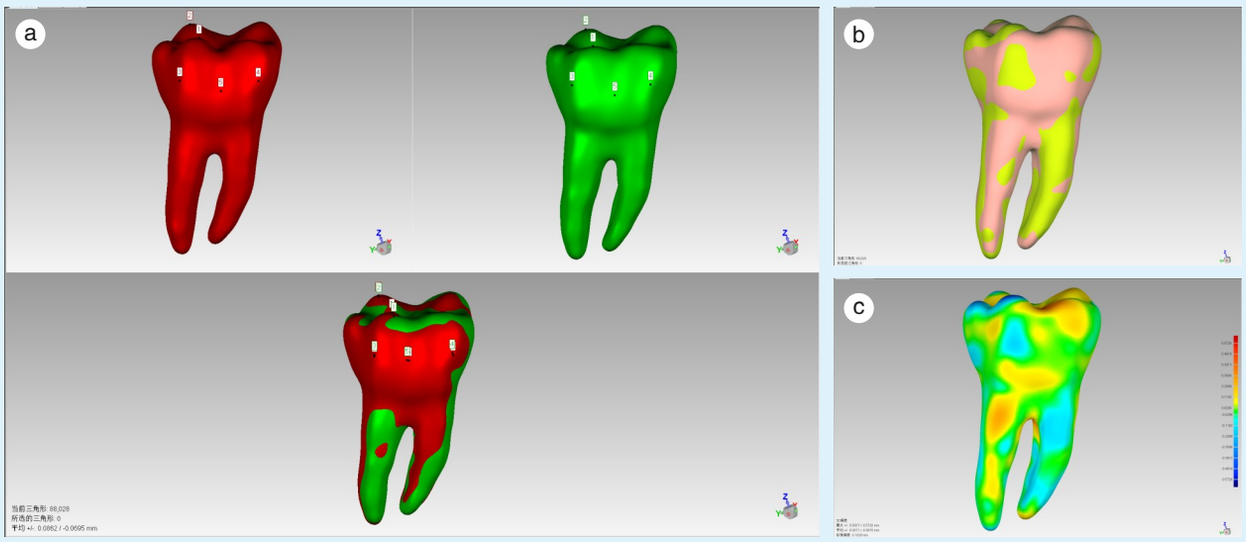

The methodological steps for three-dimensional digital model superimposition and registration. a: using the entire crown portion above the cemento-enamel junction as a reference base, initial N-point alignment was performed using feature points between the pre-treatment (T0, red model) and post-treatment (T1, green model) models; b: the ICP algorithm was applied to achieve precise best-fit superimposition of the models; c: a preliminary three-dimensional color-coded deviation map was generated following ICP superimposition and used to quantify morphological changes on the tooth surface. ICP: iterative closest point. Figures were generated by Geomagic Studio(2014) software

Figure 3　Best-fit registration of three-dimensional models of the mandibular first molar before and after treatment

图3　治疗前后下颌第一磨牙三维模型的最佳拟合配准

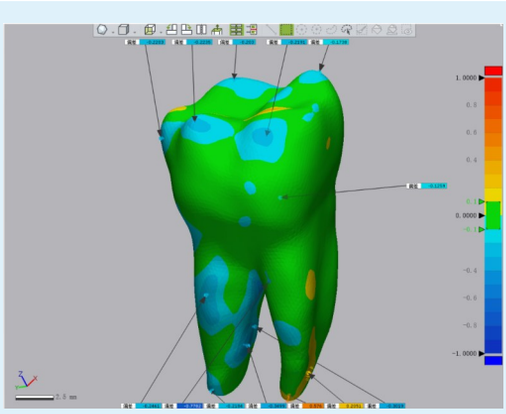

Visual quantification of the three-dimensional spatial displacement deviations on the surface of a target tooth before (T0) and after (T1) treatment. The unit of the scale on the right is mm. The three-dimensional pseudo-color mapping mechanism is defined as follows: warm-colored areas (red/orange) represent regions of positive surface changes (growth or deposition); cold-colored areas (blue/cyan) represent regions of resorptive changes; and green areas indicate regions where the anatomical morphology remains stable with zero deviation before and after treatment. Figures were generated by Geomagic Control X(2020.1) software

Figure 4　Three-dimensional color-coded deviation map of hard tissues in the mandibular first molar before and after rapid maxillary expansion treatment

图4　上颌快速扩弓治疗前后下颌第一磨牙硬组织的三维偏差色谱图

差异。牙根表面最大吸收深度的治疗前后差值符合正态分布，采用配对t检验，比较治疗前后差异。将𬌗面最大磨耗量进行对数转换（log𬌗面最大磨耗量）后，符合正态分布，分析变量关系时，采用Pearson相关分析初步评估年龄、性别以及牙根表面最大吸收与𬌗面最大磨耗量的相关性，多元线性回归分析控制混杂因素影响，进一步探讨变量间的预测价值。$P<0.05$为差异具有统计学意义。

2　结　果

2.1　RME治疗前后下颌第一磨牙𬌗面最大磨耗深度、牙根表面最大吸收深度的变化

①𬌗面最大磨耗深度：治疗前后差值不符合正态分布，单样本Wilcoxon符号秩检验显示，治疗后磨耗深度显著增加，增加量中位数为0.349 mm，$P<0.001$。病例示例见图5。②牙根表面最大吸收深度：治疗前后差值符合正态分布，单样本t检验显示，治疗后吸收深度显著增加，平均增加（0.453±0.202）mm，95% *CI*：0.398-0.508mm，$P<0.001$。RME治疗导致了下颌第一磨牙发生了磨耗和牙根表面吸收，均达到了统计学上的显著增加。其中，牙根表面吸收的增加不仅具有统计学意义，且效应量极大。见表1。

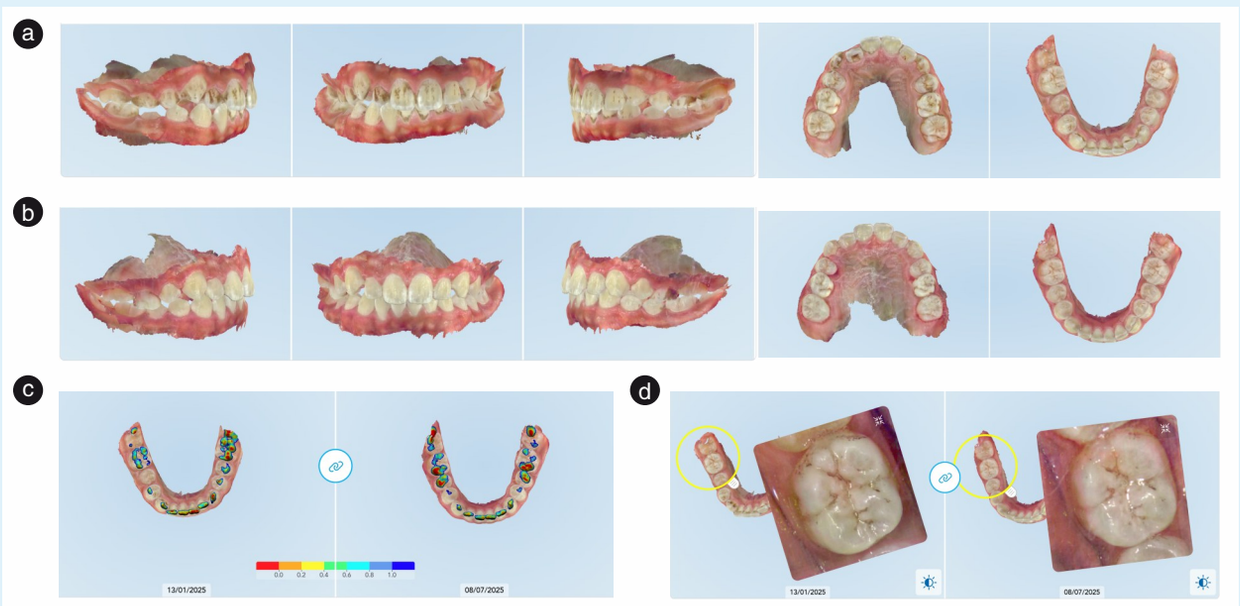

Comparison of intraoral photographs before (T0) and after (T1) treatment, highlighting the adaptive changes in the mandibular dentition, the shifts in occlusal contact distribution, and the detailed occlusal surface alterations of the mandibular first molars following RME treatment. a: intraoral photograph before expansion treatment (T0), showing mild crowding in the mandibular dentition and a slight lingual inclination of the posterior teeth; b: intraoral photograph after the completion of passive retention (T1), demonstrating that the crowding of the mandibular dentition is alleviated and the lingual inclination of the posterior teeth is reduced following RME. c: comparison of the changes in the distribution of occlusal contact points before and after RME treatment (red indicates the tightest areas of contact, while blue indicates areas with general contact); figure wase generated by Geomagic Control X(2020.1) software; d: detailed morphological changes on the occlusal surfaces of the mandibular first molars before and after treatment. Notably, the mesiobuccal cusp exhibits the most severe wear, which precisely corresponds to the tightest occlusal contact point (red area) shown in Figure c, indicating a pronounced localized occlusal stress concentration. RME: rapid maxillary expansion

Figure 5　Intraoral photographs and detailed views of occlusal surface changes in the mandibular first molar before and after rapid maxillary expansion treatment

图5　上颌快速扩弓治疗前后口内照及下颌第一磨牙𬌗面变化细节图

表1　上颌快速扩弓治疗前后下颌第一磨牙𬌗面最大磨耗深度、牙根表面最大吸收深度的变化

Table 1　Changes in the maximum wear depth and maximum root surface resorption depth of mandibular first molars before and after rapid maxillary expansion treatment

Difference before and after treatment / mm		*Z*/*t*	*P*	Cohen's d
Maximum wear depth (*M* [*Q*1, *Q*3])	0.349 (0.268, 0.447)	Z = 6.452	<0.001	-
Maximum root surface resorption depth ($\bar{x}$±s)	0.453 ± 0.202	*t* = 16.630	<0.001	2.242, 95% *CI*: 1.741-2.737

The change in maximum wear depth was analyzed using the one-sample Wilcoxon signed-rank test (*Z*-value); the change in maximum root surface resorption depth was analyzed using the paired *t*-test (*t*-value). Sample size n = 55. *CI*: confidence interval

2.2　下颌第一磨牙𬌗面磨耗与牙根表面吸收的相关性分析

Pearson相关分析结果显示，RME治疗后下颌第一磨牙𬌗面log最大磨耗量（对数转换值）与牙根表面最大吸收量呈显著正相关（r = 0.343，P = 0.005），提示二者存在中等程度的关联。年龄和性别分别与𬌗面最大磨耗量（r = −0.022，P = 0.435；r = −0.120，P = 0.191）和牙根表面最大吸收量（r = −0.077，P = 0.286；r = 0.031，P = 0.414）均无统计学显著相关性。见表2。

进一步采用多元线性回归分析，在控制年龄与性别变量后，𬌗面最大磨耗量仍对牙根表面最大吸收量具有独立的显著正向预测作用。结果显示：log𬌗面最大磨耗量的回归系数B = 0.384（95%*CI*：0.094-0.675），标准化系数β = 0.342，转换为原始测量值后结果表明：𬌗面最大磨耗量深度每相对增加10%，牙根表面最大吸收量平均绝对增加约0.037 mm（95% *CI*：0.009-0.064 mm，P =

表2　主要变量的Pearson相关系数矩阵

Table 2　Pearson correlation coefficients, matrix of key variables

Variable		Log maximum occlusal wear	Age	Sex
Maximum occlusal wear (mm, $\bar{x} \pm s$)	0.38 ± 0.16*	1		
Age (years, $\bar{x} \pm s$)	12.16 ± 1.38	r = −0.022 (P = 0.435)	1	
Sex (n [%])		r = −0.120 (P = 0.191)	r = −0.232 (P = 0.044)	1
Male	26 (47.3)			
Female	29 (52.7)			
Root surface resorption (mm, $\bar{x} \pm s$)	0.45 ± 0.20	r = 0.343 (P = 0.005)	r = −0.077 (P = 0.286)	r = 0.031 (P = 0.414)

Pearson correlation analysis was performed. *This value is the original measured value back-transformed from the logarithmically converted data. The sample consisted of 55 participants (26 male and 29 female) ranging in age from 10 to 15 years old, including 6 patients aged 10, 13 aged 11, 15 aged 12, 12 aged 13, 5 aged 14, and 4 aged 15

0.011)；年龄和性别的回归系数分别为B = −0.032（P = 0.106）和B = 0.014（P = 0.791），均未达到统计学显著性。模型整体具有统计学意义（F = 3.454，P<0.05），调整后R^2 = 0.120，各变量方差膨胀因子（VIF）均接近1，表明模型无多重共线性问题。见表3。

表3　下颌第一磨牙矜面最大磨耗量与牙根表面吸收关联性的多元线性回归模型分析

Table 3　Multivariate linear regression model analysis of the correlation between maximum occlusal wear of mandibular first molars and root surface absorption

Variable	B	95% CI	β	P	VIF
Constant	0.990	(0.452 – 1.529)		<0.001	
Wear (log wear)	0.384	(0.094 – 0.675)	0.342	0.011	1.017
Age	−0.032	(−0.070 – 0.007)	−0.216	0.106	1.060
Sex (male)	0.014	(−0.092 – 0.121)	0.035	0.791	1.075

B: unstandardized coefficient; β: standardized coefficient; CI: confidence interval; VIF: variance inflation factor. The dependent variable is the maximum root surface resorption, and the reference group for sex is female. The unit for both maximum wear and maximum root surface resorption is mm. All VIF values are close to 1, indicating the absence of multicollinearity

3　讨　论

本回顾性观察研究旨在探讨RME干预后对下颌牙列产生的继发性硬组织变化。本研究的创新之处在于，首次在RME治疗背景下，发现下颌第一磨牙发生了矜面磨耗与牙根表面吸收，运用高质量三维分析软件系统且精准地量化其变化，也证实了二者存在正相关关系，并建立了预测模型，初步勾勒了“扩弓–咬合紊乱–应力异常–矜面磨耗–牙根表面吸收”的潜在病理关联。正如前言所述，既往同类研究受限于二维影像重叠及三维重建软件运用等因素，难以在三维维度精确捕捉空间细微差异，这也是本研究着力解决的核心问题。

RME治疗主要通过作用于双侧支抗牙，经螺旋加力装置使腭中缝呈“前宽后窄”的楔形打开，此过程常伴随支抗牙的颊向倾斜[28-29]。矫治力传递至牙齿，可引发牙骨质、牙周膜及牙槽骨发生相应的生物学改建[30-31]。尽管RME治疗直接作用于上颌，但下颌亦会随之发生适应性改变[32-33]，主要源于上颌宽度增加后，颊肌对下颌的约束减弱、咬合关系外移，进而引发下颌后牙的功能性颊倾与牙槽骨改建[4]。临床中，接受RME治疗的患者多为9~15岁青少年。本研究纳入第一前磨牙、第二前磨牙及第一磨牙完全萌出、可佩戴Hyrax扩弓器的患者，通过对比治疗前后CBCT三维重叠模型，测量下颌第一磨牙矜面磨耗及牙根表面吸收情况。研究发现，在主动扩弓开始至被动保持结束平均4.12个月内，RME治疗后的下颌第一磨牙均发生了具有统计学显著性的最大磨耗和牙根表面最大吸收的增加。更重要的是，多元线性回归分析明确了最大磨耗量对牙根表面最大吸收量具有独立且显著的正向预测作用。尽管本研究作为观察性研究，在方法学上无法直接确立机械应力异常与牙根表面之间的绝对因果关系，但本研究所证实的最大磨耗量与吸收量之间的显著正相关性，与经典生物力学推演高度契合，分析其可能的原因为RME干预通过增宽上颌牙弓打乱了原有的正常咬合平衡，随着上颌磨牙的向外扩展，下颌磨牙往往被动承受咬合外移带来的异常应力集中、早接触或干扰，这种不均衡的受力状态直接导致矜面进行性磨耗加剧[34-35]。同时，异常咬合力经牙周膜传递至牙根表面，可能干扰牙骨质与牙槽骨表面成骨/破骨细胞活动的生理平衡，使破骨活动相对增强，从而激活或加速牙根表面吸收[36]。据

此推测，“上颌扩弓→下颌咬合外移/紊乱→L6咬合应力异常→磨耗加剧→牙根表面吸收”构成了一条具有高度临床合理性的潜在病理链。这一发现不仅为咬合创伤导致牙根表面吸收的理论提供了新的真实测量数据量化佐证，更从循证医学角度，将𬌗面形态学牙体硬组织的丧失确立为一项可用于提示牙根表面病理性吸收风险的直观临床指标。

此外，三维数字化技术的应用进一步支撑了本研究的方法学创新。3D Slicer软件作为处理三维影像的重要工具[37-38]。该软件支持CT、MRI、超声等多种影像数据的处理与分析，具有图像分割、配准、体积测量及术中导航等功能，在影像处理精度方面优势显著[39-40]。生成的高质量三维模型可为临床诊疗与手术规划提供支持，还可通过插件满足不同专业需求。目前3D Slicer在神经外科、骨科等领域应用广泛，但在口腔领域应用较少，主要集中在正颌外科的取骨设计、颌面缺损修复[41]与正畸牙齿移动评估[12]。本研究运用了3D Slicer对牙齿进行三维重建，提取单颗牙模型，并通过Geomagic软件对治疗前后模型进行配准与重叠，生成偏差色谱图，自动计算模型表面数千对应点的距离，量化牙体表面变化，减少人为测量误差[42]，结合三维影像技术与人工智能（artificial intelligence，AI）实现半自动化分析，提升测量的可重复性与一致性，极大地削弱了主观识别误差，这种技术手段确保了数据的科学性与精确度。

本研究尚存在一定的局限性。首先，在临床实际操作中，本研究纳入研究对象基本处于恒牙列，RME治疗结束后即转入下一阶段正畸治疗，且受限于放射卫生伦理原则，患者在被动保持结束后的半年或一年内，若无明确的其他正畸指征，并不常规拍摄CBCT进行复查。因此，本研究未能获取更长期的三维量化观测节点数据。未来需要通过前瞻性研究设计，在严格遵循伦理规范的前提下，进一步追踪咬合创伤及适应性变化是否会随时间推移而减轻。其次，不同患者的牙弓扩展程度可能对下颌磨牙的咬合负荷分布产生不同程度的生物力学影响，年龄及咬合力大小也可能会发生不同程度磨耗，受限于临床研究及样本量，本研究未能纳入更多年龄段的样本、对咬合力大小划分，以及扩弓量的大小对𬌗面磨耗与牙根表面吸收情况进行更细致的分层分析。这也是下一阶段深入探讨的重要研究方向。

综上所述，本研究不仅量化证实了RME治疗引起的下颌第一磨牙𬌗面磨耗与牙根表面吸收且二者存在正相关关系，更为咬合创伤导致牙周及牙体硬组织改变的经典理论提供了坚实的三维量化佐证，并建立了预测模型，初步勾勒了“扩弓-咬合紊乱-应力异常-磨耗-吸收”的潜在病理关联。对于临床的指导意义在于：在其他临床症状（如牙齿敏感、咬合疼痛、松动等）尚不明显，但观察到牙体𬌗面局部病理性磨耗加重这一可视化表征时，需高度警惕并发牙根表面吸收的风险，及时进行CBCT等三维辅助检查并采取相应的干预与防控措施。

【Author contributions】 Yang J designed the study, performed image modeling analysis, and wrote the article. Hou XG performed statistical data analysis. Cao YN collected imaging data. Qin J reviewed the relevant literature. Bai MH conceptualized and reviewed the article. All authors read and approved the final manuscript as submitted.

【Ethics statement】 The study adhered to the tenets of the Declaration of Helsinki and was approved by the Ethics Committee of (No. 2025-085), and written informed consent was obtained from all participants.

【Funding】 This study was supported by the grants from Health Science Research Project of Hunan Provincial Health Commission (No. W20243152). The funder had no role in the study design, data collection and analysis, decision to publish, or preparation of the manuscript.

【Competing interests】 All authors have completed the ICMJE uniform disclosure form at www.icmje.org/disclosure-of-interest/ and declare: support from the Health Science Research Project of Hunan Provincial Health Commission (No. W20243152) for the submitted work; no financial relationships with any organisations that might have an interest in the submitted work in the previous three years; no other relationships or activities that could appear to have influenced the submitted work.

【Data availability statement】 The original contributions presented in this study are included in the article. Further inquiries can be directed to the corresponding author upon reasonable request.

【Generative AI statement】 The manuscript did not use generative AI software during the creative process, but DeepSeek was used for text polishing. The authors reviewed and edited the output and take full responsibility for the manuscript.

参考文献

[1] Pan Y, Peng W, Wang Y. Comparison of the effects of different palatal morphology on maxillary expansion *via* RME and MSE: a finite element analysis[J]. Clin Exp Dent Res, 2024, 10(5): e70005. doi: 10.1002/cre2.70005.

[2] Serafin M, Fastuca R, Zecca PA, et al. 3D occlusal changes of upper first molars after rapid maxillary expansion on permanent versus deciduous teeth: a retrospective multicenter CBCT study[J]. Prog Orthod, 2023, 24(1): 24. doi: 10.1186/s40510-023-00476-1.

[3] Laganà G, Paoloni V, Pavoni C, et al. Tridimensional changes in

mandibular arch after rapid maxillary expansion therapy: a clinical study[J]. Children, 2023, 10(5): 775. doi: 10.3390/children10050775.

[4] Ugolini A, Abate A, Donelli M, et al. Spontaneous mandibular dentoalveolar changes after rapid maxillary expansion (RME), slow maxillary expansion (SME), and leaf expander-a systematic review [J]. Children, 2024, 11(4): 501. doi: 10.3390/children11040501.

[5] Rausch H, Marreiros J, Kullmer O, et al. An experimental approach on dynamic occlusal fingerprint analysis to simulate use-wear localisation and development on stone tools[J]. Sci Rep, 2024, 14(1): 20084. doi: 10.1038/s41598-024-70265-1.

[6] Zhao Z, Chen L, Zhu S, et al. Periodontal ligament stem cells in tissue remodeling: from mechanical forces to inflammatory signals [J]. Stem Cell Res Ther, 2025, 16(1): 653. doi: 10.1186/s13287-025-04777-6.

[7] Gandhi V, Mehta S, Gauthier M, et al. Comparison of external apical root resorption with clear aligners and pre-adjusted edgewise appliances in non-extraction cases: a systematic review and meta-analysis[J]. Eur J Orthod, 2021, 43(1): 15-24. doi: 10.1093/ejo/cjaa013.

[8] Prasanna Arvind TR, Ramasamy N, Subramanian AK, et al. Three-dimensional volumetric evaluation of root resorption in maxillary anteriors following en-masse retraction with varying force vectors – a randomized control trial[J]. Orthod Craniofacial Res, 2024, 27 (2): 211-219. doi: 10.1111/ocr.12704.

[9] Cheng H, Huang Y, Pan Y, et al. Three-dimensional analysis of maxillary incisor root resorption associated with three distinct anterior retraction protocols: a retrospective study[J]. Int J Dent, 2026, 2026: 5583614. doi: 10.1155/ijod/5583614.

[10] Baraka M, El-Kateb N, Gamal M, et al. Assessment of volumetric changes after regenerative endodontic procedures using semiautomated and 3D U-NET automated CBCT segmentation: a retrospective cohort study[J]. BMC Oral Health, 2025, 25(1): 1409. doi: 10.1186/s12903-025-06826-1.

[11] Vilanova L, Castillo AA, Bellini-Pereira SA, et al. Three-dimensional changes after maxillary molar distalization with a miniscrew-anchored cantilever[J]. Angle Orthod, 2023, 93(5): 513-523. doi: 10.2319/091222-640.1.

[12] Eason M, Tai SK, Loh CT, et al. Three-dimensional assessment of tooth movements in clear aligner treatment of moderate and severe crowding[J]. Clin Oral Investig, 2025, 30(1): 6. doi: 10.1007/s00784-025-06657-y.

[13] Gerbino G, Autorino U, Giaccone E, et al. Virtual planning and CAD/CAM-assisted distraction for maxillary hypoplasia in cleft lip and palate patients: accuracy evaluation and clinical outcome[J]. J Craniomaxillofac Surg, 2021, 49(9): 799-808. doi: 10.1016/j.jcms.2021.03.004.

[14] von Elm E, Altman DG, Egger M, et al. The Strengthening the Reporting of Observational Studies in Epidemiology (STROBE) statement: guidelines for reporting observational studies[J]. Lancet, 2007, 370(9596): 1453-1457. doi: 10.1016/S0140-6736(07)61602-X.

[15] Cardoso-Silva L, Gomes BC, de Faria Melo RP, et al. Unilateral molar Incisor hypomineralization influences the chewing side? An observational study in children[J]. Clin Oral Investig, 2024, 28 (12): 634. doi: 10.1007/s00784-024-06037-y.

[16] Fleming PS, Koletsi D, Polychronopoulou A, et al. Are clustering effects accounted for in statistical analysis in leading dental specialty journals?[J]. J Dent, 2013, 41(3): 265-270. doi: 10.1016/j.jdent.2012.11.012.

[17] Proffit WR, Fields HW Jr, Larson BE, et al. Contemporary Orthodontics [M]. 6th ed. Philadelphia, Pa.: Elsevier, 2019.

[18] Ferrillo M, Daly K, Pandis N, et al. The effect of vertical skeletal proportions, skeletal maturation, and age on midpalatal suture maturation: a CBCT-based study[J]. Prog Orthod, 2024, 25(1): 4. doi: 10.1186/s40510-023-00504-0.

[19] Meltem Aslan Ozturk E, Muftuoglu O. Evaluation of bony changes observed in mid-palatal suture after rapid maxillary expansion using fractal analysis[J]. J Stomatol, 2024, 77(3): 186-190. doi: 10.5114/jos.2024.143588.

[20] Beltrami F, Kiliaridis S, Antonarakis GS. Long-term stability of posterior crossbite correction, treated in the mixed or permanent dentition of growing children: a systematic review and meta-analysis[J]. Orthod Craniofac Res, 2024, 27(1): 1-14. doi: 10.1111/ocr.12690.

[21] Aleesh MM, Rajeh NA, Aleesh AM. Evaluating the impact of various predictors on rapid maxillary expansion (RME) success[J]. Clin Oral Investig, 2025, 29(6): 325. doi: 10.1007/s00784-025-06401-6.

[22] 国家卫生健康委员会. WS 818—2023 锥形束X射线计算机体层成像(CBCT)设备质量控制检测标准[S]. 北京: 中国标准出版社, 2023.
National Health Commission. WS 818—2023 Standard for testing of quality control in X-ray cone beam computed tomography equipment[S]. Beijing: Standards Press of China, 2023.

[23] Yang Q, Cai M, Hao S, et al. Accuracy and reliability of a three-dimensional superimposition method for maxillary jaws and dentition[J]. BMC Oral Health, 2025, 25(1): 1281. doi: 10.1186/s12903-025-06637-4.

[24] Trpčić M, Perišić MM, Lukačević F, et al. Accuracy analysis of extraoral 3D scanning in dental prosthetic[J]. Acta Stomatol Croat, 2023, 57(4): 339-352. doi: 10.15644/asc57/4/5.

[25] Thomas TP, Anderson DD, Willis AR, et al. A computational/experimental platform for investigating three-dimensional puzzle solving of comminuted articular fractures[J]. Comput Methods Biomech Biomed Engin, 2011, 14(3): 263-270. doi: 10.1080/10255841003762042.

[26] Park J, Choi DS, Jang I, et al. A novel method for volumetric assessment of tooth wear using three-dimensional reverse-engineering technology: a preliminary report[J]. Angle Orthod, 2014, 84(4): 687-692. doi: 10.2319/081113-592.1.

[27] Gkantidis N, Dritsas K, Katsaros C, et al. 3D method for occlusal tooth wear assessment in presence of substantial changes on other tooth surfaces[J]. J Clin Med, 2020, 9(12): 3937. doi: 10.3390/jcm9123937.

[28] Mehta S, Arqub SA, Vishwanath M, et al. Biomechanics of conven-

tional and miniscrew-assisted rapid palatal expansion[J]. J World Fed Orthod, 2024, 13(3): 105-112. doi: 10.1016/j.ejwf.2024.03.002.

[29] Ning R, Chen J, Liu S, et al. Treatment effects after maxillary expansion using tooth-borne *vs* tissue-borne miniscrew-assisted rapid palatal expansion appliance[J]. Am J Orthod Dentofacial Orthop, 2023, 164(4): 545-553. doi: 10.1016/j.ajodo.2023.02.022.

[30] Li Y, Zhan Q, Bao M, et al. Biomechanical and biological responses of periodontium in orthodontic tooth movement: up-date in a new decade[J]. Int J Oral Sci, 2021, 13(1): 20. doi: 10.1038/s41368-021-00125-5.

[31] Yu QY, Huang YP, Li WR. Extracellular matrix remodelling of the periodontium under orthodontic force[J]. Chin J Dent Res, 2024, 27(2): 121-131. doi: 10.3290/j.cjdr.b5459583.

[32] Kotarska M, Kucukkeles N, Lis J, et al. Changes in the mandible following rapid maxillary expansion in children with class II malocclusion: a systematic review[J]. Diagnostics, 2022, 12(7): 1688. doi: 10.3390/diagnostics12071688.

[33] Jiang R, Chen J, Zheng W, et al. A comparative study of mandibular changes induced by rapid maxillary expansion *vs* sagittal-guided Twin-block therapy during the mixed dentition period[J]. Am J Orthod Dentofacial Orthop, 2026. doi: 10.1016/j.ajodo.2026.06.018.

[34] Sricharat P, Nalamliang N, Jearanaiphaisarn T. Occlusal and behavioral factors associated with vertical root fractures in endodontically treated teeth: a retrospective matched case-control study[J]. J Dent, 2026, 167: 106553. doi: 10.1016/j.jdent.2026.106553.

[35] Zhang G, Zeng F, Wang M, et al. Association between unilateral third molar elongation, temporomandibular joint space asymmetry, and posterior tooth wear: a CBCT study[J]. BMC Oral Health, 2026, 26(1): 1179. doi: 10.1186/s12903-026-08560-8.

[36] Shen F, Xia X, Han Y, et al. From force to resorption: mechanotransduction, osteoclasts, prevention[J]. Prog Orthod, 2026, 27(1): 27. doi: 10.1186/s40510-026-00625-2.

[37] Shi H, Li Y, Wang Y, et al. The preoperative evaluation value of 3D-slicer program before microsurgical vascular decompression in patients with hemifacial spasm[J]. Clin Neurol Neurosurg, 2022, 217: 107241. doi: 10.1016/j.clineuro.2022.107241.

[38] Dot G, Chaurasia A, Dubois G, et al. DentalSegmentator: robust open source deep learning-based CT and CBCT image segmentation[J]. J Dent, 2024, 147: 105130. doi: 10.1016/j.jdent.2024.105130.

[39] Lu M, Shafiq Z, Yang W, et al. Retrospective validation of 3D Slicer against CTA source images for accurate intracerebral hematoma volumetry: a comparative study with the Tada formula[J]. BMC Med Imaging, 2025, 25(1): 518. doi: 10.1186/s12880-025-02074-5.

[40] You Y, Niu Y, Sun F, et al. Three-dimensional printing and 3D slicer powerful tools in understanding and treating neurosurgical diseases[J]. Front Surg, 2022, 9: 1030081. doi: 10.3389/fsurg.2022.1030081.

[41] 蒲根磊, 杨涵, 金铭, 等. 医学三维建模软件结合3D打印技术对颌面缺损修复的应用[J]. 中国医学工程, 2022, 30(1): 49-53. doi: 10.19338/j.issn.1672-2019.2022.01.012.
Pu GL, Yang H, Jin M, et al. Application of medical three-dimensional modeling software combined with 3D printing technology for maxillofacial defect repair[J]. China Med Eng, 2022, 30(1): 49-53. doi: 10.19338/j.issn.1672-2019.2022.01.012.

[42] Herren FL, Gerber V, Meier R, et al. Semi-automatic segmentation of cone beam computed tomography datasets for volume measurements of equine cheek teeth[J]. J Vet Dent, 2022, 39(1): 41-48. doi: 10.1177/08987564211061630.

（编辑　周春华）

Open Access
This article is licensed under a Creative Commons Attribution 4.0 International License.
Copyright © 2026 by Editorial Department of Journal of Prevention and Treatment for Stomatological Diseases

官网