[DOI]10.12016/j.issn.2096-1456.202660013

·综述·

早期龋管理研究进展

赵梅，　梁羽童，　何金枝，　程磊
口腔疾病防治全国重点实验室 国家口腔医学中心 口腔疾病国家临床医学研究中心 四川大学华西口腔医院牙体牙髓病科，四川 成都（610041）

【摘要】 局限于牙釉质的早期龋是实现龋病非手术干预的关键窗口。目前，龋病管理已从传统的“钻-补”模式转向以龋风险管理和龋损管理为核心的现代模式。本文基于龋病管理的最新理念，系统性综述了早期龋管理各方面的研究进展，包括龋风险评估、早期诊断、治疗方案选择及随访监测，总结了当前面临的主要挑战，并就人工智能在早期龋管理中的运用进行了总结和展望。在龋风险管理方面，美国牙科协会系统、龋病风险评估管理系统、Cariogram系统和龋风险评估工具等仍是临床主流工具，但人工智能技术的引入提供了更高维度、更多因素整合的预测能力，有望提升风险分层的准确性。在早期诊断方面，视诊、探诊与咬翼片仍是基础手段，但对早期龋尤其是邻面病变的灵敏度有限；定量光诱导荧光、光学相干断层扫描、近红外光透照、光纤透照、激光荧光等光学技术的应用使龋损特征数字化，为脱矿程度分析、活跃性判断及人工智能模型构建提供了数据基础。早期龋的治疗以无创和微创方式为主，再矿化治疗适用于浅表病损，渗透树脂兼具阻断进展及改善美观的优势，微研磨和漂白可作为美学处理的补充手段；激光、臭氧及光动力等新技术亦展现出潜在应用价值。治疗方案制定需综合龋活跃性、患者龋风险状态、脱矿深度、依从性与治疗意愿等因素，但目前脱矿深度仍难以精准定量，决策依据缺乏标准化。在随访管理方面，需基于风险分层制定个体化复查间隔，关注病损变化、患者依从性及复发风险。综上所述，智能化与精准化将成为未来早期龋管理的发展方向，AI在风险预测、图像分析和临床决策支持等方面的应用有望进一步提升早期龋的诊疗效率与效果。

【关键词】 早期龋；　龋病管理；　龋风险评估；　早期诊断；　再矿化治疗；　微创治疗；　人工智能

【中图分类号】 R78　**【文献标志码】** A　**【文章编号】** 2096-1456（2026）06-0585-10

【引用著录格式】 赵梅，梁羽童，何金枝，等. 早期龋管理研究进展[J]. 口腔疾病防治，2026，34(6)：585-594. doi:10.12016/j.issn.2096-1456.202660013.

微信公众号

Research progress in early caries management

ZHAO Mei, LIANG Yutong, HE Jinzhi, CHENG Lei. State Key Laboratory of Oral Diseases & National Center for Stomatology & National Clinical Research Center for Oral Diseases & Department of Endodontics, West China Hospital of Stomatology, Sichuan University , Chengdu 610041, China
Corresponding author: CHENG Lei, Email: chengleidentist@163.com

【Abstract】 Early caries confined to the enamel layer represent a critical window for achieving noninvasive intervention in caries management. Caries management has shifted from the traditional “drill-and-fill” model toward a modern paradigm centered on caries risk and lesion management. Based on contemporary concepts, this review systematically summarizes recent advances in early caries management, including caries risk assessment, early diagnosis, treatment strategy selection, and follow-up monitoring, while highlighting the major challenges currently being faced, and further reviewing and discussing the application of artificial intelligence (AI) in early caries management. In terms of risk management, conventional systems including the American Dental Association, Caries Management by Risk Assessment, Cariogram, and the Caries-Risk Assessment Tool remain mainstays in clinical practice. However, AI offers predictive

【收稿日期】 2026-01-08；　**【修回日期】** 2026-03-03
【基金项目】 国家自然科学基金(82271033)；四川省卫生健康委员会(23LCYJ016)；四川大学华西口腔医院临床研究项目(LCYJ-QN-202515)
【作者简介】 赵梅，硕士研究生在读，Email：zm20001124@126.com
【通信作者】 程磊，教授，博士，Email：chengleidentist@163.com

capability through higher-dimensional data processing and the integration of numerous influencing factors, with the potential to improve the accuracy of risk stratification. For diagnosis, visual inspection, tactile examination, and bitewing radiography remain fundamental methods, yet their sensitivity for early caries—particularly proximal lesions—is limited. The application of optical technologies, including quantitative light-induced fluorescence, optical coherence tomography, near-infrared light transillumination, fiber-optic transillumination, and laser-induced fluorescence, enables digital characterization of caries lesions, providing a data foundation for demineralization assessment, lesion activity evaluation, and AI model development. The management of early caries primarily relies on noninvasive and minimally invasive approaches. Remineralization therapy is suitable for superficial lesions, resin infiltration offers the dual advantages of inhibiting lesion progression and improving aesthetics, and microabrasion and bleaching may serve as adjunctive aesthetic treatments. Emerging modalities such as laser, ozone, and photodynamic therapy have also demonstrated potential. Treatment decision-making should comprehensively consider lesion activity, patient caries risk status, demineralization depth, patient compliance, and treatment preferences. However, precise quantification of demineralization depth remains challenging, and standardized decision-making criteria are still lacking. Follow-up management should be individualized based on risk stratification, with attention to lesion changes, patient compliance, and the risk of recurrence. In summary, intelligent and precision-based approaches are expected to define the future of early caries management, and the application of AI in risk prediction, image analysis, and clinical decision support is anticipated to further enhance the efficiency and effectiveness of early caries diagnosis and treatment.

【Key words】 early caries; caries management; caries risk assessment; early diagnosis; remineralization therapy; minimally invasive treatment; artificial intelligence

J Prev Treat Stomatol Dis, 2026, 34(6): 585-594.

【Competing interests】 The authors declare no competing interests.

This study was supported by the grants from the National Natural Science Foundation of China (No. 82271033), Sichuan Provincial Health Commission (No. 23LCYJ016), Clinical Research Program of West China Hospital of Stomatology, Sichuan University (No. LCYJ-QN-202515).

龋病是一种发生在牙齿硬组织上的慢性、进行性、破坏性疾病，是全球公共卫生的巨大挑战[1]。其病变过程由表及里，呈渐进性发展。早期龋又称非成洞型龋或成洞前龋，局限于牙齿表面尚未形成明显龋洞，呈白垩色、棕黄色或者褐色斑块，是龋病的早期形态[2]。早期龋可发生于冠部牙釉质，亦可发生于根面的牙本质或牙骨质。本文主要讨论冠部早期龋的相关问题。

早期龋的基本病理特征是口腔细菌产酸导致表层下脱矿速度超过唾液主导的再矿化速度[3]。此时，牙齿表层结构相对完整，通过抑制牙釉质脱矿或促进牙釉质再矿化过程可使病程停止，甚至恢复受损组织[4]。因此，对早期龋进行及时、科学、有效的管理，是阻止牙齿进入“钻-补-复发-再补”恶性循环、降低治疗成本、改善患者生活质量和减轻公共卫生负担的关键窗口期。

近年来，随着对龋病病因认识的更新，龋病防治的模式已经从传统的“补洞”模式转向龋病风险管理模式[5]。本文以国际国内龋病管理的最新理念为框架，针对性综述了早期龋管理的现状、进展及目前面临的主要困难及挑战，以期为龋病的有效防控提供线索。

1　龋病管理

现代龋病管理将龋病视为动态可干预过程，包括龋病的群体管理及个性化管理[6]。个性化管理针对特定个体，包含龋风险管理及基于龋风险评估的龋损管理[6]。龋风险管理通过评估个体风险，给予相应的诊治及家庭干预措施，实现龋病的早期预防与风险控制[7]。龋损管理则聚焦于已发生的龋损，通过综合分析龋风险及龋损特点，制定个体化治疗方案并实施治疗和随访监测[8-9]。基于全生命周期龋病管理理念[10]及龋病管理发展现状，龋病管理的临床实施包括：龋风险评估及管理、龋病诊断、治疗方案制定、治疗难度评估，以及匹配相应资质医生实施治疗和随访（图1）。

科学的评估工具是龋病管理实施的基础。目前国际上通用的龋病风险评估工具包括：美国牙科协会（American Dental Association，ADA）系统[11]、龋病风险评估管理（Caries Management by

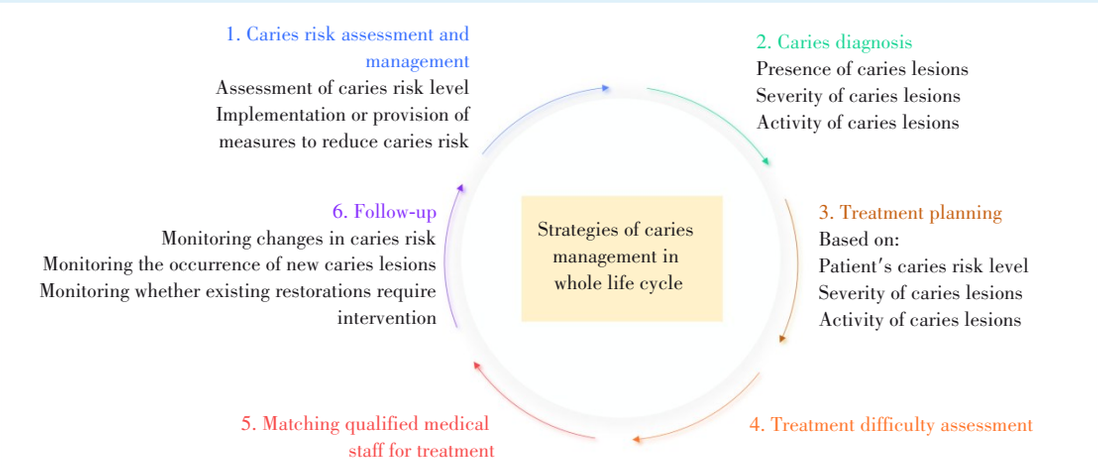

Figure 1　Schematic diagram of personalized caries management

图1　龋病个性化管理内容的示意图

Risk Assessment, CAMBRA)系统[12]、Cariogram系统[13]以及龋风险评估工具(Caries-risk Assessment Tool, CAT)系统[14]。在龋损管理方面,国际上较为知名的个性化管理工具包括:国际龋病检测与评估系统(International Caries Detection and Assessment System, ICDAS)[15]、国际龋病分类与管理系统(International Caries Classification and Management System, ICCMS)[6]。ICDAS提供了龋病诊断标准(包括严重程度和活跃度分级),确保不同医生对龋病严重程度的判断一致。ICCMS在ICDAS的基础上发展而来,不仅指导龋病诊断,同时采用"4D循环模式"来辅助决策[16]。值得注意的是,长期以来国际上缺乏针对龋损管理难度进行评估的系统及工具。我国学者通过研究影响龋病治疗难度的相关因素,建立了龋病防治难度评估系统,填补了这一领域的空白[5]。

2　早期龋管理及其进展

2.1　龋风险评估及龋风险管理

龋风险评估是现代龋病管理的基础。龋风险评估通过综合分析龋病保护因素和促进因素,判断个体或者人群在一定时间内发生龋病的概率,并提供合适的防治措施,以阻止龋病的发生发展[17-18]。ADA、CAMBRA、Cariogram以及CAT系统通过选择性分析特定的龋相关因素,预测个体在未来时间内患龋的概率[19]。龋病是一种多因素疾病,在进行龋风险评估时,考量的因素越多,评估和预测的结果越准确[20]。

龋风险管理以患者的行为管理为核心,根据龋风险评估结果(极高风险、高风险、中风险和低风险)采用不同措施。例如,Cariogram系统就在评估患者龋风险等级的同时,提供了针对不同风险等级的个体化预防建议[21]。ICCMS推荐低龋风险患者每日使用含氟牙膏刷牙2次;中龋风险患者在以上基础上加用含氟漱口水;高龋风险患者应使用高浓度氟化物牙膏、再矿化液、抗菌漱口水,并积极控制糖摄入、改善唾液分泌功能。中、高龋风险患者建议每3个月接受1次诊室干预[6]。

2.2　早期龋的诊断

龋病的诊断包括3个层面:龋损是否存在、龋损的严重程度(累及牙齿硬组织的深度)以及龋损的活跃程度。常用的方法包括视诊、探诊以及影像学检查[22]。视诊时,ICDAS推荐将患牙隔湿吹干5 s,以消除唾液对脱矿部位的"遮盖效应",避免漏诊[15]。探诊时应注意力度和手法,避免对龋损表面造成医源性损伤。咬翼片对邻面早期龋的诊断具有优势[23-24],但其诊断效能受拍摄质量、脱矿程度、阅片者经验等多重因素影响,需要结合其他诊断方法以提高综合诊断效果[25-26]。对于早期龋,尤其是位于邻面接触区的病变,上述临床检查方法虽具有较高的特异性,但灵敏度较低[27]。

2.2.1　光学诊断技术　基于龋损和健康牙体组织光学性质差异的诊断方法已逐步应用于临床实践,主要包括:定量光诱导荧光技术(quantitative light-induced fluorescence, QLF)[28]、光学相干断层成像技术(optical coherence tomography, OCT)[29-30]、

近红外光透照技术(near-infrared light transillumination, NILT)[31-32]、光纤透照技术(fiber-optic transillumination, FOTI)[33]和激光荧光技术(laser-induced fluorescence, LIF)等[34]。目前临床上基于上述技术的代表性设备包括DIAGNOdent龋检测笔和DIAGNOcam[35]。

2.2.2　早期龋严重程度评估　在早期龋严重程度评估方面,ICDAS以颜色改变程度来提示早期龋牙釉质的不同脱矿深度,但未提供量化指标[36]。ICCMS基于影像学资料对早期龋及其严重程度进行分级:1级累及表层1/2牙釉质;2级累及牙釉质全层[16]。由于不同部位牙釉质存在厚度差异,相同分级的早期龋其脱矿深度可能存在差异。此外,二维影像学资料无法提供唇颊舌腭面脱矿深度的准确信息。

2.2.3　早期龋活跃性评估　龋活跃度是指在一定时期内龋损进一步发展的可能性,可分为活跃龋与静止龋[37]。国际广泛接受的龋损活跃度评价标准包括Nyvad系统[38]、ICDAS龋活跃性评估系统(ICDAS Caries Activity Assessment, ICDAS-CAA)[15, 39]和ICCMS系统[40],主要通过病损区颜色、光泽度、质地、菌斑滞留情况、病损位置等指标进行评估(表1)。对于早期龋,Nyvad和ICCMS系统的评价指标相似,而ICDAS-CAA则进一步对不同的指标进行了赋分,根据赋分结果进行半定量分析。相较而言,Nyvad系统使用简便、重复性好[41];ICDAS-CAA通过量化评分提高对龋活跃性评价的标准程度;而ICCMS作为一种龋病管理综合系统,将龋活跃性评估视为整个龋病管理流程的一部分,整合了ICDAS的分级标准和基于Nyvad修改的活跃性评估标准[42]。虽然龋活跃性评估在早期龋管理中的重要性日益受到重视,但这些标准的使用率仍然较低[5]。2024年,欧洲龋病研究组织与欧洲保守牙科联合会发布最新共识,建议将龋损活跃性纳入常规评估,并据此制定个体化管理方案[43]。

表1　早期龋活跃性评价标准

Table 1　Criteria for assessing early caries activity

	Nyvad criteria		ICDAS-CAA		ICCMS	
	Active caries	Inactive caries	Active caries	Inactive caries	Active caries	Inactive caries
Color	White or light yellow	White, brown or black	Brown (1 point) White (3 points) Black (4 points)	Brown (1 point) White (3 points) Black (4 points)	Chalky, brown	Chalky, brown, or black
Luster	Absent	Present	NA	NA	Absent	Present
Tactile	Rough	Hard/Smooth	Smooth (2 points) Rough (4 points)	Smooth (2 points) Rough (4 points)	Rough	Hard/Smooth
Plaque	Present	NA	Present (3 points) Absent (1 point)	Present (3 points) Absent (1 point)	Present	Absent
Lesion location	Close to the gingival margin	Usually away from the gingival margin	NA	NA	Plaque retention areas (e.g., near the gingival margin, pits, and fissures)	Cleanable areas, usually away from the gingival margin
Gingiva	NA	NA	Healthy gingiva (0 points) Gingival bleeding (3 points)	Healthy gingiva (0 points) Gingival bleeding (3 points)	NA	NA
Other	NA	NA	> 7 points	≤ 7 points	NA	NA

ICDAS-CAA: International Caries Detection and Assessment System-Caries Activity Assessment; ICCMS: International Caries Classification and Management System; NA: not applicable

2.3　早期龋的治疗方式

早期龋治疗的目的包括阻止疾病进展、恢复牙体硬组织健康及改善部分美学问题。核心非手术治疗包括控制菌斑与饮食管理、再矿化治疗和渗透树脂。控制菌斑与饮食管理是基础,通过减少患龋部位的酸暴露,可提升治疗成功率。再矿化治疗是目前运用最广泛的早期龋无创治疗方式。常用的再矿化材料包括含氟凝胶、含氟涂料等,通过促进牙釉质表面再矿化、增强牙釉质抗酸能力,从而逆转病变进程[44]。除氟化物外,以磷酸钙为核心的技术,如酪蛋白磷酸肽-无定形磷酸钙(casein phosphopeptide-amorphous calcium phos-

phate，CPP-ACP）、生物活性玻璃、纳米羟基磷灰石、自组装肽等新型材料，可作为氟化物治疗的补充[45-47]。再矿化治疗操作简单、成本较低，但主要作用于浅层病变，对深层病变的修复能力有限[48]，其治疗效果高度依赖于患者的依从性[49]、唾液流速、流量以及矿物质浓度[44]。渗透树脂利用低黏度、高流动性的光固化树脂，通过毛细作用渗透到早期龋损内部的多孔疏松结构中，阻断病变进展并改善牙齿外观。该技术对患者依从性要求低、效果显著[50-51]。用于早期龋治疗的非常规技术还包括牙釉质微研磨术和牙齿漂白。微研磨技术通过研磨和酸处理相结合的方式，去除脱矿牙釉质，达到阻止龋病进展的目的[52]。微研磨改善牙齿美观方面的治疗效果持久且显著，经过微研磨处理后的牙齿表面光滑度提高，可减少菌斑积聚，降低龋齿发生风险，但存在牙体组织损伤大、操作要求高等局限性[53]。牙齿漂白对早期龋不具备治疗效应，仅通过降低病变区域与健康组织之间的颜色差异，达到改善牙齿美观的作用[54]。临床上可联合两种或者3种技术来改善早期龋所致美观问题[55]。

新兴早期龋治疗手段还包括激光技术和臭氧技术。铒激光和二氧化碳激光可精准去除病变组织并刺激再矿化[56]；Er：YAG激光可调节牙菌斑生物膜的致龋菌比例以及生物多样性，从而预防龋病[57]。光动力疗法通过激活光敏剂释放氧自由基，杀灭致龋菌、破坏牙菌斑生物膜，可作为辅助治疗手段[58]。臭氧治疗则利用其强效抗菌特性杀灭致龋菌并抑制菌斑再生，仅作为辅助治疗应用[59]。

2.4　早期龋治疗方案的制定

早期龋治疗方案的制定需综合评估患者的龋活跃性、龋损特点、患者特点（包括需求和偏好、生活方式、口腔卫生习惯及治疗意愿）等多个因素。核心原则是尽可能通过非手术方法阻止或逆转早期龋损，保留健康的牙体组织。

早期龋的龋风险高低和龋损活跃度决定病变进展的可能性及治疗的紧迫性。低龋风险患者以预防为主，中、高龋风险患者需增加个性化非手术干预措施。ICCMS基于病损水平定制策略，核心理念是最大限度地保留牙体组织。对于活跃性早期龋，推荐非手术治疗，通过病因控制、再矿化疗法或渗透树脂治疗等使其转变为非活跃性或静止性病变。对于健康牙面及非活跃性早期龋损，仅限于基于风险的预防。仅在病损发展至临床分类的“中度”且放射学深度达牙本质外1/3的临界情况下，ICCMS才推荐临床医生在继续非手术管理与牙体保留性操作治疗之间进行个体化选择[16, 60]。

目前尚无指南对早期龋非手术治疗方案的选择提供指导。早期龋严重程度（即牙釉质脱矿深度）的精准评估对方案的选择具有重要临床意义。氟化物所致的矿物质沉积通常仅限于龋损外层30~50 μm[61]，渗透树脂的渗透深度通常在500 μm以内[62]，微研磨术通常要求磨除的牙体组织在200 μm以内[63-64]。目前检测方法难以精准量化牙釉质脱矿深度，导致早期龋治疗方式的选择缺乏标准化决策依据，治疗过程常具有较强的尝试性、主观性以及不可预测性。因此，研发早期龋严重程度的可靠辅助诊断工具有重要临床价值。

2.5　早期龋治疗难度评估

龋病治疗过程受患者全身因素、口腔局部因素、龋损因素及治疗方式等多重因素影响，其难度在不同患者之间乃至同一患者的不同龋损之间均存在显著差异[65-66]。难度评估可指导病例分级，实现低难度病例全科医师处理，高难度病例牙体牙髓专科医师甚至龋病专家治疗，最终达到优化医疗资源配置，提高诊疗效率和成功率的目的。对于极高龋风险、张口度小、咽反射明显、唾液分泌异常或旧修复体脱落≥2次的患者，其治疗应由龋病临床专家实施[5]。

2.6　早期龋随访管理

英国国家卫生与临床优化研究所（National Institute for Health and Care Excellence，NICE）建议结合疾病状态和龋病风险进行个性化随访[67]。ICCMS亦建议应根据患者的年龄和龋病风险状态进行个体化随访，并认为这是保证早期龋非手术治疗成功的重要环节。ICCMS随访机制结合了回顾（评估患者龋风险因素的变化与行为干预的执行）和监测（评估牙列状态、病变活跃性、新龋损发生、修复体完整性）[6]。低龋风险患者每年随访≥1次，中风险2~3次，高风险每3个月1次。课题组前期研究发现，早期龋经渗透树脂处理后若发生继发脱矿，QLF难以准确反映病变变化，此类病例需重点关注修复体边缘及局部再脱矿，可结合影像与其他方法综合评估[68]。

2.7　人工智能在早期龋管理中的应用

基于深度学习的人工智能（artificial intelligence，AI）能够整合多维数据，提高龋风险评估的效率与客观性，提升早期龋诊断的准确性，并辅助临床决策[69-72]。

2.7.1　龋风险评估　AI的应用推动了新型龋风险评估系统的发展[73]。借助深度学习和机器学习算法，研究者可同时分析数个龋保护及风险因素在不同龋风险人群中的分布规律，提升预测准确性[74]。口腔微生物组由700余种微生物组成，其组成改变是龋病的始动因子[75-76]。Teng等[77]使用AI算法分析患龋前后口腔微生物组的时空特征，构建可预测特定患者龋风险的智能模型；并进一步优化出了可对特定牙齿患龋风险进行预测的模型，准确率超过90%[78]。此外，也有研究通过AI分析宿主、环境等非微生物因素或多因素综合进行龋风险评估[79-80]。但上述模型尚缺乏大规模、多中心的临床试验进行验证[73]。

2.7.2　早期龋诊断　近年来，AI在龋病诊断领域的前景被逐步发掘[81-82]。数字化技术，包括数字化影像技术[69, 83]、口内数码照片[84]、QLF[85-86]、OCT[87]、NILT[88]、FOTI、LIF[89]等可将龋损特征进行数字化转化的技术，为AI进行龋病诊断奠定了基础。目前，AI在成洞型龋损诊断方面的技术已在部分国家获准临床应用。例如，美国食品药品监督管理局（Food and Drug Administration，FDA）认证的人工智能齿科平台OVERJET可从数字化X线片上自动识别龋损及其严重程度[90]；Pearl作为首个获得FDA、欧洲合格认证（Conformité Européenne，CE）、加拿大卫生部三重认证的AI龋病诊断软件，可从X线片及CBCT上自动检测并标注龋损[91]。基于深度卷积神经网络的AI模型在咬翼片和口内图像分析中能高效地识别早期龋，并减少医生间的主观判断差异[81, 90]。然而，与AI在成洞型龋损诊断中的运用研究相比，其在早期龋诊断中的作用尚未被充分挖掘，特别是在脱矿深度定量评估方面研究仍相对有限[92]。课题组前期研究结果显示，QLF图像中龋损区域荧光损失量与脱矿深度存在显著相关性，利用AI识别这一规律可能是诊断早期龋严重程度的可行方向[68, 93]。

2.7.3　治疗决策支持　在早期龋治疗中，AI能够协助临床医生更准确地执行ICCMS的治疗决策框架。通过深度学习算法，AI可分析龋病风险，辅助判断病变的活跃性及发展趋势，并综合患者治疗意愿、原有修复体的状态、社会经济地位等多维因素[94-95]，使治疗更加具有个性化和针对性[65]。牙科临床决策支持系统（Clinical Decision Support System，CDSS）通过整合龋病风险评估和牙齿状态等数据，提供基于证据的治疗建议，并自动提醒潜在的健康风险或优先处理事项。AI的引入可以进一步优化决策过程，提高诊疗效率和准确性[96]，并有助于提升牙科助理在患者管理、放射影像分析及治疗方案制定中的作用[94]。

2.7.4　挑战与展望　尽管AI在早期龋管理的风险评估、诊断和治疗决策等环节展现出较大潜力，但临床推广仍面临诸多挑战[97]。现有模型缺乏大规模、多中心的临床试验验证，泛化能力有待证实[69]，未来的研究应聚焦于临床验证，并致力于通过多模态数据的结合来提高诊断的敏感性，以确保早期龋能在可逆转阶段被及时识别[98]。更深层次的挑战源于临床信任度不足、责任判定模糊以及缺乏统一的临床验证标准[99]。根据公众偏好调查，AI模型的“黑箱性”与性能之间的权衡是核心矛盾，缺乏“可解释性”将阻碍医患沟通及知情同意的有效实施[100]。此外，AI系统的购置及维护成本以及医务人员的培训也是临床推广的障碍。

3　总结及展望

早期龋的管理是维持牙齿结构完整性、避免进入有创修复循环的关键窗口期。现代龋病管理模式已从传统的“补洞”模式过渡到将龋风险管理与个性化龋损管理相结合的模式。针对活跃性早期龋损，ICCMS等系统明确建议优先采用非手术治疗以终止病变活跃性。当前主要治疗手段包括以新型磷酸钙类和纳米羟基磷灰石等为补充的再矿化治疗以及渗透树脂等微创技术。然而，早期龋治疗方案的选择目前仍缺乏统一的标准化决策依据，效果易受患者依从性、个体差异及脱矿深度难以精准量化等因素影响。展望未来，早期龋的管理将趋向智能化与精准化：一方面，AI技术在龋风险评估、早期龋图像分析及治疗决策支持系统中的应用，将极大提升诊断准确性、优化群体管理和个性化治疗方案的制定效率。另一方面，临床工作应致力于整合微创干预策略（如微研磨与渗透树脂的联合应用）并充分利用治疗难度评估系统，以实现医疗资源的优化配置和治疗效果的最大化。在确保技术可靠性、解决高成本和隐私等应用局限性的前提下，AI作为辅助工具的普及，将是推动早期龋管理模式升级的重要方向。

【Author contributions】 Zhao M wrote the article. Liang YT, He JZ collected the references, revised the article. Cheng L conceptualized and reviewed the article. All authors read and approved the final manuscript as submitted.

参考文献

[1] World Health Organization. Global oral health status report: towards universal health coverage for oral health by 2030[R]. Geneva: World Health Organization, 2022.

[2] Machiulskiene V, Campus G, Carvalho JC, et al. Terminology of dental caries and dental caries management: consensus report of a workshop organized by ORCA and cariology research group of IADR[J]. Caries Res, 2020, 54(1): 7-14. doi: 10.1159/000503309.

[3] González-Cabezas C. The chemistry of caries: remineralization and demineralization events with direct clinical relevance[J]. Dent Clin North Am, 2010, 54(3): 469-478. doi: 10.1016/j.cden.2010.03.004.

[4] Preethanath R, Anil A, Anil S, et al. Demineralization and remineralization dynamics and dental caries[M]//Rusu LC, Ardelean LC, eds. Dental caries-the selection of restoration methods and restorative materials. Rijeka: IntechOpen, 2022.

[5] Cheng L, Zhang L, Yue L, et al. Expert consensus on dental caries management[J]. Int J Oral Sci, 2022, 14(1): 17. doi: 10.1038/s41368-022-00167-3.

[6] Ismail AI, Pitts NB, Tellez M, et al. The international caries classification and management system (ICCMS™) an example of a caries management pathway[J]. BMC Oral Health, 2015, 15Suppl 1 (Suppl 1): S9. doi: 10.1186/1472-6831-15-S1-S9.

[7] Featherstone JDB, Mascarenhas AK, Sarkari CD. A value-based care program in dentistry centered on caries risk assessment: preliminary results[J]. J Am Dent Assoc, 2025, 156(7): 547-554. doi: 10.1016/j.adaj.2025.04.002.

[8] 陈智, 卢展民, Schwendicke Falk , 等 . 龋损管理: 龋坏组织去除的专家共识[J]. 中华口腔医学杂志, 2016, 51(12): 712-716. doi: 10.3760/cma.j.issn.1002-0098.2016.12.003.
Chen Z, Lu ZM, Schwendicke F, et al. Managing carious lesions: consensus recommendations on carious tissue removal[J]. Chin J Stomatol, 2016, 51(12): 712-716. doi: 10.3760/cma. j. issn. 1002-0098.2016.12.003.

[9] Park M, Patel F, Santos MJ, et al. Utilization of caries risk assessment tools within the underserved population: a scoping review[J]. BMC Oral Health, 2025, 25(1): 330. doi: 10.1186/s12903-025-05637-8.

[10] 周学东, 程磊, 郑黎薇 . 全生命周期的龋病管理[J]. 中华口腔医学杂志 , 2018, 53(6): 367-373. doi: 10.3760/cma. j. issn. 1002-0098.2018.06.002.
Zhou XD, Cheng L, Zheng LW. Strategies of caries management in whole life cycle[J]. Chin J Stomatol, 2018, 53(6): 367-373. doi: 10.3760/cma.j.issn.1002-0098.2018.06.002.

[11] American Dental Association. Caries risk assessment form completion instructions[Z/OL]. Chicago: American Dental Association, 2011. https: //www. ada. org/-/media/project/ada-organization/ada/ada-org/files/resources/library/oral-health-topics/ada_caries_risk_assessment.pdf.

[12] Featherstone JDB, Chaffee BW. The evidence for caries management by risk assessment (CAMBRA®)[J]. Adv Dent Res, 2018, 29 (1): 9-14. doi: 10.1177/0022034517736500.

[13] Bratthall D, Hänsel Petersson G. Cariogram - a multifactorial risk assessment model for a multifactorial disease[J]. Community Dent Oral Epidemiol, 2005, 33(4): 256-264. doi: 10.1111/j. 1600-0528.2005.00233.x.

[14] American Academy of Pediatric Dentistry Council on Clinical Affairs. Policy on use of a caries-risk assessment tool (CAT) for infants, children, and adolescents[J]. Pediatr Dent, 2005-2006, 27(7 Suppl): 25-27.

[15] Ismail AI, Sohn W, Tellez M, et al. The international caries detection and assessment system (ICDAS): an integrated system for measuring dental caries[J]. Community Dent Oral Epidemiol, 2007, 35 (3): 170-178. doi: 10.1111/j.1600-0528.2007.00347.x.

[16] Pitts NB, Martignon S, Douglas GVA, et al. ICCMS™ guide for practitioners and educators[C]. London: ICDAS Foundation, 2014.

[17] Ng TC, Luo BW, Lam WY, et al. Updates on caries risk assessment-a literature review[J]. Dent J (Basel), 2024, 12(10): 312. doi: 10.3390/dj12100312.

[18] Olatosi OO, Schroth RJ, DeMaré D, et al. Healthcare providers′ perspectives on the Canadian caries risk assessment tool implementation in indigenous pediatric primary care: a qualitative study [J]. BMC Oral Health, 2025, 25(1): 708. doi: 10.1186/s12903-025-06036-9.

[19] Featherstone JDB, Crystal YO, Alston P, et al. A comparison of four caries risk assessment methods[J]. Front Oral Health, 2021, 2: 656558. doi: 10.3389/froh.2021.656558.

[20] Schroth RJ, Rothney J, Sturym M, et al. A systematic review to inform the development of a Canadian caries risk assessment tool for use by primary healthcare providers[J]. Int J Paediatr Dent, 2021, 31(6): 767-791. doi: 10.1111/ipd.12776.

[21] Doitchinova L, Kirov D, Nikolova J, et al. Caries risk assessment in adults using the cariogram[J]. Folia Med (Plovdiv), 2020, 62(4): 831-837. doi: 10.3897/folmed.62.e51874.

[22] Walsh T, Macey R, Ricketts D, et al. Enamel caries detection and diagnosis: an analysis of systematic reviews[J]. J Dent Res, 2022, 101(3): 261-269. doi: 10.1177/00220345211042795.

[23] Muhonen MH, Raittio E, Olkkonen L, et al. Bitewing radiographs in proximal caries diagnostics and restorative treatment of adults: a retrospective study of electronic health records[J]. Caries Res, 2025. doi: 10.1159/000549383.

[24] Carvalho BKG, Nolden EL, Wenning AS, et al. Diagnostic accuracy of artificial intelligence for approximal caries on bitewing radiographs: a systematic review and meta-analysis[J]. J Dent, 2024, 151: 105388. doi: 10.1016/j.jdent.2024.105388.

[25] Keenan JR, Keenan AV. Accuracy of dental radiographs for caries detection[J]. Evid Based Dent, 2016, 17(2): 43. doi: 10.1038/sj.ebd.6401166.

[26] Wenzel A. Digital radiography and caries diagnosis[J]. Dentomaxillofac Radiol, 1998, 27(1): 3-11. doi: 10.1038/sj.dmfr.4600321.

[27] Kocak N, Cengiz-Yanardag E. Clinical performance of clinical-visual examination, digital bitewing radiography, laser fluorescence, and near-infrared light transillumination for detection of non-cavitated proximal enamel and dentin caries[J]. Lasers Med Sci, 2020, 35(7): 1621-1628. doi: 10.1007/s10103-020-03021-2.

[28] Lee ES, Hwang J, Cheng L, et al. Diagnostic accuracy of quantita-

tive light-induced fluorescence in detecting caries of various types and locations: a systematic review and meta-analysis[J]. Sci Rep, 2025, 15: 39905. doi: 10.1038/s41598-025-23631-6.

[29] Balhaddad AA, Alharamlah F, Albrahim HF, et al. Assessing diagnostic accuracy and monitoring of caries progression using optical coherence tomography (OCT): a systematic review[J]. J Dent, 2025, 155: 105628. doi: 10.1016/j.jdent.2025.105628.

[30] Strumpski M, Schneider H, Rüger C, et al. Validity and reliability of intraoral optical coherence tomography and bitewing radiography for detecting approximal carious lesions[J]. Caries Res, 2025, 59(6): 476-489. doi: 10.1159/000544789.

[31] Methuen M, Suominen AL, Lussi A, et al. Near-infrared light transillumination (NIR-LT) *vs* clinical-visual inspection/FOTI to detect interproximal caries lesions *in vivo*[J]. Quintessence Int, 2024, 55(10): 834-843. doi: 10.3290/j.qi.b5714710.

[32] Macey R, Walsh T, Riley P, et al. Transillumination and optical coherence tomography for the detection and diagnosis of enamel caries[J]. Cochrane Database Syst Rev, 2021, 1(1): CD013855. doi: 10.1002/14651858.CD013855.

[33] Marmaneu-Menero A, Iranzo-Cortés JE, Almerich-Torres T, et al. Diagnostic validity of digital imaging fiber-optic transillumination (DIFOTI) and near-infrared light transillumination (NILT) for caries in dentine[J]. J Clin Med, 2020, 9(2): 420. doi: 10.3390/jcm9020420.

[34] 梁景平. 龋病早期诊断新技术的研究与应用[J]. 中华口腔医学杂志, 2021, 56(1): 33-38. doi: 10.3760/cma. j. cn112144-20201108-00558.
Liang JP. Research and application of new techniques for early diagnosis of caries[J]. Chin J Stomatol, 2021, 56(1): 33-38. doi: 10.3760/cma.j.cn112144-20201108-00558.

[35] Sürme K, Kara NB, Yilmaz Y. *In vitro* evaluation of occlusal caries detection methods in primary and permanent teeth: a comparison of CarieScan PRO, DIAGNOdent pen, and DIAGNOcam methods [J]. Photobiomodul Photomed Laser Surg, 2020, 38(2): 105-111. doi: 10.1089/photob.2019.4686.

[36] Caceda JH, Jiang S, Calderon V, et al. Sensitivity and specificity of the ICDAS II system and bitewing radiographs for detecting occlusal caries using the spectra™ caries detection system as the reference test in children[J]. BMC Oral Health, 2023, 23(1): 896. doi: 10.1186/s12903-023-03615-6.

[37] Nyvad B, Baelum V. Nyvad criteria for caries lesion activity and severity assessment: a validated approach for clinical management and research[J]. Caries Res, 2018, 52(5): 397-405. doi: 10.1159/000480522.

[38] Nyvad B, Machiulskiene V, Baelum V. Reliability of a new caries diagnostic system differentiating between active and inactive caries lesions[J]. Caries Res, 1999, 33(4): 252-260. doi: 10.1159/000016526.

[39] ICDAS Coordinating Committee. International caries detection and assessment system (ICDAS II): manual criteria[S]. Budapest: ICDAS Coordinating Committee, 2009.

[40] Pitts NB, Ekstrand KR. International caries detection and assessment system (ICDAS) and its international caries classification and management system (ICCMS) - methods for staging of the caries process and enabling dentists to manage caries[J]. Community Dent Oral Epidemiol, 2013, 41(1): e41-e52. doi: 10.1111/cdoe.12025.

[41] Abdalla H, Allison PJ, Madathil SA, et al. Caries lesions progression in adults: a prospective 2-year cohort study[J]. Community Dent Oral Epidemiol, 2025, 53(1): 33-41. doi: 10.1111/cdoe.13005.

[42] Pitts NB, Banerjee A, Mazevet ME, et al. From 'ICDAS' to 'CariesCare International': the 20-year journey building international consensus to take caries evidence into clinical practice[J]. Br Dent J, 2021, 231(12): 769-774. doi: 10.1038/s41415-021-3732-2.

[43] Neuhaus KW, Kühnisch J, Banerjee A, et al. Organization for caries research-European federation of conservative dentistry consensus report on clinical recommendations for caries diagnosis paper II: caries lesion activity and progression assessment[J]. Caries Res, 2024, 58(5): 511-520. doi: 10.1159/000538619.

[44] González-Cabezas C, Fernández CE. Recent advances in remineralization therapies for caries lesions[J]. Adv Dent Res, 2018, 29(1): 55-59. doi: 10.1177/0022034517740124.

[45] Bröseler F, Tietmann C, Bommer C, et al. Randomised clinical trial investigating self-assembling peptide P_{11}-4 in the treatment of early caries[J]. Clin Oral Investig, 2020, 24(1): 123-132. doi: 10.1007/s00784-019-02901-4.

[46] Shen P, Fernando JR, Yuan Y, et al. Efficient enamel subsurface lesion remineralisation and dentine tubule occlusion by high concentration CPP-ACP: a randomised, cross-over *in situ* study[J]. Sci Rep, 2025, 15(1): 28263. doi: 10.1038/s41598-025-14005-z.

[47] Sleem MM, Eid EG, Abdelghany AM, et al. Evaluation of the remineralization potential of different bioactive glass varnishes on white spot lesions: an *in vitro* study[J]. BMC Oral Health, 2025, 25(1): 1284. doi: 10.1186/s12903-025-06665-0.

[48] Butera A, Gallo S, Pascadopoli M, et al. Home oral care with biomimetic hydroxyapatite *vs*. conventional fluoridated toothpaste for the remineralization and desensitizing of white spot lesions: randomized clinical trial[J]. Int J Environ Res Public Health, 2022, 19(14): 8676. doi: 10.3390/ijerph19148676.

[49] Willmot DR. White lesions after orthodontic treatment: does low fluoride make a difference?[J]. J Orthod, 2004, 31(3): 235-242. doi: 10.1179/146531204225022443.

[50] Kashash Y, Hein S, Göstemeyer G, et al. Resin infiltration versus fluoride varnish for visual improvement of white spot lesions during multibracket treatment. A randomized-controlled clinical trial [J]. Clin Oral Investig, 2024, 28(6): 308. doi: 10.1007/s00784-024-05695-2.

[51] Predapramote V, Tantilertanant Y, Srisawasdi S. Evaluation of resin infiltration for inhibiting initial caries progression: an *in vitro* study using micro-computed tomographic analysis[J]. Saudi Dent J, 2024, 36(5): 745-750. doi: 10.1016/j.sdentj.2024.03.003.

[52] Rocha AO, Cardoso K, Goebel MC, et al. A global overview of enamel microabrasion for white spot lesions: a bibliometric review [J]. Restor Dent Endod, 2024, 49(3): e29. doi: 10.5395/rde.2024.49.e29.

[53] Villalobos-Tinoco J, Jurado CA, Rojas-Rueda S, et al. Micro- and macroabrasion in the esthetic zone: a narrative review and case study[J]. Dent J (Basel), 2025, 13(5): 183. doi: 10.3390/dj13050183.

[54] Barbosa LMM, Baracco B, Carneiro TS, et al. Impact of bleaching on white spot lesions: hydrogen peroxide permeability and color alteration[J]. Clin Oral Investig, 2025, 29(9): 401. doi: 10.1007/s00784-025-06490-3.

[55] Saxena P, Grewal MS, Agarwal P, et al. Clinical efficacy of resin infiltration technique alone or in combination with micro abrasion and in-office bleaching in adults with mild-to-moderate fluorosis stains[J]. J Pharm Bioallied Sci, 2021, 13(Suppl 1): S301-S305. doi: 10.4103/jpbs.JPBS_795_20.

[56] Majeed MM, Al-Taee LA. Microinvasive treatment modalities in operative dentistry[Z]. Baghdad: University of Baghdad College of Dentistry, 2023.

[57] Huang W, Zheng P, Huang Y, et al. The impact of Er: YAG laser combined with fluoride treatment on the supragingival plaque microbiome in children with multiple caries: a dynamic study[J]. BMC Oral Health, 2022, 22(1): 537. doi: 10.1186/s12903-022-02537-z.

[58] Suresh N, Joseph B, Sathyan P, et al. Photodynamic therapy: an emerging therapeutic modality in dentistry[J]. Bioorg Med Chem, 2024, 114: 117962. doi: 10.1016/j.bmc.2024.117962.

[59] Santos GM, Pacheco RL, Bussadori SK, et al. Effectiveness and safety of ozone therapy in dental caries treatment: systematic review and meta-analysis[J]. J Evid Based Dent Pract, 2020, 20(4): 101472. doi: 10.1016/j.jebdp.2020.101472.

[60] FDI World Dental Federation. FDI policy statement on Classification of caries lesions of tooth surfaces and caries management systems: adopted by the FDI general assembly: 17 September 2011, Mexico City, Mexico[J]. Int Dent J, 2013, 63(1): 4-5. doi: 10.1111/idj.12014.

[61] Ishac A, Daou D. Fluoride penetration depth and its impact on white spot lesions and molar incisor hypo-mineralization: a literature review[J]. Bull Stomatol Maxillofac Surg, 2025, 21(3): 74-81. doi: 10.58240/1829006X-2025.3-74.

[62] Ibrahim DFA, Venkiteswaran A, Hasmun NN. The penetration depth of resin infiltration into enamel: a systematic review[J]. J Int Soc Prev Community Dent, 2023, 13(3): 194-207. doi: 10.4103/jispcd.JISPCD_36_23.

[63] Pini NIP, Sundfeld-Neto D, Aguiar FHB, et al. Enamel microabrasion: an overview of clinical and scientific considerations[J]. World J Clin Cases, 2015, 3(1): 34-41. doi: 10.12998/wjcc.v3.i1.34.

[64] Favoreto MW, Condolo L, Camargo CM, et al. Impact of microabrasion and a remineralizing agent before in-office bleaching on hydrogen peroxide permeability, color alteration, and enamel morphology[J]. J Dent, 2025, 156: 105655. doi: 10.1016/j.jdent.2025.105655.

[65] 周学东, 凌均棨, 梁景平, 等. 龋病临床治疗难度因素及处理[J]. 华西口腔医学杂志, 2017, 35(1): 1-7. doi: 10.7518/hxkq.2017.01.001.
Zhou XD, Ling JQ, Liang JP, et al. Difficulty influence factors of dental caries clinical treatment[J]. West Chin J Stomatol, 2017, 35(1): 1-7. doi: 10.7518/hxkq.2017.01.001.

[66] 张宁, 王翔宇, 侯如霞, 等. 慢病管理模式在低龄儿童龋中的应用[J]. 口腔疾病防治, 2022, 30(9): 670-674. doi: 10.12016/j.issn.2096-1456.2022.09.009.
Zhang N, Wang XY, Hou RX, et al. Application of chronic disease management model in early childhood caries[J]. J Prev Treat Stomatol Dis, 2022, 30(9): 670-674. doi: 10.12016/j.issn.2096-1456.2022.09.009.

[67] National Institute for Health and Care Excellence. Dental checks: intervals between oral health reviews: clinical guideline[M]. London: National Institute for Health and Care Excellence (NICE), 2024.

[68] Shi Y, Feng X, Li M, et al. Application of quantitative light-induced fluorescence technology in early caries detection and resin infiltration treatment[J]. J Dent, 2025, 162: 106086. doi: 10.1016/j.jdent.2025.106086.

[69] Albano D, Galiano V, Basile M, et al. Artificial intelligence for radiographic imaging detection of caries lesions: a systematic review[J]. BMC Oral Health, 2024, 24(1): 274. doi: 10.1186/s12903-024-04046-7.

[70] Luke AM, Rezallah NNF. Accuracy of artificial intelligence in caries detection: a systematic review and meta-analysis[J]. Head Face Med, 2025, 21(1): 24. doi: 10.1186/s13005-025-00496-8.

[71] Mohammad-Rahimi H, Motamedian SR, Rohban MH, et al. Deep learning for caries detection: a systematic review[J]. J Dent, 2022, 122: 104115. doi: 10.1016/j.jdent.2022.104115.

[72] Chen YW, Stanley K, Att W. Artificial intelligence in dentistry: current applications and future perspectives[J]. Quintessence Int, 2020, 51(3): 248-257. doi: 10.3290/j.qi.a43952.

[73] Noor Uddin A, Ali SA, Lal A, et al. Applications of AI-based deep learning models for detecting dental caries on intraoral images - a systematic review[J]. Evid Based Dent, 2025, 26(1): 71-72. doi: 10.1038/s41432-024-01089-1.

[74] Rokhshad R, Banakar M, Shobeiri P, et al. Artificial intelligence in early childhood caries detection and prediction: a systematic review and meta-analysis[J]. Pediatr Dent, 2024, 46(6): 385-394.

[75] He J, Cheng L. The oral microbiome: a key determinant of oral health[J]. Adv Exp Med Biol, 2025, 1472: 133-149. doi: 10.1007/978-3-031-79146-8_9.

[76] 徐万宁, 廖生, 彭显, 等. 基于CiteSpace的龋病微生态微生物领域的趋势与热点研究[J]. 口腔疾病防治, 2024, 32(12): 933-944. doi: 10.12016/j.issn.2096-1456.202440319.
Xu WN, Liao G, Peng X, et al. CiteSpace-based analysis of research trends and hotspots in the field of microbiomes and microbes of dental caries[J]. J Prev Treat Stomatol Dis, 2024, 32(12): 933-944. doi: 10.12016/j.issn.2096-1456.202440319.

[77] Teng F, Yang F, Huang S, et al. Prediction of early childhood caries *via* spatial-temporal variations of oral microbiota[J]. Cell Host Microbe, 2015, 18(3): 296-306. doi: 10.1016/j.chom.2015.08.005.

[78] Yang F, Teng F, Zhang Y, et al. Single-tooth resolved, whole-mouth prediction of early childhood caries *via* spatiotemporal

variations of plaque microbiota[J]. Cell Host Microbe, 2025, 33(6): 1019-1032.e6. doi: 10.1016/j.chom.2025.05.006.

[79] Ho TE, Yang YM, Gu WJ, et al. Construction of an early childhood caries risk prediction model based on the oral microbiome: a nested case-control study[J]. BMC Oral Health, 2025, 25(1): 923. doi: 10.1186/s12903-025-06147-3.

[80] Wu TT, Xiao J, Sohn MB, et al. Machine learning approach identified multi-platform factors for caries prediction in child-mother dyads[J]. Front Cell Infect Microbiol, 2021, 11: 727630. doi: 10.3389/fcimb.2021.727630.

[81] Lee S, Oh SI, Jo J, et al. Deep learning for early dental caries detection in bitewing radiographs[J]. Sci Rep, 2021, 11(1): 16807. doi: 10.1038/s41598-021-96368-7.

[82] Park EY, Jeong S, Kang S, et al. Tooth caries classification with quantitative light-induced fluorescence (QLF) images using convolutional neural network for permanent teeth *in vivo*[J]. BMC Oral Health, 2023, 23(1): 981. doi: 10.1186/s12903-023-03669-6.

[83] Jiang F, Li S, Liu J, et al. Deep learning-based tooth segmentation for enhanced visualization of dental anomalies and pathologies[J]. Ann Anat, 2026, 264: 152771. doi: 10.1016/j.aanat.2025.152771.

[84] Moharrami M, Farmer J, Singhal S, et al. Detecting dental caries on oral photographs using artificial intelligence: a systematic review[J]. Oral Dis, 2024, 30(4): 1765-1783. doi: 10.1111/odi.14659.

[85] Ding L, He D, Zheng S, et al. *In-vitro* and *in-vivo* comparative studies of treatment effects on enamel demineralization during orthodontic therapy: implications for clinical early-intervention strategy[J]. Clin Oral Investig, 2024, 28(10): 545. doi: 10.1007/s00784-024-05944-4.

[86] Oh SH, Lee SR, Choi JY, et al. Detection of dental caries and cracks with quantitative light-induced fluorescence in comparison to radiographic and visual examination: a retrospective case study [J]. Sensors (Basel), 2021, 21(5): 1741. doi: 10.3390/s21051741.

[87] Janjua OS, Jeelani W, Khan MI, et al. Use of optical coherence tomography in dentistry[J]. Int J Dent, 2023, 2023: 4179210. doi: 10.1155/2023/4179210.

[88] Ortiz MIG, de Melo Alencar C, De Paula BLF, et al. Accuracy of near-infrared light transillumination (NILT) compared to bitewing radiograph for detection of interproximal caries in the permanent dentition: a systematic review and meta-analysis[J]. J Dent, 2020, 98: 103351. doi: 10.1016/j.jdent.2020.103351.

[89] Spagopoulos D, Michou S, Gizani S, et al. Fluorescence and near-infrared light for detection of secondary caries: a systematic review [J]. Dent J (Basel), 2023, 11(12): 271. doi: 10.3390/dj11120271.

[90] Cantu AG, Gehrung S, Krois J, et al. Detecting caries lesions of different radiographic extension on bitewings using deep learning [J]. J Dent, 2020, 100: 103425. doi: 10.1016/j.jdent.2020.103425.

[91] Pearl Inc. Pearl becomes first dental AI company to receive FDA clearance, CE mark, and health Canada approval[Z]. Pearl, 2022.

[92] He K, Zhang R, Liang M, et al. The application of deep learning in early enamel demineralization detection[J]. PeerJ, 2025, 13: e18593. doi: 10.7717/peerj.18593.

[93] Min JH. Validation of quantitative light-induced fluorescence digital analysis for assessing early dental caries depth: a micro-computed tomography-based *in vitro* study[J]. Dent J (Basel), 2025, 13(3): 90. doi: 10.3390/dj13030090.

[94] Kayali S, Golkari A, Mathur M. Artificial intelligence integrated with intraoral digital imaging in dental caries detection, treatment planning, and clinical decision-making: a scoping review[J]. F1000Research, 2026, 14: 1328. doi: 10.12688/f1000research.172671.2.

[95] Mertens S, Krois J, Garcia Cantu A, et al. Artificial intelligence for caries detection: randomized trial[J]. J Dent, 2021, 115: 103849. doi: 10.1016/j.jdent.2021.103849.

[96] Mendonça EA. Clinical decision support systems: perspectives in dentistry[J]. J Dent Educ, 2004, 68(6): 589-597.

[97] Schwendicke F, Samek W, Krois J. Artificial intelligence in dentistry: chances and challenges[J]. J Dent Res, 2020, 99(7): 769-774. doi: 10.1177/0022034520915714.

[98] Walsh T, Macey R, Riley P, et al. Imaging modalities to inform the detection and diagnosis of early caries[J]. Cochrane Database Syst Rev, 2021, 3(3): CD014545. doi: 10.1002/14651858.CD014545.

[99] Müller A, Mertens SM, Göstemeyer G, et al. Barriers and enablers for artificial intelligence in dental diagnostics: a qualitative study [J]. J Clin Med, 2021, 10(8): 1612. doi: 10.3390/jcm10081612.

[100] Ploug T, Sundby A, Moeslund TB, et al. Population preferences for performance and explainability of artificial intelligence in health care: choice-based conjoint survey[J]. J Med Internet Res, 2021, 23(12): e26611. doi: 10.2196/26611.

（编辑　罗燕鸿）

Open Access
This article is licensed under a Creative Commons Attribution 4.0 International License.
Copyright © 2026 by Editorial Department of Journal of Prevention and Treatment for Stomatological Diseases

官网