

Letter to Editor

Asian Pacific Journal of Tropical Medicine

apjtm.org

doi: 10.4103/apjtm.apjtm_615_25

Clinical and ultrasonographic correlates of viral load in pediatric Chikungunya: A retrospective analysis

Menglin Tan[1], Weixue Zhu[1], Xiaoqian Chen[1], Guangqiong Li[1], Kam Lun Ellis Hon[2], Alexander K. C. Leung[3], Suhua Jiang[1]✉

[1]*The First People's Hospital of Foshan (Foshan Hospital Affiliated to Southern University of Science and Technology), School of Medicine, Southern University of Science and Technology, Guangdong, China*

[2]*Department of Paediatrics, CUHK Medical Centre, The Chinese University of Hong Kong, Hong Kong SAR, China*

[3]*Department of Pediatrics, University of Calgary, Alberta, Canada*

Chikungunya virus (CHIKV) has re-emerged in Asia with increasing pediatric involvement, yet systematic data from mainland China remain limited. Global climate change has further facilitated the spread of *Aedes*-borne viruses in the Asia-Pacific region[1]. Although joint manifestations are well described in adults, pediatric patterns, especially those supported by imaging, are less commonly reported in China[2]. CT values offer a semi-quantitative indicator of viral replication[3], while ultrasonography is sensitive for detecting acute synovial inflammation[4]. However, few studies have integrated these indicators in children. Here, we briefly report clinical features, ultrasonographic findings, and virological correlates in 42 pediatric Chikungunya cases, representing one of the first integrated pediatric datasets from southern China.

This retrospective analysis included 42 laboratory-confirmed CHIKV infections admitted to Foshan First People's Hospital, Foshan, Guangdong, China, between July and August 2025. Similar to previous pediatric cohorts describing acute febrile rash illness[5,6], our inclusion criteria required laboratory confirmation by RT-PCR, and children with co-infections or rheumatologic disease were excluded. Demographic characteristics, clinical manifestations, laboratory parameters, CT values, and joint ultrasonography were retrieved from electronic medical records. Ultrasonography was performed within 72 h after admission by trained radiologists using a high-frequency (7-12 MHz) linear probe, consistent with recommended musculoskeletal imaging practices[4]. The institutional ethics committee of Foshan First People's Hospital approved this study [Approval No. Lunshenyan (2025) 220; July 11, 2025], and informed consent was obtained from guardians.

Among the 42 children [mean age, (10.2 ± 4.1) years; 23 boys], fever (95.2%) and rash (100%) were universal features, consistent with prior pediatric cohorts reporting near-universal exanthem[5,7]. Arthralgia occurred in 28 children (66.7%), typically mild to moderate (mean VAS: 2.6 ± 1.3), and most often involved the ankles and wrists. Table 1 summarizes demographic and clinical characteristics, including the distribution of joint involvement.

Table 1. Demographic and clinical characteristics of 42 children with Chikungunya fever.

Variable	Value
Age, years, mean ± SD	10.2 ± 4.1
Sex (boys), *n* (%)	23 (54.8)
Fever, *n* (%)	40 (95.2)
Duration of fever, days	2.3 ± 1.1
Rash, *n* (%)	42 (100.0)
Rash duration, days	4.9 ± 1.6
Arthralgia, *n* (%)	28 (66.7)
Arthralgia duration, days	2.8 ± 1.3
Distribution of joint involvement*	
Ankle	54.8%
Wrist	38.1%
Knee	19.0%
Fingers	14.3%
Elbow	7.1%
Toe	2.4%

*Joint involvement was not mutually exclusive; a patient could have involvement of more than one joint, so percentages may not sum to 100%.

Ultrasonography demonstrated abnormalities in 20/24 (83.3%) children with arthralgia, whereas none of the 14 cases without arthralgia showed abnormal findings (P<0.001). These results echo previous observations that CHIKV-related synovitis and effusion are prominent during the acute phase[4,8]. Lymph-node abnormalities were also more frequent in children with arthralgia (45.8% *vs.* 0%,

✉To whom correspondence may be addressed. E-mail: jsh20192019@163.com

This is an open access article distributed under the terms of the Creative Commons Attribution-Non-Commercial-No Derivatives License 4.0 (CCBY-NC-ND), where it is permissible to download and share the work provided it is properly cited. The work cannot be changed in any way or used commercially without permission from the journal.

For reprints contact: reprints@medknow.com

©2026 *Asian Pacific Journal of Tropical Medicine* Produced by Wolters Kluwer-Medknow.

How to cite this article: Tan M, Zhu W, Chen X, Li G, Hon KLE, Leung AKC, et al. Clinical and ultrasonographic correlates of viral load in pediatric Chikungunya: A brief report. Asian Pac J Trop Med 2026; 19(3): 141-142.

Article history: Received 25 October 2025 Revision 23 January 2026
Accepted 19 March 2026 Available online 24 March 2026

P=0.002), suggesting broader immune activation similar to that described in other pediatric reports[9].

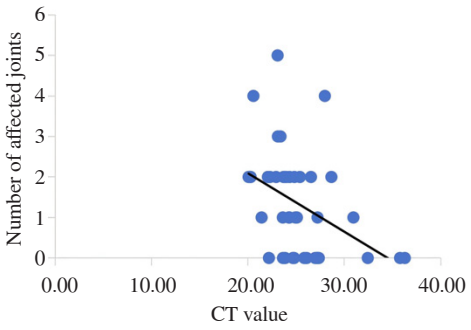

Figure 1. Correlation between viral CT values and cumulative number of affected joints in pediatric CHIKV infection (Spearman r=–0.47, P=0.002).

Importantly, CT values showed a significant negative correlation with the cumulative number of affected joints (Spearman r=–0.47, P=0.002), indicating that higher viral loads correspond to broader joint involvement (Figure 1). A similar relationship between viral load and musculoskeletal inflammation has been described in adult studies[8]. Figure 1 illustrates this association. Among the 16 children who underwent repeat testing before discharge, 62.5% achieved viral negativity within 3-5 days, while others showed rising CT values, indicating a reduction in viral activity during recovery.

This report has several limitations: it is a single-center retrospective study with a modest sample size, and not all children underwent ultrasonography. Cytokine or immunologic profiling was not performed, although previous research highlights distinct inflammatory pathways in pediatric Chikungunya, including IL-6 and TNF-α elevation[9]. Nevertheless, this brief report provides quantitative evidence linking viral load with ultrasonographic abnormalities in children. Integrating molecular markers with bedside ultrasonography may facilitate early risk identification and strengthen regional pediatric surveillance strategies where *Aedes*-borne viruses continue to expand[1,2].

In conclusion, pediatric Chikungunya in southern China is characterized by high frequencies of rash, fever, and arthralgia, with strong correspondence between symptoms, ultrasonographic abnormalities, and viral CT values. CT values may serve as early markers of inflammatory burden, supporting their integration into pediatric assessment frameworks in endemic regions.

Conflict of interest satement

The authors declare that there are no conflicts of interest.

Funding

The authors received no extramural funding for the study.

Authors' contributions

M.T. conceived and designed the study, collected the clinical data, performed the analysis, and drafted the manuscript. W.Z., X.C., and G.L. contributed to data collection and data curation, and assisted in data analysis and interpretation. K.L.E.H. and A.K.C.L. provided critical revision of the manuscript for important intellectual content. S.J. supervised the project and coordinated the study. All authors reviewed and approved the final version of the manuscript.

References

[1] Tjaden NB, Suk JE, Fischer D, Thomas SM, Beierkuhnlein C, Semenza JC. Modelling the effects of global climate change on Chikungunya transmission in the 21st century. *Sci Rep* 2017; **7**(1): 3813. doi: 10.1038/s41598-017-03566-3.

[2] Feng Y, Zhang H. Advances in epidemiology and vector biology of Chikungunya fever in China. *China Trop Med* 2025; **25**(5): 582-587.

[3] B SR, Patel AK, Kabra SK, Lodha R, Ratageri VH, Ray P. Virus load and clinical features during the acute phase of Chikungunya infection in children. *PLoS One* 2019; **14**(2): e0211036. doi: 10.1371/journal.pone.0211036.

[4] Blettery M, Brunier L, Banydeen R, Derancourt C, de Bandt M. Management of acute-stage chikungunya disease: Contribution of ultrasonographic joint examination. *Int J Infect Dis* 2019; **84**: 1-4. doi: 10.1016/j.ijid.2019.03.031.

[5] de Jesus Pereira B, Brasil MQA, Silva JJ, Cristal JR, Carvalho IP, Miranda MCP, et al. Chikungunya in a pediatric cohort: Asymptomatic infection, seroconversion, and chronicity rates. *PLoS Negl Trop Dis* 2025; **19**(7): e0013254. doi: 10.1371/journal.pntd.0013254.

[6] Naik KD, Delhi Kumar CG, Abimannane A, Dhodapkar R, Biswal N. Chikungunya infection in children: Clinical profile and outcome. *J Trop Pediatr* 2024; **71**(1): fmae057. doi: 10.1093/tropej/fmae057.

[7] Hoarau JJ, Jaffar Bandjee MC, Krejbich Trotot P, Das T, Li-Pat-Yuen G, Dassa B, et al. Persistent chronic inflammation and infection by Chikungunya arthritogenic alphavirus in spite of a robust host immune response. *J Immunol* 2010; **184**(10): 5914-5927. doi: 10.4049/jimmunol.0900255.

[8] Benjamanukul S, Osiri M, Chansaenroj J, Chirathaworn C, Poovorawan Y. Rheumatic manifestations of Chikungunya virus infection: Prevalence, patterns, and enthesitis. *PLoS One* 2021; **16**(4): e0249867. doi: 10.1371/journal.pone.0249867.

[9] Beserra FLCN, Oliveira GM, Marques TMA, Farias LABG, Santos JRD, Daher EF, et al. Clinical and laboratory profiles of children with severe chikungunya infection. *Rev Soc Bras Med Trop* 2019; **52**: e20180232. doi: 10.1590/0037-8682-0232-2018.

Publisher's note

The Publisher of the *Journal* remains neutral with regard to jurisdictional claims in published maps and institutional affiliations.

Edited by Zhang Q, Lei Y, Pan Y