[DOI]10.12016/j.issn.2096-1456.202550569

·综述·

口腔潜在恶性疾患癌变预防新进展

张雅洁，　孙婉昕，　但红霞
口腔疾病防治全国重点实验室 国家口腔医学中心 口腔疾病国家临床医学研究中心 中国医学科学院口腔黏膜癌变与防治创新单元 四川大学华西口腔医院口腔黏膜病科，四川成都(610041)

【摘要】 口腔潜在恶性疾患(oral potentially malignant disorders，OPMDs)是一组具有不同形态特征的口腔黏膜疾病，可能发展为口腔鳞状细胞癌(oral squamous cell carcinoma，OSCC)。流行病学研究表明，全球约4.67%的人口可能患有OPMD，Meta分析结果显示OPMD患者进展为OSCC的风险是正常人群的2.5倍。OPMD发展为OSCC的过程复杂，其发生发展受吸烟、饮酒、咀嚼槟榔、口腔微生物等危险因素驱动，并涉及遗传变异、表观遗传修饰与肿瘤微环境失调的复杂交互。在分子机制层面，基因组杂合性缺失与关键信号通路的级联失调构成上皮癌变的内在基础，而免疫抑制性微环境的建立，包括M2巨噬细胞极化、程序性死亡配体1介导的免疫逃逸及口腔微生物的促癌作用等则为癌变提供了关键的外部支持。尽管已有药物治疗、手术治疗、光动力治疗等多种治疗方法被用于OPMD的癌变预防，但目前还没有公认的可明确预防OPMD癌变的有效手段。近年来，人工智能技术通过整合临床、病理及分子多维数据，在OPMD癌变风险预测方面展现出良好的性能，为推动个体化风险分层与精准随访管理等方面提供了新的决策支持工具。本文对OPMD癌变预防新进展进行综述，以期为OPMD的临床管理提供参考。

【关键词】 口腔潜在恶性疾患；　口腔白斑；　口腔扁平苔藓；　口腔黏膜下纤维性变；　癌变；　手术治疗；　激光治疗；　冷冻治疗；　光动力治疗；　人工智能
【中图分类号】 R78　**【文献标志码】** A　**【文章编号】** 2096-1456(2026)08-0799-13
【引用著录格式】 张雅洁，孙婉昕，但红霞. 口腔潜在恶性疾患癌变预防新进展[J]. 口腔疾病防治，2026，34(8)：799-811. doi:10.12016/j.issn.2096-1456.202550569.

微信公众号

Advances in the prevention of malignant transformation of oral potentially malignant disorders

ZHANG Yajie, SUN Wanxin, DAN Hongxia.　State Key Laboratory of Oral Diseases & National Center for Stomatology & National Clinical Research Center for Oral Diseases & Research Unit of Oral Carcinogenesis and Management, Chinese Academy of Medical Sciences & Department of Oral Medicine, West China Hospital of Stomatology, Sichuan University, Chengdu 610041, Sichuan China
Corresponding author: DAN Hongxia, Email: danhx@scu.edu.cn

【Abstract】 Oral potentially malignant disorders (OPMDs) are a group of oral mucosal diseases with different morphological characteristics that have an increased risk of progressing to oral squamous cell carcinoma (OSCC). Epidemiological studies indicate that approximately 4.67% of the global population may have an OPMD, and meta-analysis results show that the risk of progression to OSCC in patients with OPMD is 2.5 times that of the general population. The progression of an OPMD to OSCC is a complex process driven by risk factors including smoking, alcohol consumption, betel quid chewing, and oral microbiota. It is characterized by intricate interactions among genetic alterations, epigenetic modifications, and dysregulation of the tumor microenvironment. At the molecular level, the intrinsic basis of epithelial carcinogenesis is established by genomic loss of heterozygosity and cascading dysregulation of critical signaling pathways, while crucial external support for malignant transformation is provided by the immunosuppressive microenvi-

【收稿日期】2025-12-10；　**【修回日期】**2026-05-26
【基金项目】国家自然科学基金面上项目(82370965, 82571090)；四川省护理学会护理科研课题(H24016)
【作者简介】张雅洁，医师，硕士研究生在读，Email：1269464144@qq.com；孙婉昕，主管护师，学士，Email: 672062322@qq.com
【通信作者】但红霞，教授，博士，Email：danhx@scu.edu.cn

ronment, including M2 macrophage polarization, immune evasion mediated by programmed death-ligand 1, and the protumorigenic effects of oral microbiota. Although a variety of therapeutic modalities (e.g., pharmacotherapy, surgical treatment, and photodynamic therapy) have been employed for the prevention of OPMD malignant transformation, no universally accepted treatment has been proven to completely eradicate the risk of cancer development at present. In recent years, artificial intelligence technologies have demonstrated promising performance in predicting the malignant transformation risk of OPMD by integrating multi-dimensional clinical, pathological, and molecular data, thereby providing new decision-support tools for advancing individualized risk stratification and precise follow-up management. This review summarizes recent advances in the prevention of OPMD malignant transformation, with the aim of offering a reference for the clinical management of OPMDs.

【Key words】 oral potentially malignant disorder; oral leukoplakia; oral lichen planus; oral submucous fibrosis; carcinogenesis; surgical treatment; laser therapy; cryotherapy; photodynamic therapy; artificial intelligence

J Prev Treat Stomatol Dis, 2026, 34(8): 799-811.

口腔潜在恶性疾患(oral potentially malignant disorders,OPMDs)是一组具有不同形态特征的口腔黏膜疾病,部分病例可能会发展为口腔鳞状细胞癌(oral squamous cell carcinoma,OSCC)。OPMD可累及口腔中的任何解剖部位,可单发或多发,病损可表现为口腔黏膜的颜色、形态和质地的变化,患者可出现不同程度的粗糙感、木涩感、刺激痛和自发痛等症状。流行病学研究表明,OPMD的总体患病率约为4.67%[1],不同OPMD的癌变风险差异较大,一项Meta分析结果显示OPMD患者进展为OSCC的风险是正常人群的2.5倍[2]。较高的患病率与明确的癌变风险,对OPMD的早期识别、风险分层及规范化管理提出了迫切要求。

目前,OPMD的诊断方法较为明确,部分疾病通过典型临床表现即可诊断,部分疾病需结合组织病理学检查进行诊断,少数疾病需基因检查方能确诊,总体诊断方法相对明确。然而,诊断明确并不意味着临床管理问题已经解决。由于OPMD病因复杂、发病机制异质性强,目前尚无能够彻底根除病变并完全阻断癌变进程的干预手段。现有治疗主要以缓解症状、控制病损进展、降低复发风险及阻断或延缓癌变为目标,但不同治疗策略在降低癌变率方面的证据等级并不一致。因此,OPMD癌变预防不能仅依赖单一治疗手段,而需要在明确诊断的基础上,综合开展癌变风险评估、规范化治疗、长期随访监测及动态管理。近年来,随着OPMD相关临床研究、分子机制研究及人工智能辅助诊疗技术的发展,OPMD癌变预防正面临新的机遇与挑战。基于此,本文将围绕OPMD的新分类及临床流行病学特征、发生发展的分子机制、癌变预防策略的效果,以及人工智能在OPMD癌变预防中的应用进行综述,以期为OPMD癌变预防和规范化临床管理提供参考。

1　OPMD的分类及临床流行病学特征

在2021年WHO口腔癌协作中心发布的共识中,OPMD被定义为“任何具有显著升高的癌变风险的口腔黏膜异常”,包含口腔白斑病(oral leukoplakia,OLK)、口腔红斑病(oral erythroplakia,OE)、口腔扁平苔藓(oral lichen planus,OLP)、增殖性疣状白斑(proliferative verrucous leukoplakia,PVL)、口腔黏膜下纤维性变(oral submucous fibrosis,OSF)、光化性唇炎(actinic cheilitis,AC)、倒吸烟相关的腭部损害(palatal lesions in reverse smokers)、口腔红斑狼疮(oral lupus erythematosus,OLE)、先天性角化不良(dyskeratosis congenita,DC)、口腔苔藓样损害(oral lichenoid lesion,OLL)和口腔移植物抗宿主病(oral graft versus host disease,OGVHD)[3]。不同类型OPMD的流行病学特征详见表1。

2　OPMD发生发展的分子机制

从正常口腔黏膜到OPMD再到OSCC的发展过程受到多种风险因素的共同影响。其中,吸烟、咀嚼槟榔、白色念珠菌感染及人乳头瘤病毒感染等是相对公认的经典风险因素。近年来,研究者进一步发现,口腔其他细菌的定植、宿主遗传易感性以及免疫微环境失调等因素也与OPMD的癌变风险密切相关[28-30]。OPMD向OSCC的恶性转化是多因素、多阶段、多机制交织的复杂生物学过程,其核心病理特征表现为基因组不稳定性累积、关键

表1　OPMD的分类及临床流行病学特征

Table 1　Classification and clinical epidemiological characteristics of OPMD

Type of disease	High-risk population	Prevalence rate	Malignant transformation rate
Oral leukoplakia	Middle-aged and older men[4]	3.41%[4]	8.4%[5]
Oral erythroplakia	Middle-aged and older women [6]	0.04%-1.14%[7]	50.0%[5]
Oral lichen planus	Middle-aged and older women[8]	1.01%[9]	1.6%[8]
Proliferative verrucous leukoplakia	Middle-aged and older women[10]	Not reported	48%[11]
Oral submucous fibrosis	Middle-aged and older men[12]	3.0%[12]	4.2%-6%[13]
Actinic cheilitis	Outdoor workers[14-15]	2.48%[1]	14%[16]
Palatal lesions in reverse smokers	Older women[17]	5.8%[a][18]	Not reported
Oral lupus erythematosus	Middle-aged and older women[19]	Not reported	10%[20]
Dyskeratosis congenita	Infants and young children[21-22]	Rare[21-22]	40%-50%[23]
Oral lichenoid lesion	Not reported	Not reported	1.88%-3.80%[24]
Oral graft versus host disease	Patients received allogeneic hematopoietic stem cell transplantation[25]	40.2%[b][26]	3.7%[c], 32.1%[d][27]

a: limited to specific populations. b: limited to patients who have received allogeneic hematopoietic cell transplantation. c: patients with a disease duration < 15 months. d: patients with a disease duration ≥ 15 months. OPMD: oral potentially malignant disorder

信号通路级联失调、免疫抑制微环境建立、基质重塑及微生物失调。这些分子事件相互协同，最终突破上皮基底膜屏障，完成从OPMD到OSCC的演进[31]。

2.1　基因组不稳定性累积

在基因组层面，染色体拷贝数变异与杂合性缺失（loss of heterozygosity，LOH）是癌变起始的核心驱动力[32-33]。染色体拷贝数变异被证明随着口腔异常增生的程度增加而增加[32]。超过半数OPMD患者存在9p21和3p14位点的LOH，此类患者癌变风险显著升高[34]；而17p13位点的LOH进一步加剧基因组不稳定性，导致DNA损伤修复功能障碍[35]。

2.2　关键信号通路级联失调

在上述基础上，上皮细胞内多条核心信号通路的级联失调为克隆性扩增提供内在动力：p53蛋白（p53 protein）通路失活导致DNA损伤修复缺陷与凋亡受阻[36]；$p16^{INK4a}$-Cyclin D1-CDK4/6-Rb轴失活，表现为细胞周期蛋白依赖性激酶4抑制因子a的蛋白产物$p16^{INK4a}$沉默、细胞周期蛋白D1（cyclin D1）过表达，推动细胞无序通过G1/S检查点[37-38]；PI3K/AKT/mTOR通路因第10号染色体上缺失的磷酸酶及张力蛋白同源物（phosphatase and tensin homolog deleted on chromosome ten，PTEN）功能丧失或微小RNA-21（microRNA-21，miR-21）过表达而异常激活，提供抗凋亡信号与代谢支持[39-42]；Wnt/β-连环蛋白信号通路（Wnt/β-catenin pathway）激活导致β-连环蛋白（β-catenin）核内积聚，启动MYC原癌基因（MYC proto-oncogene，MYC）、CCND1等促增殖靶基因转录，赋予细胞干细胞样表型[43-47]。O6-甲基鸟嘌呤-DNA甲基转移酶基因（O6-methylguanine-DNA methyltransferase gene，MGMT）、死亡相关蛋白激酶基因（death-associated protein kinase gene，DAPK）和E-钙黏蛋白基因（E-cadherin gene，ECAD）等抑癌基因启动子高甲基化是口腔上皮异常增生早期事件的核心驱动因素[48]。上皮结构完整性的早期破坏是OPMD癌变的关键环节，分区缺陷蛋白3（partitioning defective 3 homolog，PAR3）、scribbled平面细胞极性蛋白（scribbled planar cell polarity protein，SCRIBBLE）和肝癌上调蛋白在口腔上皮异常增生中表达显著下调[49]；CK2-PA28γ-pT23-E4F1轴异常激活下调E4F转录因子1（E4F transcription factor 1，E4F1）的蛋白丰度，解除其对细胞周期蛋白A2（cyclin A2）的抑制，推动细胞异常增殖，且该事件在正常黏膜到OLK到OSCC进程中呈渐进性增强趋势[50]。

2.3　免疫抑制微环境建立

近期Yang等[31]关于癌前病变的信号通路与靶向干预的综述提出肿瘤微环境（tumor microenvironment，TME）的“土壤退化”是决定OPMD命运的关键外部因素。在免疫微环境层面，OPMD细胞表面程序性死亡配体1（programmed death-ligand 1，PD-L1）表达上调，通过与T细胞PD-1结合抑制细胞毒性T淋巴细胞活性，介导免疫逃逸[30]，而抗PD-1抗体在部分高危增殖性疣状白斑患者中取得临床缓解，证实了该机制的核心作用[51]。$TDO2^{+}$肌成纤维

细胞通过TDO2-AhR轴介导T细胞免疫抑制，在癌巢外围构筑“免疫陷阱”[52-53]；肿瘤相关巨噬细胞（tumor-associated macrophages，TAMs）向M2表型极化[54-55]，通过分泌白细胞介素-10（interleukin-10，IL-10）、转化生长因子-β（transforming growth factor-β，TGF-β）及表达PD-L1塑造免疫抑制微环境[56-59]。免疫抑制网络呈现高度细胞多样性与功能协同性。髓源性抑制细胞（myeloid-derived suppressor cells，MDSCs）在OPMD中大量浸润，通过抑制T细胞功能参与免疫抑制微环境的建立[60-61]。树突状细胞（dendritic cells，DCs）在OPMD阶段出现PD-L1上调，导致抗原提呈能力下降[62]；调节性B细胞（regulatory B cells，Bregs）可通过分泌TGF-β等诱导调节性T细胞（regulatory T cells，Tregs）扩增，而Tregs与$CD8^+$T细胞共存并协同营造免疫抑制微环境，加速免疫逃逸和癌变进展[30,63-65]；肥大细胞通过释放血管内皮生长因子（vascular endothelial growth factor，VEGF）等促进血管生成[66]。此外，细胞毒性T淋巴细胞相关抗原4、V结构域免疫球蛋白T细胞激活抑制因子等多个免疫检查点分子在Tregs、M2巨噬细胞及MDSCs表面协同表达，共同构建“免疫抑制生态系统”[67-69]。

2.4　基质重塑及微生物失调

在基质成分层面，癌相关成纤维细胞（cancer-associated fibroblasts，CAFs）不仅促进上皮-间充质转化（epithelial-mesenchymal transition，EMT），还招募Tregs和MDSCs强化免疫抑制[52,70-73]；衰老成纤维细胞在OPMD和OSCC基质中积聚，在TME中发挥促癌作用[74-75]。口腔微生物失调可直接参与癌变：具核梭杆菌通过CXCL2介导的OSCC细胞与巨噬细胞之间的交互作用，推动OSCC进展[76]，牙龈卟啉单胞菌通过增强$CD4^+$T细胞浸润、抑制$CD8^+$T细胞功能，诱导OSCC局部免疫抑制微环境形成[77]。

综上，OPMD癌变是“种子”（基因突变的上皮细胞）与“土壤”（退化的微环境）协同演变的生态系统过程。上皮内驱动通路激活、细胞极性破坏及蛋白酶体调控轴异常构成内在基础，而免疫抑制建立、基质重塑及微生物失调提供外部支持。这些多层次机制相互反馈、强化，共同推动病变从轻度不典型增生向浸润癌演进[31]（图1）。未来干预策略需从单一靶点转向“生态系统重建”，同时靶向上皮驱动突变、退化微环境及两者间交互对话。

3　OPMD癌变预防策略的效果

目前OPMD的癌变预防策略主要包括非手术治疗和手术治疗，其中非手术治疗主要包括主动监测、化学预防、激光治疗、冷冻治疗和光动力治疗。

3.1　主动监测

在OPMD的癌变预防体系中，主动监测是一种重要的临床管理策略，该策略并非被动等待，而是通过定期、严格的临床和组织学监测进行主动动态管理，旨在早期识别癌变征象以便及时干预。近期一项来自于瑞典的回顾性研究（n=739）显示，定期随访监测能显著改善预后，定期随访组在癌变时诊断分期更早，5年净生存率高达90.0%，显著高于未定期随访组[78]。主动监测策略还融合了积极的生活方式干预，如戒烟、戒酒、戒除槟榔及饮食调整（如增加抗氧化食物摄入），并借助组织活检、自体荧光光谱分析、甲苯胺蓝染色、窄带成像等辅助技术提高监测准确性。主动监测主要适用于低风险或无法耐受积极治疗的患者，但其局限性在于本身不能阻止癌变，因此，应当积极关注OPMD病损的动态变化，若在监测过程中发现OPMD病损的癌变风险升高，例如均质型变为非均质型、上皮异常增生程度升高等，仍应采取积极的治疗措施以预防癌变。

3.2　化学预防

化学预防被定义为使用合成、天然药物或生物制剂来预防、抑制或逆转癌变进程[79]。该策略旨在拦截口腔上皮改变，以抑制其癌变，是OPMD管理中的重要组成部分。

各类药物可通过不同机制阻止OPMD的癌变进程。维甲酸类药物（如异维A酸）通过结合特定受体调节基因转录，抑制生长并诱导细胞分化[80]。局部应用维甲酸类药物可在部分患者中实现病损面积缩小或完全缓解[81]。类胡萝卜素（如β-胡萝卜素、番茄红素）与多种癌症的风险呈负相关，番茄红素的抗氧化活性和非氧化作用，包括抗增殖、细胞死亡诱导、调节致癌物代谢酶和免疫调节，使其成为一种有潜力的抗癌药物[82-84]，研究表明接受8 mg/d或4 mg/d口服番茄红素治疗的OLK患者表现出明显的临床和组织学改善[81]。口服β-胡萝卜素（360 mg/周×12个月）后OLK的完全消退率为33%[81]。含有10%冻干黑树莓的生物粘附凝胶能导致病灶显著临床消退和组织学分级降低，且不良反应轻微[81]。姜黄素（3.6 g/d）在OLK治疗中也

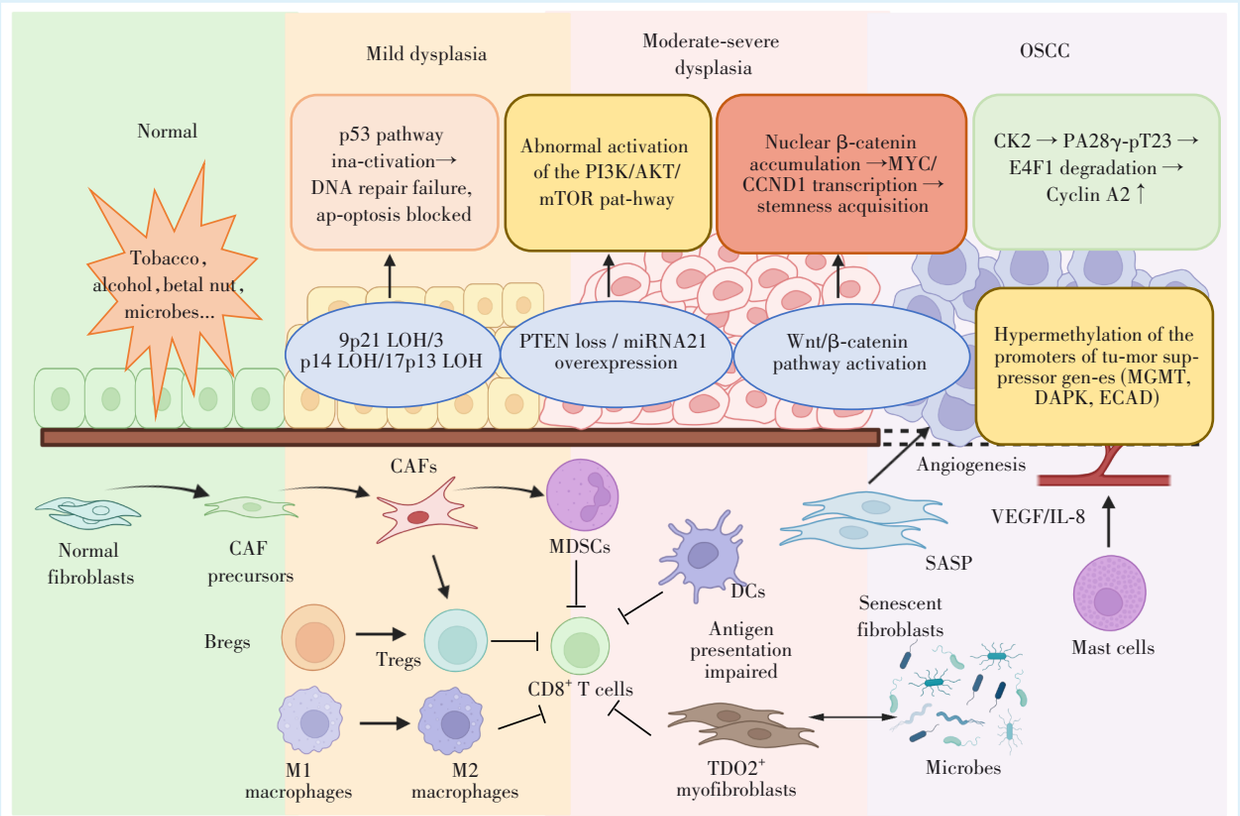

p53: tumor protein p53; PI3K: phosphoinositide 3-kinase; AKT: protein kinase B; mTOR: mammalian target of rapamycin; MYC: MYC proto-oncogene; CCND1: cyclin D1; CK2: casein kinase 2; PA28γ: proteasome activator subunit 28 gamma; E4F1: E4F transcription factor 1; LOH: loss of heterozygosity; PTEN: phosphatase and tensin homolog; miRNA-21: microRNA-21; Wnt: wingless-related integration site; MGMT: O-6-methylguanine-DNA methyltransferase; DAPK: death-associated protein kinase; ECAD: E-cadherin; SASP: senescence-associated secretory phenotype; VEGF: vascular endothelial growth factor; CD: cluster of differentiation; IL-8: interleukin-8; TDO2: tryptophan 2,3-dioxygenase; CAF: cancer-associated fibroblast; Bregs: regulatory B cells. OPMD: oral potentially malignant disorder. Generated with BioRender

Figure 1　Molecular mechanisms of the development and malignant transformation of OPMD

图1　OPMD发生发展的分子机制

显示出67.5%的临床响应率,但伴有贫血、高血压等不良反应[81]。在靶向代谢通路方面,一项Ⅱa期试验结果显示(NCT02581137),口服二甲双胍12周可使60%的OLK或OE患者获得组织病理学改善[85]。而在免疫调节方面,另一项Ⅱ期试验(NCT03692325)证实,PD-1抑制剂纳武利尤单抗能使36.7%的难治性PVL患者达到显著的临床缓解[51]。然而,尽管上述部分药物在减轻症状、缩小病灶和改善异常增生程度等方面显示出一定效果,但迄今仍缺乏令人信服的证据表明任何化学预防药物能显著降低OPMD的癌变风险[81]。

鉴于传统化学预防药物疗效的局限性,目前该领域的研究重点已转向针对OPMD分子发病机制的精准干预。其核心机制涉及免疫微环境失调、关键信号通路异常激活及炎症调控,据此涌现出多个极具潜力的分子靶点。目前,已有部分动物实验研究揭示了免疫检查点抑制剂、铁死亡诱导剂、表皮生长因子受体(epidermal growth factor receptor, EGFR)靶向药物、mTOR抑制剂等在OPMD癌变预防方面的潜力[40,86-89],但未来仍需进一步的临床研究对其预防效果进行验证。

3.3　激光治疗

激光治疗是管理OPMD的常用方法之一,其应用涉及多种类型的激光,如二氧化碳(CO_2)激光、掺钕钇铝石榴石(Nd:YAG)激光、半导体激光等。与传统手术相比,激光具有创伤小、出血少、术后肿胀和瘢痕较少的优点,且可通过对手术部位的消毒降低细菌感染的风险。

然而,激光治疗也存在明显的局限性。尽管一项Meta分析显示,CO_2激光治疗相比其他治疗方

式的复发率更低，比值比为0.36（95% *CI*：0.12~1.04）[90]，但差异无统计学意义（$P = 0.06$）。目前不同文献报道的复发率范围较大[90-91]，甚至有研究报道18个月内复发率高达54.17%[92]。一篇纳入36项研究共5 051例病损的Meta分析指出，激光治疗OLK的总体癌变率为5.2%[93]。由于多数研究并未设置对照组，与其他治疗方式相比较，激光治疗在预防OPMD癌变方面的有效性尚不确切。

3.4　冷冻治疗

冷冻治疗的基本原理是利用极低的温度将细胞内外的液体迅速冻结，从而原位破坏病变组织原有细胞结构。冷冻治疗具有操作简单、安全、省时、出血量低、继发感染率低、术后疼痛轻微，且不易产生瘢痕等优点[94]。Yu等[95]对60处OLK病损行冷冻疗法后，所有病损均完全消退。

然而，冷冻治疗也存在明显的局限性。尽管短期缓解率高，但Meta分析结果显示，冷冻治疗后OLK的复发率高达21%[96]。一项回顾性研究显示，对72例OLK患者（包括8例中重度异型增生）进行冷冻治疗后，在平均18个月的随访期内，所有病例均未发生癌变[97]。然而，另一项回顾性研究发现，对OLK病损进行冷冻治疗后的癌变率（25%）或冷冻联合手术治疗的癌变率（25%）比单独手术切除后的癌变率（1.3%）更高[98]，但由于该研究不同组别之间临床病理参数的基线数据并不一致，无法排除混杂因素的影响。因此，尽管冷冻治疗对OLK的短期有效率高，但由于缺乏充分的临床研究证据，其预防OPMD癌变的有效性仍有待进一步验证。

3.5　光动力治疗

光动力疗法（photodynamic therapy，PDT）是一种基于光敏剂介导的光化学、光生物学反应，对病变细胞产生杀伤作用的治疗方法。其基本要素主要包括光敏剂、氧气和光。在特定波长光的照射下，光敏剂从基态跃迁至激发态，再与附近分子和氧发生电子或能量转移，生成多种活性氧（reactive oxygen species，ROS），直接发挥细胞毒性作用；也可通过血管毒性作用引起组织缺氧和营养枯竭，间接杀伤靶组织；还可通过激发炎症和非特异性/特异性免疫反应引起组织损伤[88]。

PDT在OPMD的临床管理中展现出显著优势：微创、操作相对简单、术后疼痛轻微，能较好地保持口腔颌面部的美观和功能，可同时处理多灶性病变，且具有可重复性。Meta分析显示，PDT治疗OPMD的完全缓解率和总有效率分别为60.6%和93.7%[99]。然而，PDT也存在局限性，如：部分患者存在治疗抵抗，单个病损常需多次治疗，治疗后可能复发等。

由于多数研究的样本例数较少，观察时间较短，仅少数研究报告了PDT治疗后OPMD的癌变率，且由于缺乏对照，难以评估PDT对OPMD癌变风险的影响。近期本课题组的回顾性队列研究表明，完成完整PDT疗程可显著降低OLK的癌变风险，对于女性及无吸烟、饮酒习惯的患者保护作用更显著[100]。尽管部分患者可能存在治疗抵抗，但通过对高角化病损进行激光预处理，可促进光敏剂渗透，提高治疗效率并有效防止复发[101]。上述研究提示PDT在OPMD癌变预防方面极具潜力，未来尚需开展前瞻性多中心长周期临床研究对PDT的癌变预防效果进行验证。

3.6　手术治疗

目前，手术治疗仍然是OPMD的常用干预措施。手术治疗能对整个标本进行组织病理学检查，有助于发现活检切取可能遗漏的微小癌灶，从而实现对癌变的早期诊断。但手术治疗能否降低OPMD的癌变风险尚存在争议。Mehanna等[102]的Meta分析表明手术切除可能降低伴有异常增生的OPMD的癌变风险。但也有研究认为手术无法降低癌变风险[103]。与此同时，手术治疗的局限性同样突出且证据充分。其最显著的弊端是高复发率，文献报道手术切除后OLK的复发率约27%[104]，对于PVL等特殊类型，传统手术后的复发率甚至高达100%[105]。更重要的是，手术无法保证完全防止癌变，研究显示，手术组在平均19个月的随访期内癌变率为1.2%，且术后OLK复发率高达20%[106]，其原因包括："区域癌化"效应、持续暴露于危险因素（如烟、酒、槟榔等）、高危黏膜的固有易感性以及未能完全切除所有具有癌变潜能的细胞[11,107-108]。此外，手术本身会带来出血、瘢痕挛缩和功能障碍等并发症。病损面积较大时，常需从身体其他部位切取皮瓣或肌皮瓣进行修复，造成供体部位的组织缺损和功能障碍，多次手术后的组织纤维化还会使后续监测变得更加复杂。在中华口腔医学会近年来发布的一系列OPMD诊疗指南/专家共识中，手术治疗主要被推荐用于病损较为局限的、具有高癌变风险的以及已经发生癌变的OPMD的治疗[109-111]。此外，手术治疗还适用于导致严重功能障碍的OPMD，如OSF引起的重度张

口受限[112]。最后，对于部分经非手术治疗无效、迁延不愈或反复发作的顽固性病损，在充分评估利弊后，手术也可作为控制病情发展的选择[109]。

3.7　OPMD癌变预防策略的选择

由于目前尚无确切证据证实上述任何一种策略能够完全预防癌变，在进行临床决策时往往需要结合患者的临床病理参数、全身状况、不同策略的优缺点和患者的个人意愿等因素综合考虑（图2）。

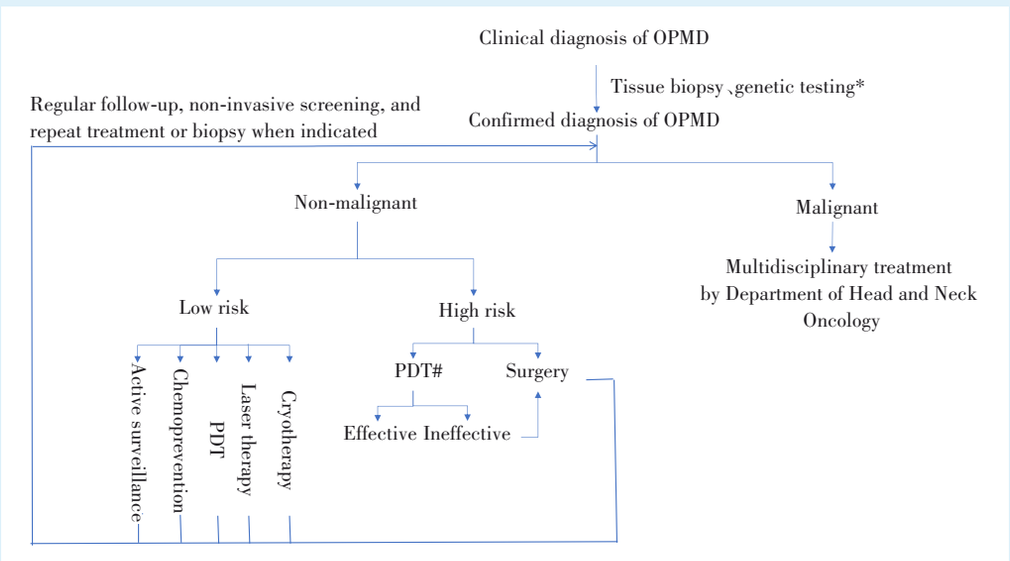

DC: dyskeratosis congenita; OPMD: oral potentially malignant disorder; PDT: photodynamic therapy. *: DC requires genetic testing for confirmation. #: conditional use

Figure 2　Strategies for preventing malignant transformation of OPMD

图2　OPMD癌变预防策略

4　人工智能在OPMD癌变预防中的应用

在OPMD癌变预防的临床实践中，临床决策的基础是准确的临床和病理诊断和对癌变风险的准确评估，这在很大程度上依赖于临床和病理医生的经验，难以向基层医院推广。为了解决上述难题，近年来，研究者对人工智能在OPMD癌变预防中的应用也进行了积极探索，已有研究主要集中于OPMD临床和病理辅助诊断、癌变风险和疗效预测等方面。从技术演进的角度来看，该领域正从“诊断识别”向“风险预测”、“预后预测”及“治疗决策支持”扩展，同时为解决基层医院诊断经验不足的问题提供了新的技术路径[113]。

多种人工智能模型已应用于该领域，包括卷积神经网络、生成对抗网络、贝叶斯深度神经网络以及注意力机制与可解释网络等。人工智能在OPMD辅助诊断中应用最为广泛，涉及OLK、OLP等常见或高癌变风险疾病的识别[114]，以及早期OSCC的诊断。训练数据来源多样，包括临床照片、HE染色切片、免疫组化切片及自体荧光图像等。在早期OSCC诊断方面，现有Meta分析显示人工智能表现出优越性能，其中，基于卷积神经网络与数码相机摄影的诊断模型取得了目前最高的准确率[115]。随着研究深入，人工智能在OPMD辅助诊断中的任务日趋精细化。最近，Feng等[116]提出“OLK进展识别”新任务，将病变分为正常、OLK、OLK癌变三类，其开发的OLPNet网络在外部验证中F1分数达90.63%，显著优于传统二分类模型。此外，Araújo等[117]采用YOLOv11与MobileNetV2两步法流程，先定位病变区域再分类，外部验证准确率达86.3%、受试者工作特征曲线下面积（area under the curve，AUC）为93.4%，更贴近基层医生诊断逻辑，降低了应用门槛。

人工智能与病理组织切片的结合是另一重要方向。过去有研究集中于通过病理切片训练模型进行上皮异常增生分级[118]，然而，由于该分级主观性强且对癌变风险预测能力有限，目前的研究重点逐渐转向多维度数据分析。如今，深度学习模型不仅能自动识别组织形态特征，还可预测基

因突变、人乳头瘤病毒状态及治疗反应，展现出开发“数字生物标志物”的潜力[119]。该领域最新突破来自Transformer架构在病理切片中的应用。最近，Shephard等[120]提出了口腔异型增生网络模型（oral dysplasia network，ODYN），该模型基于Transformer架构分析全切片图像，既能准确区分增生异常与非异常（F1分数达0.96），又能直接预测癌变风险，为客观评估癌变风险、减少病理医生经验差异提供了新工具。在OPMD的预后预测方面，人工智能模型通过整合组织病理特征、临床流行病学数据及免疫组化蛋白表达等多维度信息，显著提升了癌变风险评估的准确性。目前，多维度数据驱动的人工智能预测模型已逐渐成为研究热点，其中如香港大学Adeoye等[121]开发的OralCancerPredict模型，其预测性能已显著超越传统的异常增生分级系统。该团队基于366例患者的回顾性队列，开发了多任务人工智能模型，可同时预测手术切除后OPMD的治疗失败、癌变及复发三种结局，外部测试中AUC分别为0.829、0.912和0.791，净收益显著优于WHO分级及传统上皮异常增生分级系统，展现了更高的临床决策价值[121]。此外，香港大学已于2025年4月将该模型投入临床实际应用，开设了全球首个口腔癌人工智能诊所，OralCancerPredict作为核心工具用于患者风险分层（高风险推荐手术干预，低风险进行观察随访），据新闻报道其平均准确率达94%[122]。类似的模型正不断涌现，能够为临床判断OPMD是否需手术干预提供更为客观、精准的参考依据。

目前人工智能在OPMD癌变预防中的发展方向正从“辅助诊断”迈向“动态监测与个性化风险管理”。研究者呼吁未来人工智能系统应具备处理时间序列图像的能力，融合临床照片、光学相干断层扫描、自体荧光及分子生物标志物等多模态数据，生成比单一模态更可靠的诊断结论。同时，“人机协同”模式正逐步取代“完全自动化”，即人工智能提供可解释判断依据（如热力图），临床医生在此基础上做出最终决策，既保留了医生的主体性，又有效弥补了其经验不足的短板。

5　总结与展望

OPMD的发生和发展是一个多因素、多步骤的复杂过程，是多个内在与外在因素相互作用的动态演进结果。目前尚无确切证据证实传统治疗如手术切除与化学预防、激光治疗和冷冻治疗等能够有效预防OPMD癌变。虽然已有单中心临床队列研究提示PDT能够降低OLK的癌变风险，但仍需要开展前瞻性、多中心、大规模、长周期临床队列研究在其他人群以及其他类型OPMD中进行进一步验证。此外，通过对影响OPMD发生发展的关键分子进行深度解构，并以此为基础进行分子分型和靶向策略研发，在人工智能辅助下对高风险患者进行积极干预，或将有助于推动阻断OPMD癌变进程这一目标的实现。

【Author contributions】 Zhang YJ performed the literature search and wrote the manuscript. Sun WX assisted with literature screening and data extraction and revised the manuscript. Dan HX conceptualized the topic and revised the manuscript. All authors read and approved the final manuscript as submitted.

【Ethics Statement】 The authors have nothing to report.

【Funding】 This study was supported by the grants from National Natural Science Foundation of China General Program (No. 82370965, No. 82571090) and Sichuan Nursing Association Nursing Research Project (No. H24016). The funder had no role in the study design, data collection and analysis, decision to publish, or preparation of the manuscript.

【Competing interests】 All authors have completed the ICMJE uniform disclosure form at www.icmje.org/disclosure-of-interest/ and declare: support from National Natural Science Foundation of China General Program (No. 82370965, No. 82571090) and Sichuan Nursing Association Nursing Research Project (No. H24016) for the submitted work; no financial relationships with any organisations that might have an interest in the submitted work in the previous three years; no other relationships or activities that could appear to have influenced the submitted work.

【Data availability statement】 Data sharing is not applicable to this article as no datasets were generated or analyzed during the current study.

【Generative AI statement】 Figures in this manuscript were created with BioRender. The authors reviewed and edited the output and take full responsibility for the figures. No other Generative AI technology was used in the creation of this manuscript.

参考文献

[1] Lonni N, Rosa TS, Pereira CK, et al. Global prevalence of oral potentially malignant disorders: an updated systematic review and meta-analysis[J]. J Oral Pathol Med, 2026. doi: 10.1111/jop.70146.

[2] Khodadadi M, Khodadadi M. Malignant transformation rate of oral precancerous disorders to oral cancer: systematic review and meta-analysis of the current evidence[J]. Front Oral Health, 2025, 6: 1673474. doi: 10.3389/froh.2025.1673474.

[3] Warnakulasuriya S, Kujan O, Aguirre-Urizar JM, et al. Oral potentially malignant disorders: a consensus report from an international seminar on nomenclature and classification, convened by the WHO collaborating centre for oral cancer[J]. Oral Dis, 2021,

27(8): 1862-1880. doi: 10.1111/odi.13704.

[4] Zhang C, Li B, Zeng X, et al. The global prevalence of oral leukoplakia: a systematic review and meta-analysis from 1996 to 2022 [J]. BMC Oral Health, 2023, 23(1): 645. doi: 10.1186/s12903-023-03342-y.

[5] Villa A, Lodolo M, Ha P. Oncological outcomes of patients with oral potentially malignant disorders[J]. JAMA Otolaryngol Head Neck Surg, 2025, 151(1): 65-71. doi: 10.1001/jamaoto.2024.3719.

[6] Öhman J, Zlotogorski-Hurvitz A, Dobriyan A, et al. Oral erythroplakia and oral erythroplakia-like oral squamous cell carcinoma - what's the difference [J]. BMC Oral Health, 2023, 23(1): 859. doi: 10.1186/s12903-023-03619-2.

[7] Wadde KR, Gajare PP, Sachdev SS, et al. Prevalence and malignant transformation rate of oral erythroplakia worldwide - a systematic review[J]. Ann Maxillofac Surg, 2024, 14(1): 76-80. doi: 10.4103/ams.ams_181_23.

[8] Boffano P, Neirotti F, Nikolovska V, et al. Clinical characteristics, management, and malignancy rate of oral lichen planus: a European multicenter study[J]. J Stomatol Oral Maxillofac Surg, 2025, 126(3S): 102218. doi: 10.1016/j.jormas.2025.102218.

[9] Alqarni A, Alarabi SM, Alamri MA, et al. Understanding oral lichen planus and its malignant potential in the Saudi Arabian population: a systematic review[J]. Oral Health Prev Dent, 2025, 23: 691-699. doi: 10.3290/j.ohpd.c_2337.

[10] Mohideen K, Ghosh S, Krithika C, et al. Malignant transformation of proliferative verrucous leukoplakia-systematic review & meta-analysis[J]. BMC Oral Health, 2025, 25(1): 175. doi: 10.1186/s12903-025-05565-7.

[11] Fatih MT, Mahmood MK, Garib BT, et al. Malignant transformation of oral leukoplakia and proliferative verrucous leukoplakia and its biomarker predictors: a systematic umbrella review[J]. Head Neck, 2026, 48(1): 246-260. doi: 10.1002/hed.70073.

[12] Wang M, Duan C, Wei Y, et al. Prevalence of oral submucous fibrosis across diverse populations: a systematic review and meta-analysis[J]. PeerJ, 2024, 12: e18385. doi: 10.7717/peerj.18385.

[13] Gondivkar SM, Yuwanati M, Sarode SC, et al. Malignant transformation in oral submucous fibrosis: tertiary level evidence: an umbrella review[J]. Oral Dis, 2024, 30(4): 1818-1827. doi: 10.1111/odi.14718.

[14] Vasilovici A, Ungureanu L, Grigore L, et al. Actinic cheilitis-from risk factors to therapy[J]. Front Med, 2022, 9: 805425. doi: 10.3389/fmed.2022.805425.

[15] de Santana Sarmento DJ, da Costa Miguel MC, Queiroz LMG, et al. Actinic cheilitis: clinicopathologic profile and association with degree of dysplasia[J]. Int J Dermatol, 2014, 53(4): 466-472. doi: 10.1111/ijd.12332.

[16] Carneiro MC, Quenta-Huayhua MG, Peralta-Mamani M, et al. Clinicopathological analysis of actinic cheilitis: a systematic review with meta-analyses[J]. Head Neck Pathol, 2023, 17(3): 708-721. doi: 10.1007/s12105-023-01543-z.

[17] Alvarez Gómez GJ, Alvarez Martínez E, Jiménez Gómez R, et al. Reverse smokers' and changes in oral mucosa. Department of Sucre, Colombia[J]. Med Oral Patol Oral Cir Bucal, 2008, 13(1): E1-E8.

[18] Kumbhalwar A, Shetiya SH, Kakodkar P, et al. Prevalence of precancerous lesions and conditions in India: a systematic review and meta-analysis[J]. World J Methodol, 2022, 12(4): 293-304. doi: 10.5662/wjm.v12.i4.293.

[19] de Arruda JAA, Villarroel-Dorrego M, Freire CH, et al. Oral lesions of systemic lupus erythematosus: a collaborative Latin American study[J]. Lupus, 2024, 33(8): 864-873. doi: 10.1177/09612033241252042.

[20] Rodrigues LRS, Ferraz DLF, de Oliveira CRG, et al. Risk and prevalence of oral cancer in patients with different types of lupus erythematosus: a systematic review and meta-analysis[J]. Oral Surg Oral Med Oral Pathol Oral Radiol, 2023, 136(5): 595-605. doi: 10.1016/j.oooo.2023.07.007.

[21] Uria-Oficialdegui ML, Navarro S, Murillo-Sanjuan L, et al. Dyskeratosis congenita: natural history of the disease through the study of a cohort of patients diagnosed in childhood[J]. Front Pediatr, 2023, 11: 1182476. doi: 10.3389/fped.2023.1182476.

[22] Watanabe H, Takahashi Y, Namiki T, et al. Dyskeratosis congenita complicated by pulmonary fibrosis and myelodysplastic syndrome with a germline mutation of the DKC1 gene and a somatic mutation of the U2AF1 gene in leukocytes[J]. Intern Med, 2025, 64(20): 3000-3006. doi: 10.2169/internalmedicine.5153-24.

[23] Alter BP, Giri N, Savage SA, et al. Cancer in dyskeratosis congenita[J]. Blood, 2009, 113(26): 6549-6557. doi: 10.1182/blood-2008-12-192880.

[24] Ramos-García P, González-Moles MÁ, Warnakulasuriya S. Oral cancer development in lichen planus and related conditions-3.0 evidence level: a systematic review of systematic reviews[J]. Oral Dis, 2021, 27(8): 1919-1935. doi: 10.1111/odi.13812.

[25] Lee SJ. Classification systems for chronic graft-versus-host disease [J]. Blood, 2017, 129(1): 30-37. doi: 10.1182/blood-2016-07-686642.

[26] Yamada A, Torihata S, Shimoide T, et al. Prevalence of oral chronic graft versus host disease after allogeneic stem cell transplantation[J]. Oral Sci Int, 2024, 21(2): 249-254. doi: 10.1002/osi2.1218.

[27] Santarone S, Natale A, Angelini S, et al. Secondary oral cancer following hematopoietic cell transplantation[J]. Bone Marrow Transplant, 2021, 56(5): 1038-1046. doi: 10.1038/s41409-020-01147-z.

[28] Zhou P, Yeshoua BJ, Konuthula N, et al. Association of oral health determinants with oral squamous cell carcinoma in never-smoking adults[J]. Head Neck, 2025, 47(7): 2025-2032. doi: 10.1002/hed.28119.

[29] Yamamoto Y, Kamiya T, Yano M, et al. Oral microbial profile analysis in patients with oral and pharyngeal cancer reveals that tumoral *Fusobacterium nucleatum* promotes oral cancer progression by activating YAP[J]. Microorganisms, 2023, 11(12): 2957. doi: 10.3390/microorganisms11122957.

[30] Surendran S, Aboelkheir U, Tu AA, et al. T-cell infiltration and immune checkpoint expression increase in oral cavity premalignant and malignant disorders[J]. Biomedicines, 2022, 10(8): 1840. doi: 10.3390/biomedicines10081840.

[31] Yang J, Wang S, Li X, et al. Signaling pathways and targeted interventions for precancers[J]. Signal Transduct Target Ther, 2026, 11(1): 9. doi: 10.1038/s41392-025-02342-4.

[32] Cai X, Zhang J, Li L, et al. Copy number alterations predict development of OSCC from oral leukoplakia[J]. J Dent Res, 2024, 103(2): 138-146. doi: 10.1177/00220345231217160.

[33] Liu KYP, Ko YCK, Poh CF. Pattern-based p53 and p16 immunohistochemistry as a potential alternative to loss of heterozygosity testing for progression risk of oral epithelial dysplasia[J]. Cancer Prev Res, 2026, 19(3): 137-144. doi: 10.1158/1940-6207.CAPR-25-0406.

[34] Mao L, Lee JS, Fan YH, et al. Frequent microsatellite alterations at chromosomes 9p21 and 3p14 in oral premalignant lesions and their value in cancer risk assessment[J]. Nat Med, 1996, 2(6): 682-685. doi: 10.1038/nm0696-682.

[35] Scully C, Field JK, Tanzawa H. Genetic aberrations in oral or head and neck squamous cell carcinoma 2: chromosomal aberrations[J]. Oral Oncol, 2000, 36(4): 311-327. doi: 10.1016/S1368-8375(00)00021-x.

[36] Mortezagholi B, Nasiri K, Movahed E, et al. miR-34 by targeting p53 induces apoptosis and DNA damage in paclitaxel-resistant human oral squamous carcinoma cells[J]. Chem Biol Drug Des, 2023, 102(2): 285-291. doi: 10.1111/cbdd.14240.

[37] Babu SS, Sunil S, Dalvi Y, et al. DNA methylation biomarkers as an early diagnostic tool in the progression of oral squamous cell carcinoma[J]. J Oral Maxillofac Pathol, 2025, 29(4): 519-527. doi: 10.4103/jomfp.jomfp_199_25.

[38] Qurishi AA, Morsy MSM, Atout AM, et al. Evaluating the role of genetic markers in predicting oral leukoplakia malignancy transformation[J]. J Pharm Bioallied Sci, 2025, 17(Suppl 2): S1153-S1155. doi: 10.4103/jpbs.jpbs_1523_24.

[39] Kumbhar G, Suryawanshi P, Ladke V. Wortmannin exhibits anticancer activity in oral cancer cell line by targeting PI3K, AKT and mTOR pathway[J]. Avicenna J Phytomed, 2026, 16(2): 78-98. doi: 10.22038/ajp.2025.26226.

[40] Helli S, Heidari A, Tafvizi A, et al. Gallic acid induces apoptosis in oral squamous cell carcinoma *via* PI3K/AKT/mTOR pathway inhibition and PTEN upregulation: an *in vitro* study[J]. Drug Res, 2026, 76(1): 14-19. doi: 10.1055/a-2724-9894.

[41] Hu C, Zhao X, Cui C, et al. miRNA-29-3p targets PTEN to regulate follicular development through the PI3K/Akt/mTOR signaling pathway[J]. Theriogenology, 2024, 214: 173-181. doi: 10.1016/j.theriogenology.2023.10.024.

[42] Adereh A, Amini P, Fateh A, et al. Loc646329 sponges miR-21 to reduce RAS/MAP kinase signaling pathway in oral squamous cell carcinoma (OSCC)[J]. Naunyn Schmiedebergs Arch Pharmacol, 2025, 398(6): 6755-6763. doi: 10.1007/s00210-024-03671-x.

[43] Peña-Oyarzún D, Flores T, Torres VA, et al. Inhibition of PORCN blocks Wnt signaling to attenuate progression of oral carcinogenesis[J]. Clin Cancer Res, 2024, 30(1): 209-223. doi: 10.1158/1078-0432.CCR-23-0318.

[44] Huang J, Li H, Yang Z, et al. SALL4 promotes cancer stem-like cell phenotype and radioresistance in oral squamous cell carcinomas *via* methyltransferase-like 3-mediated m6A modification[J]. Cell Death Dis, 2024, 15(2): 139. doi: 10.1038/s41419-024-06533-9.

[45] Huang R, Feng X, Zhou T, et al. METTL5 promotes tumor progression in oral squamous cell carcinoma by activating the Myc pathway[J]. J Oral Pathol Med, 2025, 54(2): 91-99. doi: 10.1111/jop.13601.

[46] Yadav RP, Baranwal S. Kindlin-2 regulates colonic cancer stem-like cells survival and self-renewal *via* Wnt/β-catenin mediated pathway[J]. Cell Signal, 2024, 113: 110953. doi: 10.1016/j.cellsig.2023.110953.

[47] Dharavath B, Butle A, Chaudhary A, et al. Recurrent UBE3C-LRP5 translocations in head and neck cancer with therapeutic implications[J]. NPJ Precis Oncol, 2024, 8(1): 63. doi: 10.1038/s41698-024-00555-4.

[48] Dvojakovska S, Popovic-Monevska D, Grcev A, et al. Promotor hypermethylated genes: prospective diagnostic biomarkers in oral cancerogenesis[J]. J Craniomaxillofac Surg, 2018, 46(10): 1737-1740. doi: 10.1016/j.jcms.2018.07.019.

[49] Ghose S, Chaudry UR, Chakravarty S, et al. Integrated profiling reveals polarity protein dysregulation during oral cancer progression[J]. Sci Rep, 2025, 15(1): 43684. doi: 10.1038/s41598-025-27447-2.

[50] Sun S, Zhong B, Wang Y, et al. Phosphorylation of PA28γ by CK2 kinase facilitates HNSCC tumor formation and progression[J]. Nat Commun, 2025, 17(1): 443. doi: 10.1038/s41467-025-67131-7.

[51] Hanna GJ, Villa A, Nandi SP, et al. Nivolumab for patients with high-risk oral leukoplakia: a nonrandomized controlled trial[J]. JAMA Oncol, 2024, 10(1): 32-41. doi: 10.1001/jamaoncol.2023.4853.

[52] Hu S, Lu H, Xie W, et al. TDO^{2+} myofibroblasts mediate immune suppression in malignant transformation of squamous cell carcinoma[J]. J Clin Invest, 2022, 132(19): e157649. doi: 10.1172/JCI157649.

[53] Zhang XY, Shi JB, Jin SF, et al. Metabolic landscape of head and neck squamous cell carcinoma informs a novel kynurenine/Siglec-15 axis in immune escape[J]. Cancer Commun, 2024, 44(6): 670-694. doi: 10.1002/cac2.12545.

[54] Liu Y, Shen L, Li Y, et al. ETS1-mediated regulation of SOAT1 enhances the malignant phenotype of oral squamous cell carcinoma and induces tumor-associated macrophages M2-like polarization[J]. Int J Biol Sci, 2024, 20(9): 3372-3392. doi: 10.7150/ijbs.93815.

[55] Wu L, Ye S, Yao Y, et al. Oral cancer stem cell-derived small extracellular vesicles promote M2 macrophage polarization and suppress $CD4^+$ T-cell activity by transferring UCA1 and targeting LAMC2[J]. Stem Cells Int, 2022, 2022: 5817684. doi: 10.1155/2022/5817684.

[56] Wang X, Wu S, Wu W, et al. *Candida albicans* promotes oral cancer *via* IL-17A/IL-17RA-macrophage axis[J]. mBio, 2023, 14(3): e0044723. doi: 10.1128/mbio.00447-23.

[57] Maldonado LAG, Nascimento CR, Rodrigues Fernandes NA, et al. Influence of tumor cell-derived TGF-β on macrophage phenotype

and macrophage-mediated tumor cell invasion[J]. Int J Biochem Cell Biol, 2022, 153: 106330. doi: 10.1016/j.biocel.2022.106330.

[58] Huang Z, Guo Y, Li B, et al. Siglec-15 on macrophages suppress the immune microenvironment in patients with PD-L1 negative non-metastasis lung adenocarcinoma[J]. Cancer Gene Ther, 2024, 31(3): 427-438. doi: 10.1038/s41417-023-00713-z.

[59] Li Y, Han X, Lin Z, et al. G6PD activation in TNBC cells induces macrophage recruitment and M2 polarization to promote tumor progression[J]. Cell Mol Life Sci, 2023, 80(6): 165. doi: 10.1007/s00018-023-04810-y.

[60] Kouketsu A, Haruka S, Kuroda K, et al. Myeloid-derived suppressor cells and plasmacytoid dendritic cells are associated with oncogenesis of oral squamous cell carcinoma[J]. J Oral Pathol Med, 2023, 52(1): 9-19. doi: 10.1111/jop.13386.

[61] Nguyen KA, DePledge LN, Bian L, et al. Polymorphonuclear myeloid-derived suppressor cells and phosphatidylinositol-3 kinase gamma are critical to tobacco-mimicking oral carcinogenesis in mice[J]. J Immunother Cancer, 2023, 11(9): e007110. doi: 10.1136/jitc-2023-007110.

[62] Eric H, Piersiala K, Lagebro V, et al. High expression of PD-L1 on conventional dendritic cells in tumour-draining lymph nodes is associated with poor prognosis in oral cancer[J]. Cancer Immunol Immunother, 2024, 73(9): 165. doi: 10.1007/s00262-024-03754-x.

[63] Lee KM, Fu Q, Huai G, et al. Suppression of allograft rejection by regulatory B cells induced *via* TLR signaling[J]. JCI Insight, 2022, 7(17): e152213. doi: 10.1172/jci.insight.152213.

[64] Yang D, Wang Z, Shang Q, et al. Decoding spatiotemporal microenvironmental changes in oral carcinogenesis[J]. J Dent Res, 2026, 105(5): 657-667. doi: 10.1177/00220345251378087.

[65] Piersiala K, Hjalmarsson E, da Silva PFN, et al. Regulatory B cells producing IL-10 are increased in human tumor draining lymph nodes[J]. Int J Cancer, 2023, 153(4): 854-866. doi: 10.1002/ijc.34555.

[66] Girdhar A, Kamboj M, Narwal A, et al. Immunohistochemical correlation of mast cells and angiogenesis in oral lichen planus[J]. Arch Oral Biol, 2022, 142: 105509. doi: 10.1016/j. archoralbio.2022.105509.

[67] Liu J, Lin WP, Xiao Y, et al. VISTA blockade alleviates immunosuppression of MDSCs in oral squamous cell carcinoma[J]. Int Immunopharmacol, 2023, 125(Pt A): 111128. doi: 10.1016/j. intimp.2023.111128.

[68] Chi J, Liu Y, Yang L, et al. Silencing of B7H4 represses the development of oral squamous cell carcinoma through promotion of M1 macrophage polarization[J]. J Oral Maxillofac Surg, 2022, 80(8): 1408-1423. doi: 10.1016/j.joms.2022.03.019.

[69] Piersiala K, da Silva PFN, Lagebro V, et al. Tumour-draining lymph nodes in head and neck cancer are characterized by accumulation of CTLA-4 and PD-1 expressing Treg cells[J]. Transl Oncol, 2022, 23: 101469. doi: 10.1016/j.tranon.2022.101469.

[70] Yang W, Zhang S, Li T, et al. Single-cell analysis reveals that cancer-associated fibroblasts stimulate oral squamous cell carcinoma invasion *via* the TGF-β/Smad pathway[J]. Acta Biochim Biophys Sin, 2022, 55(2): 262-273. doi: 10.3724/abbs.2022132.

[71] Tian H, Zhao S, Nie F, et al. The pro-cancer and immunosuppressive activity of macrophage-transformed cancer-associated fibroblasts in oral squamous cell carcinoma[J]. J Adv Res, 2026, 82: 521-534. doi: 10.1016/j.jare.2025.07.027.

[72] Liu Z, Zhang Z, Zhang Y, et al. Spatial transcriptomics reveals that metabolic characteristics define the tumor immunosuppression microenvironment *via* iCAF transformation in oral squamous cell carcinoma[J]. Int J Oral Sci, 2024, 16(1): 9. doi: 10.1038/s41368-023-00267-8.

[73] Zhao S, Zhang Y, Meng X, et al. $INHBA^{+}$ macrophages and pro-inflammatory CAFs are associated with distinctive immunosuppressive tumor microenvironment in submucous fibrosis-derived oral squamous cell carcinoma[J]. BMC Cancer, 2025, 25(1): 857. doi: 10.1186/s12885-025-14261-2.

[74] Niklander SE, Arúnguiz P, Faunes F, et al. Aging and oral squamous cell carcinoma development: the role of cellular senescence [J]. Front Oral Health, 2023, 4: 1285276. doi: 10.3389/froh.2023.1285276.

[75] Niklander S, Morales D, Valencia C, et al. Exploring senescent oral fibroblasts: implications in oral squamous cell carcinoma and potential pharmacological interventions[J]. Oral Surg Oral Med Oral Pathol Oral Radiol, 2025, 139(1): e34. doi: 10.1016/j.oooo.2024.10.249.

[76] Nie F, Zhang J, Tian H, et al. The role of CXCL2-mediated crosstalk between tumor cells and macrophages in *Fusobacterium nucleatum*-promoted oral squamous cell carcinoma progression[J]. Cell Death Dis, 2024, 15(4): 277. doi: 10.1038/s41419-024-06640-7.

[77] 张一博, 许立明, 乃吉拜·莫敏, 等. 牙龈卟啉单胞菌诱导口腔鳞状细胞癌免疫抑制微环境形成的机制研究[J]. 四川大学学报(医学版), 2025, 56(3): 746-753. doi: 10.12182/20250560602.
Zhang YB, Xu LM, Naijibai MOMIN, et al. Mechanism of *Porphyromonas gingivalis* inducing the formation of a local immunosuppressive microenvironment in oral squamous cell carcinoma[J]. J Sichuan Univ Med Sci, 2025, 56(3): 746-753. doi: 10.12182/20250560602.

[78] Jäwert F, Nyman J, Olsson E, et al. Regular clinical follow-up of oral potentially malignant disorders results in improved survival for patients who develop oral cancer[J]. Oral Oncol, 2021, 121: 105469. doi: 10.1016/j.oraloncology.2021.105469.

[79] Viglianisi G, Polizzi A, Grippaudo C, et al. Chemopreventive and biological strategies in the management of oral potentially malignant and malignant disorders[J]. Bioengineering, 2024, 11(1): 65. doi: 10.3390/bioengineering11010065.

[80] Łuczak JW, Palusińska M, Maślińska-Gromadka K, et al. The next generation of skin care: transforming retinoid therapeutics[J]. Cells, 2025, 14(21): 1650. doi: 10.3390/cells14211650.

[81] Lodi G, Franchini R, Warnakulasuriya S, et al. Interventions for treating oral leukoplakia to prevent oral cancer[J]. Cochrane Database Syst Rev, 2016, 7(7): CD001829. doi: 10.1002/14651858.CD001829.pub4.

[82] Jarczewska K, Kopeć M, Surmacki JM. *In vitro* analysis of β-carotene supplementation: insights from Raman spectroscopy on brain,

lung, and breast cancer cells[J]. Phys Chem Chem Phys, 2025, 27(29): 15350-15366. doi: 10.1039/d5cp01289a.

[83] Darouei B, Bohn T, Vahid F, et al. Dietary carotenoids and breast cancer risk: evidence from a large population-based incident case-control study[J]. Nutr Metab, 2025, 22(1): 107. doi: 10.1186/s12986-025-01007-x.

[84] López-Solís R, Castro-Barquero S, Donat-Vargas C, et al. Lycopene intake and prostate cancer risk in men at high cardiovascular risk: a prospective cohort study[J]. BMC Med, 2025, 23(1): 627. doi: 10.1186/s12916-025-04440-0.

[85] Gutkind JS, Molinolo AA, Wu X, et al. Inhibition of mTOR signaling and clinical activity of metformin in oral premalignant lesions [J]. JCI Insight, 2021, 6(17): e147096. doi: 10.1172/jci.insight.147096.

[86] Wang L, Wang YJ, Wang R, et al. Fasting-mimicking diet enhances EGFR-TKI efficacy in oral cancer through dual mechanisms: direct cancer cell sensitization and tumor-associated macrophage crosstalk[J]. Front Pharmacol, 2025, 16: 1641024. doi: 10.3389/fphar.2025.1641024.

[87] Yang M, Chen X, Cheng C, et al. Cucurbitacin B induces ferroptosis in oral leukoplakia *via* the SLC7A11/mitochondrial oxidative stress pathway[J]. Phytomedicine, 2024, 129: 155548. doi: 10.1016/j.phymed.2024.155548.

[88] Yang D, Yang D, Song Y, et al. Ferroptosis induction enhances photodynamic therapy efficacy for OLK[J]. J Dent Res, 2024, 103(12): 1227-1237. doi: 10.1177/00220345241280257.

[89] Xu Y, Mcmillan A, Gupta N, et al. *In situ* treatment with a TLR9 agonist virus-like particle to promote immune responses against oral epithelial dysplasia progression[J]. Cancer Immunol Immunother, 2025, 74(6): 189. doi: 10.1007/s00262-025-04023-1.

[90] Datarkar A, Shah V, Pandilwar P, et al. Is CO_2 laser effective in the surgical management of oral potentially malignant disorders? A systematic review and meta-analysis[J]. Lasers Med Sci, 2025, 40(1): 132. doi: 10.1007/s10103-025-04396-w.

[91] Sagalow ES, Kumar AT, Banoub RG, et al. Recurrence of premalignant oral cavity and oropharynx lesions after pulsed diode laser treatment[J]. Am J Otolaryngol, 2022, 43(5): 103556. doi: 10.1016/j.amjoto.2022.103556.

[92] Rodriguez-Lujan A, López-Jornet P, Pons-Fuster López E. Recurrence of oral leukoplakia after CO_2 laser resection: a prospective longitudinal study[J]. Cancers, 2022, 14(21): 5455. doi: 10.3390/cancers14215455.

[93] de Pauli Paglioni M, Migliorati CA, Schausltz Pereira Faustino I, et al. Laser excision of oral leukoplakia: does it affect recurrence and malignant transformation? A systematic review and meta-analysis[J]. Oral Oncol, 2020, 109: 104850. doi: 10.1016/j.oraloncology.2020.104850.

[94] Wu Y, Ren G, Sun M, et al. Expert consensus on cryosurgery therapy of mucosal melanoma on head and neck[J]. Cryobiology, 2025, 120: 105280. doi: 10.1016/j.cryobiol.2025.105280.

[95] Yu CH, Chen HM, Chang CC, et al. Cotton-swab cryotherapy for oral leukoplakia[J]. Head Neck, 2009, 31(8): 983-988. doi: 10.1002/hed.21055.

[96] Bhattarai BP, Singh AK, Singh RP, et al. Recurrence in oral leukoplakia: a systematic review and meta-analysis[J]. J Dent Res, 2024, 103(11): 1066-1075. doi: 10.1177/00220345241266519.

[97] Chen HM, Cheng SJ, Lin HP, et al. Cryogun cryotherapy for oral leukoplakia and adjacent melanosis lesions[J]. J Oral Pathol Med, 2015, 44(8): 607-613. doi: 10.1111/jop.12287.

[98] Saito T, Sugiura C, Hirai A, et al. Development of squamous cell carcinoma from pre-existent oral leukoplakia: with respect to treatment modality[J]. Int J Oral Maxillofac Surg, 2001, 30(1): 49-53. doi: 10.1054/ijom.2000.0012.

[99] Binnal A, Tadakamadla J, Rajesh G, et al. Photodynamic therapy for oral potentially malignant disorders: a systematic review and meta-analysis[J]. Photodiagnosis Photodyn Ther, 2022, 37: 102713. doi: 10.1016/j.pdpdt.2022.102713.

[100] Song Y, Tang F, Liu J, et al. A complete course of photodynamic therapy reduced the risk of malignant transformation of oral leukoplakia[J]. Photodiagnosis Photodyn Ther, 2024, 49: 104338. doi: 10.1016/j.pdpdt.2024.104338.

[101] Dong B, He M, Zhang J, et al. Effect of the combination of diode laser ablation with photodynamic therapy for oral leukoplakia with epithelial dysplasia: a retrospective study[J]. Oral Surg Oral Med Oral Pathol Oral Radiol, 2025, 140(2): 177-185. doi: 10.1016/j.oooo.2025.03.003.

[102] Mehanna HM, Rattay T, Smith J, et al. Treatment and follow-up of oral dysplasia-a systematic review and meta-analysis[J]. Head Neck, 2009, 31(12): 1600-1609. doi: 10.1002/hed.21131.

[103] Zhou S, Zhang X, Liu W, et al. Evaluating surgical excision to prevent progression of oral precancerous lesions: highlighting randomized controlled trials and cohort studies[J]. J Dent Sci, 2023, 18(4): 1876-1882. doi: 10.1016/j.jds.2023.05.033.

[104] Talreja L, Goyal R, Yadav D, et al. Evaluation of clinical outcomes and recurrence after surgical excision of oral leukoplakia: a prospective cohort study[J]. Cureus, 2024, 16(10): e71593. doi: 10.7759/cureus.71593.

[105] 谢雨朗, 李春雨, 蒋思鑫, 等. 增殖性疣状白斑诊断和治疗的研究新进展[J]. 中华口腔医学杂志, 2023, 58(10): 1083-1090. doi: 10.3760/cma.j.cn112144-20230816-00088.
Xie YL, Li CY, Jiang SX, et al. Research progress in the diagnosis and management of proliferative verrucous leukoplakia[J]. Chin J Stomatol, 2023, 58(10): 1083-1090. doi: 10.3760/cma.j.cn112144-20230816-00088.

[106] Lombardi N, Arduino PG, Lampiano M, et al. Surgical treatment compared with "wait and see" in patients affected by oral leukoplakia to prevent oral cancer: preliminary data from a multicenter randomized controlled trial[J]. Oral Dis, 2025, 31(3): 807-814. doi: 10.1111/odi.15058.

[107] Xu H, Gao Z, Liu H, et al. Associations of lifestyle factors with oral cancer risk: an umbrella review[J]. J Stomatol Oral Maxillofac Surg, 2025, 126(3S): 102234. doi: 10.1016/j.jormas.2025.102234.

[108] Sundaram E, Pal US, Sowmya MV, et al. Field cancerisation in oral squamous cell carcinoma patients: a systematic review[J]. J Maxillofac Oral Surg, 2025, 24(2): 416-431. doi: 10.1007/s12663-024-02287-1.

[109] 中华口腔医学会口腔黏膜病学专业委员会, 中华口腔医学会中西医结合专业委员会. 口腔扁平苔藓诊疗指南(修订版)[J]. 中华口腔医学杂志, 2022, 57(2): 115-121. doi: 10.3760/cma.j.cn112144-20211115-00505.
Society of Oral Medicine, Chinese Stomatological Association. Guideline for the diagnosis and treatment of oral lichen planus(revision)[J]. Chin J Stomatol, 2022, 57(2): 115-121. doi: 10.3760/cma.j.cn112144-20211115-00505.

[110] 魏子豪, 曾昕, 陈谦明. 口腔白斑病的规范性临床诊疗[J]. 中华口腔医学杂志, 2022, 57(8): 884-889. doi: 10.3760/cma.j.cn112144-20220606-00304.
Wei ZH, Zeng X, Chen QM. Standardized diagnosis and treatment of oral leukoplakia[J]. Chin J Stomatol, 2022, 57(8): 884-889. doi: 10.3760/cma.j.cn112144-20220606-00304.

[111] 张珊珊, 刘传霞, 陈谦明.《增殖性疣状白斑: 标准化评估和报告的专家共识指南》解读[J]. 中华口腔医学杂志, 2024, 59(8): 771-776. doi: 10.3760/cma.j.cn112144-20240116-00026.
Zhang SS, Liu CX, Chen QM. Interpretation of "proliferative verrucous leukoplakia: an expert consensus guideline for stadardized assessment and reporting"[J]. Chin J Stomatol, 2024, 59(8): 771-776. doi: 10.3760/cma.j.cn112144-20240116-00026.

[112] Society of Oral Medicine, Chinese Stomatological Association. Guideline for the diagnosis and clinical management of oral submucous fibrosis[J]. Chin J Dent Res, 2023, 26(4): 271-285. doi: 10.3290/j.cjdr.b4784075.

[113] Guo X, He Y, Han Q, et al. Application of artificial intelligence in oral potentially malignant disorders: current opinions and future barriers[J]. Clin Transl Oncol, 2026, 28(3): 804-817. doi: 10.1007/s12094-025-04043-4.

[114] Kouketsu A, Doi C, Tanaka H, et al. Detection of oral cancer and oral potentially malignant disorders using artificial intelligence-based image analysis[J]. Head Neck, 2024, 46(9): 2253-2260. doi: 10.1002/hed.27843.

[115] Li J, Kot WY, McGrath CP, et al. Diagnostic accuracy of artificial intelligence assisted clinical imaging in the detection of oral potentially malignant disorders and oral cancer: a systematic review and meta-analysis[J]. Int J Surg, 2024, 110(8): 5034-5046. doi: 10.1097/JS9.0000000000001469.

[116] Feng L, Li Q, Wang H, et al. Advancing oral leukoplakia progression recognition: a benchmark with dataset, method, and application[J]. Neural Netw, 2026, 195: 108256. doi: 10.1016/j.neunet.2025.108256.

[117] Araújo ALD, da Silva AVB, Gonçalves ARM, et al. Two-step pipeline for oral diseases detection and classification: a deep learning approach[J]. Front Oral Health, 2025, 6: 1659323. doi: 10.3389/froh.2025.1659323.

[118] Araújo ALD, Silva VMD, Moraes MC, et al. The use of deep learning state-of-the-art architectures for oral epithelial dysplasia grading: a comparative appraisal[J]. J Oral Pathol Med, 2023, 52(10): 980-987. doi: 10.1111/jop.13477.

[119] Viet CT, Zhang M, Dharmaraj N, et al. Artificial intelligence applications in oral cancer and oral dysplasia[J]. Tissue Eng Part A, 2024, 30(19/20): 640-651. doi: 10.1089/ten.TEA.2024.0096.

[120] Shephard AJ, Mahmood H, Raza SEA, et al. Development and validation of an artificial intelligence-based pipeline for predicting oral epithelial dysplasia malignant transformation[J]. Commun Med, 2025, 5(1): 186. doi: 10.1038/s43856-025-00873-z.

[121] Adeoye J, Wang H, Lo AWI, et al. Multidimensional artificial intelligence-based cancer progression prediction in oral leukoplakia[J]. J Dent Res, 2026, 105(6): 727-736. doi: 10.1177/00220345251378053.

[122] Veseli E, Adeoye J. The future of oral cancer care through AI-powered clinics[J]. Br Dent J, 2025, 238(12): 908-909. doi: 10.1038/s41415-025-8902-1.

（编辑　张琳）

Open Access
This article is licensed under a Creative Commons Attribution 4.0 International License.
Copyright © 2026 by Editorial Department of Journal of Prevention and Treatment for Stomatological Diseases

官网