OPEN ACCESS
[DOI]10.12016/j.issn.2096-1456.202550532

·综述·

自体牙移植术临床管理现状与展望

马向玉[1,2]，　谭学莲[2]，　段沛沛[3]，　黄定明[2]
1.绵阳市中医医院口腔科，四川 绵阳（621000）；　2.口腔疾病防治全国重点实验室 国家口腔医学中心 国家口腔疾病临床医学研究中心 四川大学华西口腔医院牙体牙髓科，四川 成都（610041）；　3.口腔疾病防治全国重点实验室 国家口腔医学中心 国家口腔疾病临床医学研究中心 四川大学华西口腔医院正畸科，四川 成都（610041）

【摘要】　自体牙移植术（ATT）是一种将口腔内非功能性牙齿（供体牙）移植至牙列缺损区域（受植区）的技术。该技术不仅具有可靠的长期成功率与存留率，还具备独特的骨诱导能力及软组织保存优势，尤其适用于青少年牙列缺损的修复。然而，ATT技术敏感度高，其成功实施依赖于术者对牙槽外科、牙周病学、牙体牙髓病学、修复学及正畸学等多学科知识的综合掌握，以及个性化手术方案的精准设计与操作。术前需系统评估供体牙的牙根发育程度、受植区骨量条件以及二者的匹配度等。根尖孔未闭合者多可通过血运重建实现牙髓自愈，成功率较高；而根尖已闭合者则需在术后2~4周完成根管治疗以减少并发症。借助锥形束CT（CBCT）、口内扫描及虚拟手术规划，可实现供体牙与受植区的精准匹配评估与移植方案设计。术中操作需通过精准规划与轻柔操作减少组织创伤、严格将供体牙离体时间控制在15 min以内，并始终保持牙根表面湿润以保护牙周膜，改善手术预后。3D打印的个性化手术导板、供体牙模型及定制骨凿等工具的应用，提高了牙槽窝预备的精确性；动态导航、手术机器人及人工智能等前沿技术亦展现出良好的应用潜力。

【关键词】　牙缺失；　牙移植；　自体牙移植；　虚拟手术规划；　微创拔牙；　计算机辅助设计；　3D打印；　数字化导板；　动态导航
【中图分类号】　R78　【文献标志码】　A　【文章编号】　2096-1456（2026）07-0696-13
【引用著录格式】　马向玉，谭学莲，段沛沛，等. 自体牙移植术临床管理现状与展望[J]. 口腔疾病防治，2026，34(7)：696-708. doi:10.12016/j.issn.2096-1456.202550532.

微信公众号

Current status and prospects of clinical management in autotransplantation of teeth

MA Xiangyu[1,2], TAN Xuelian[2], DUAN Peipei[3], HUANG Dingming[2].　1. Department of Stomatology, Mianyang Hospital of Traditional Chinese Medicine, Mianyang 621000, China;　2. State Key Laboratory of Oral Diseases & National Center for Stomatology & National Clinical Research Center for Oral Diseases & Department of Endodontics, West China Hospital of Stomatology, Sichuan University, Chengdu 610041, China;　3. State Key Laboratory of Oral Diseases & National Center for Stomatology & National Clinical Research Center for Oral Diseases & Deparment of Orthodontics, West China Hospital of Stomatology, Sichuan University, Chengdu 610041, China
Corresponding author: HUANG Dingming, Email: dingminghuang@163.com

【Abstract】　Autotransplantation of teeth (ATT) is a surgical technique that involves transplanting a non-functional tooth (donor tooth) within the oral cavity to an edentulous area (recipient site). This procedure not only demonstrates reliable long-term success and survival rates but also possesses unique osteoinductive capacity and soft tissue preservation advantages, making it particularly suitable for the restoration of dental defects in adolescents. However, ATT is highly technique-sensitive, and its successful implementation depends on the operator's comprehensive mastery of multidisciplinary knowledge, including alveolar surgery, periodontology, endodontics, prosthodontics, and orthodontics, as

【收稿日期】2025-11-18；　【修回日期】2026-03-11
【基金项目】四川省科技厅重点研发项目（2021YFS0031）；成都市科技项目（2024-YF05-02478-SN）；四川大学华西口腔医院临床研究项目（LCYJ-MS-202304）。
【作者简介】马向玉，副主任医师，硕士，Email：maxiangyu032031@163.com
【通信作者】黄定明，教授，博士，Email：dingminghuang@163.com

well as the precise design and execution of personalized surgical plans. Preoperative systematic evaluation is required to assess the root development stage of the donor tooth, the bone volume condition of the recipient site, and the compatibility between the donor tooth and the recipient site. For teeth with an open apex, pulpal healing through revascularization is often achievable with a high success rate, whereas those with a closed apex typically require root canal treatment 2 - 4 weeks postoperatively to minimize complications. Utilizing cone beam computed tomography, intraoral scanning, and virtual surgical planning enables accurate assessment of donor-recipient matching and the design of the transplantation plan. Intraoperatively, careful attention must be paid to minimizing tissue trauma through precise planning and gentle manipulation, strictly limiting the extra-oral time of the donor tooth to within 15 min, and maintaining the root surface moist at all times to protect the periodontal ligament and improve surgical outcomes. The application of tools, such as 3D-printed personalized surgical guides, donor tooth replicas, and customized osteotomes, has enhanced the precision of socket preparation. Further, emerging technologies, such as dynamic navigation, surgical robotics, and artificial intelligence, have also demonstrated promising potential in the field of ATT.

【Key words】 tooth loss; tooth transplantation; autotransplantation of teeth; virtual surgical planning; minimally invasive tooth extraction; computer aided design; three-dimensional printing; digital guide plate; dynamic navigation

J Prev Treat Stomatol Dis, 2026, 34(7): 696-708.

自体牙移植术(autotransplantation of teeth, ATT)指将口腔中一颗非功能性的牙齿(供体牙)移植到牙列缺损的区域(受植区),以恢复其功能和美观的术式[1-2]。其历史可追溯至古埃及时期,但直至20世纪中期,在牙髓生物学及牙周愈合机制研究的推动下,才逐步形成系统化的治疗理念[3]。相较于种植修复,ATT不仅有保留天然牙体及牙周组织结构、允许术后正畸调整等优势[4-5],年轻恒牙移植后牙根还能继续发育并促进颌骨生长[6],成为牙列缺损修复的重要选择[7-8]。但ATT的开展需要涉及微创拔牙技术、受植区的牙槽嵴保存、拔牙窝内牙周膜利用、骨增量、供体牙的牙髓处理等[9],其长期疗效与术者对技术前沿进展的掌握、个性化手术方案的设计及精准操作密切相关[10]。本文基于当前文献证据,旨在梳理ATT的核心理念与操作原则,并分析数字化技术的应用价值与未来趋势,从而为临床工作提供参考。

1　自体牙移植术的适应证

ATT适用于因牙胚发育异常、外伤、严重龋病或牙周病等原因导致的恒牙缺失[11]。常见的移植方案包括:将第三磨牙作为供体牙移植至第一或第二磨牙缺失区域[12-13]、将正畸需要拔除的前磨牙移植至前牙缺失区域等[14-15]。处于颌骨持续发育阶段的青少年牙列缺损患者,通常不适合进行种植修复或冠桥修复[16]。而移植的自体牙有骨诱导潜能,可以促进正常颌骨发育,还能通过后续正畸治疗进行咬合调整,建立良好的邻接关系和咬合关系[17]。

因此,对于有合适供体牙的青少年牙列缺损患者,ATT应作为建议治疗方案之一[17-18]。另外,牙齿严重异位萌出或埋伏阻生,正畸牵引困难的病例也可以采用ATT[19-20]。

2　自体牙移植术术前评估

2.1　评估内容

2.1.1　供体牙条件　对于年轻恒牙,牙根发育状态非常重要。根尖孔未闭合的供体牙存留率更高[21],且牙髓再血管化的比例可达96%[22]。但其移植后牙根平均增长仅2.83 mm[6],并不能完全发育到正常的牙根长度。理想的年轻恒牙供体牙应处于牙根发育接近完成、根尖孔尚未闭合的阶段,通常对应于Moorrees分期的第4~5期[23-24](表1)。此时牙根长度已达预期全长的2/3以上,且根尖孔直径通常大于1 mm,有利于血运重建[22]。术前可通过根尖X线片或锥形束CT(cone beam computed tomography, CBCT)进行测量,以精确评估牙根长度和根尖孔直径,辅助手术决策[25]。

根尖孔已闭合的牙齿也可作为供体牙,但牙髓坏死风险显著增高,通常需要进行根管治疗以降低移植失败风险[22]。供体牙通常可以选择额外的或无功能的牙齿。如第三磨牙[18]、正畸需要拔除的牙齿[26],也可选择多生牙[27]、乳牙[28]等。供体牙牙冠和牙根形态、大小需与受植区基本匹配。

表1　牙根发育的Moorrees分期[23-24]

Table 1　Moorrees classification of root development[23-24]

Moorrees classfication	Coded symbol	Stage
1	Ri	Initial root formation
2	R¼	Root length 1/4
3	R½	Root length 1/2
4	R¾	Root length 3/4
5	Rc	Root length complete
6	A½	Apex 1/2 closed
7	Ac	Apical closure complete

必要时可通过适度调磨、修复、旋转或正畸辅助移动等方式提升与受植区的适配度[29]。单根、圆锥形且根面平滑的牙齿因其易于微创完整拔出而更受青睐。存在严重牙周病变、牙根形态严重异常或未控制的重度根尖周炎的牙齿，失败风险较高，通常不宜选为供体牙[2, 30]。

2.1.2　受植区条件　受植区除需要评估缺隙大小能否容纳供体牙牙冠外，还需要测算可用骨量（高度、宽度和密度）是否足以容纳供体牙牙根、提供稳定支持[31]。对于轻度骨量不足，可考虑采用引导性骨再生术[32-33]或上颌窦提升术[34-35]等辅助手段来改善骨条件以接纳供体牙。但骨缺损过重，如骨壁高度或宽度丧失超过1/3，伴有颊舌侧骨板缺失时，预后通常较差，一般视为相对禁忌[2]。受植区应有健康的牙龈附着，无严重的急慢性炎症或咬合创伤。

2.1.3　患者因素　患者年龄可能影响ATT的成功率。有研究提示年轻患者成功率更高[36]，并推测与其更强的组织再生能力相关[37]，但也有文献报道认为年龄对ATT的预后无显著的影响[38-39]。患者维持良好的口腔卫生习惯及有效的菌斑控制对于移植牙的长期稳定和健康至关重要[40]。吸烟被明确为移植失败的重要危险因素，多因素分析研究显示吸烟者的ATT失败风险可高达非吸烟者的16.67倍[40]。

2.2　数字化技术在术前评估中的应用

ATT的成功高度依赖手术医生的经验与技巧。传统方法需要反复试放和调整供体牙，不仅耗时且操作繁琐，还可能损伤牙周膜细胞，进而影响移植成功率及牙根的后续发育[25]。数字化技术通过三维影像分析、计算机辅助设计与制作等技术进行术前周密规划与虚拟预演，降低对术者个人经验的依赖，提升了整个手术流程的安全性、精准度与可预测性[41]。

2.2.1　全面检查与数据采集　根据术前CBCT高分辨率的颌骨及牙齿三维数据，评估供体牙的牙根形态、长度、弯曲度，年轻恒牙的牙根发育阶段，受植区的可用骨量（包括高度、宽度、密度），牙槽窝形态以及其与邻近重要解剖结构（如下牙槽神经管、上颌窦、邻牙牙根）的空间关系等，判断供体牙与受植区的匹配度[42-43]。口内扫描获取牙列及软组织的数字模型，与CBCT数据融合后还可用于术前规划和导板设计。人工智能可通过这些数据评估供体牙拔出风险、指导牙槽窝预备参数设定及筛查根管变异等，为手术提供精准决策支持[44-45]。但现阶段其应用尚不成熟，在精度和应用范围方面需进一步提升[46]。

2.2.2　虚拟手术规划　在手术规划软件中进行牙齿分割和虚拟移植，优化移植位置、角度及咬合关系，可直观地评估骨容纳度、避免邻牙损伤、规划预备路径，提升手术安全性[47]。

2.2.3　制作个性化手术辅助工具　数字化导板技术在自体牙移植早期主要用于引导受植区牙槽窝的预备，近年来出现了拔牙导板、修整导板、植入定位导板、固定引导导板、根管治疗导板等多种类型，能够在手术的多个环节提供引导[48-49]。这些导板多采用生物相容性树脂材料，并通过3D打印或数控切削等数字化工艺制作完成。顺序钻孔导板和多轴钻孔导板等不同设计能够使术者依照预设路径与深度逐步完成窝洞预备，提升牙槽窝预备的准确度和可控性[50]。但Zhang等[51]的研究显示，通过导板进行移植的牙实际位置与虚拟设计之间仍存在一定偏差，平均颈部偏差约为（1.16±0.57）mm，根尖偏差约为（1.80±0.94）mm。有学者认为该偏差在临床可接受范围内，因供体牙与受植区之间应避免过度紧密贴合及直接骨接触[52]。也有学者指出这个偏差可能影响移植牙在颌骨内的最终排列与咬合关系[53]，需提升精准度[54]。

Wei等[44]尝试将深度学习技术应用于导板的自动生成。其算法所输出的设计方案在精度上可与高级医师媲美,同时减少了人工投入与时间成本,展现出良好的应用前景。

传统方法采用种植钻头预备牙槽窝,其器械形态与供体牙牙根形状之间存在固有差异,限制了牙槽窝与供体牙牙根的精准匹配。为克服这一局限,Anssari等[55]提出了一种新型的引导式牙槽窝预备技术。该技术基于CBCT数据定制与供体牙根形态完全匹配的骨凿,在初步预备后,通过小锤轻敲定制骨凿完成牙槽窝的最终成形,从而实现更佳的形态适配。此类定制骨凿可选用钛合金[54]或钴铬合金[52]等材料,通过3D打印或传统铸造工艺制作[56]。

牙槽窝预备以后,需要试植以确定牙槽窝的大小、方向是否合适[57]。2001年Lee等[58]提出了供体牙模型技术,该技术从CBCT中提取供体牙数据,通过计算机辅助快速成型技术打印出供体牙的3D模型,在术中代替真实供体牙进行受植区拟合和预备指导。这种技术可以缩短供体牙体外时间并减少对牙周膜的机械损伤,有助于改善预后[59-60],现已应用于ATT中。

医师在术前还可以打印患者牙列模型[61],在模型上模拟手术过程,验证手术导板的适配性与准确性,并提升操作熟练度,优化手术流程,缩短手术时间。

3　患者知情同意

因牙移植涉及多个学科[62],技术路径复杂,手术风险较高,因此在实施前与患者进行充分交流沟通,获得患者同意并书面签署知情同意书。

4　自体牙移植术的实施

4.1　拔除患牙与预备受植区

患牙拔除与供体牙移植可同期进行,也可延期进行,两者的成功率和存留率相近[63-64]。受植区炎症严重时应考虑拔牙2~4周后延期移植[2]。拔除患牙后,需彻底清除牙槽窝内病变组织,并轻柔去除牙槽间隔、修整侧壁,以形成适配供体牙根部的牙槽窝。预备器械可选择球钻、裂钻、种植钻针或个性化设计的骨凿等[52]。理想的受植区牙槽窝应比供体牙牙根深约2 mm,宽约1 mm[65]。牙槽窝初步预备完成后,建议使用供体牙模型试植入,必要时进行调整[66]。传统方法依赖于术者的空间想象与手感,在操作空间受限时难以精准控制,可以采用数字化导板、动态导航等技术进行辅助引导。动态导航技术相较于数字化导板具有更高的灵活性与直观性,不妨碍术中冷却,能够在术中实时追踪器械位置,并增强解剖结构的可视化,使医生能够根据牙槽骨的具体情况动态调整窝洞预备路径[67-68]。手术机器人在种植领域的尝试已经展现出其在颌骨预备中的优势,如精确定位和稳定控制、高效和微创等[69]。Liu等[70]采用人工智能结合手术机器人成功实施了2例ATT,术后3~6个月随访发现移植牙无松动、牙龈健康、咀嚼功能正常,影像学检查证实牙槽骨高度稳定、根周未见明显骨吸收,表现出良好的术后效果。手术机器人的核心优势在于其操作的标准化与智能化,这有望降低自体牙移植对医师个人经验的依赖,推动该技术的普及[71]。

关于受植区预备与供体牙拔出的先后顺序,临床实践中存在两种主流观点:一种主张先拔出供体牙再预备受植区[2],另一种则建议先预备受植区再拔出供体牙[72]。“先拔牙后预备”优先关注拔牙风险。若供体牙无法完整拔出,已预备的牙槽窝将失去意义,导致手术失败。“先预备后拔牙”的观点,则优先考虑牙周膜损伤风险。如果供体牙拔出后,受植区预备难度大,离体时间过长,术后牙根吸收和骨粘连风险将升高。

笔者建议在临床中进行个体化评估。若供体牙易拔出且受植区预备简单,优先采用“先预备后拔牙”以缩短供体牙离体时间;反之则采用“先拔牙后预备”;若两者风险均较高,可采用“分步拔牙法”,即先将供体牙拔松,估计能够完整拔出时暂停拔牙,让供体牙保持在原位牙槽窝内,完成受植区牙槽窝预备后,再完整拔出供体牙进行移植。

4.2　供体牙的拔出和处理

保护供体牙覆盖于牙根表面的牙周膜对成功实现牙移植非常重要。牙周膜干细胞可分化为成纤维细胞、成牙骨质细胞和成骨细胞,直接参与牙周组织愈合。临床研究表明,牙周膜损伤面积超过4 mm^2时,牙根外吸收风险显著增加[73]。因此,操作中需贯彻微创理念,通过数字化精准规划和轻柔的术中操作,最小化对牙周膜的损伤。包括①术前数字化评估与虚拟规划:通过CBCT获取供体牙及周围结构的三维数据精确测量牙根形态、弯曲度、牙周膜间隙宽度;虚拟手术规划,探讨最佳脱位方式,避免断根[1]。②器械选择与使用:为

减小牙周膜损伤，拔牙时尽量避免使用牙挺[73-74]。应选择专用牙钳或微创牙钳，将钳喙置于釉牙骨质界冠方的牙冠部，避免钳喙向根方滑动或直接挤压牙根表面，然后轻微缓慢地颊舌向摇动患牙并适当旋转，使牙周膜逐渐撕裂，牙齿松动拔出[72]。若供体牙为埋伏阻生牙，则需作必要的牙龈切开、翻瓣，并优先使用拔牙专用高速手机或超声骨刀进行精准去骨，小心去除覆盖牙冠及阻碍脱位的骨质，全程避免损伤牙根表面[2]。③保护牙根：供体牙离体后，其体外保存时间应严格控制在15 min内[75-76]，并始终保持牙根表面湿润，推荐使用冷藏的汉克氏平衡盐溶液或生理盐水保存[2]。

供体牙牙根处于不同发育阶段时牙髓处理策略也有所不同。约96%的年轻恒牙可通过血运重建实现牙髓自愈，无需常规根管治疗[22]。牙根发育完全的恒牙通常需根管治疗以提升存留率[77]，学者们曾尝试在不同的时机完成根管治疗。Barendregt等[23]在术前完成根管治疗，认为这能有效避免牙髓坏死引发的牙根炎症吸收。但术前根管治疗不适用于严重错位或埋伏阻生的供体牙，且根管治疗后的供体牙在拔牙过程中根折风险更高[78]。术中根管治疗因会导致离体时间延长，可能加剧牙周膜损伤，现已少用[79]。目前多数文献在移植术后2~4周进行根管治疗，此时牙周膜初步愈合尚未发生炎性牙根吸收[22, 35]，可以达到保护牙周组织愈合和预防牙根吸收的目的。

但是，根管治疗仍存在治疗难度大、耗时长、牙髓活力丧失等问题。学者们探索了多种新的牙髓处理方案[80]。Liao等[81]通过术中根尖切除联合倒充填替代根管治疗，存留率达100%，成功率70.4%，证实该简化方案的可行性。Plakwicz等[82]对5例供体牙进行根尖2~4 mm切除以扩大根尖孔，模拟年轻恒牙的牙髓再生环境；2年复查发现所有移植牙均出现根管闭塞，活动度正常，牙周组织健康。Gaviño Orduña等[83]采用脆性折裂（fragile fracture，FF）技术暴露根尖3 mm牙髓，同时植入富血小板纤维蛋白（platelet-rich fibrin，PRF）促进血运重建，复查发现牙髓活力测试反应为阳性，同时出现根管闭塞表现。Yoshihashi等[35]则在完成牙髓摘除和根管预备、严格消毒后，将牙髓干细胞注入根管，术后1周牙髓活力测试即出现阳性，60周时MRI证实根管系统内信号与正常牙髓一致，提示其出现了牙髓组织再生。综上所述，当前供体牙牙髓处理策略正从传统的根管治疗，向根尖手术、血运重建及组织工程再生等多元化方向发展，以期保留或恢复牙髓活力。然而，上述新技术多基于个案报告，其长期疗效及临床普适性仍需更多大样本研究加以证实。

4.3　供体牙植入

供体牙植入时也需注意保护牙周膜。操作中应避免触碰牙根表面或施加压力，可通过旋转、邻面调磨或修整牙槽窝达到良好就位[84-85]。植入后需确保咬合关系协调：供体牙𬌗面应略低于邻牙，既避免咬合创伤，也为年轻恒牙预留萌出空间。生物活性材料的应用可促进牙周愈合，如将骨替代材料[31]、自体血小板浓缩生长因子（concentrated growth factors，CGF）[86-87]、釉基质蛋白[88]或自体脱矿牙本质/牙骨质基质[89]等置于受植区牙槽窝内，可增强牙周再生能力。

4.4　移植牙的缝合和固定

移植牙就位后，需修整龈瓣并严密缝合，以建立良好的初期牙龈封闭，辅助供体牙的牙周愈合[2]。采用缝线或非刚性材料固定可以保持移植牙适度的生理性动度，激活牙周韧带细胞增殖，减少术后并发症[90]。

5　自体牙移植术的术后治疗

当移植牙存在牙冠宽度不足、邻接丧失或咬合干扰时，可通过树脂充填、嵌体或全冠修复恢复外形、邻接或重建咬合[91]。修复时间一般在6~8周以后开始[78]。正畸治疗也是可行的方案[92]，正畸加载还可促进受植区愈合[93]。有学者建议正畸应在骨改建完成（约6个月后）进行[78]，也有研究发现，术后3~4周开始施加轻力可降低骨强直和牙根替代性吸收的风险[23]，施力时机对最终牙根发育长度无显著影响[94]。ATT临床流程如图1所示。

6　数字导航自体牙移植术的临床病例

本病例的报道获得患者书面知情同意。患者，35岁男性，因36牙根纵裂伴根尖周病变拔除3月余就诊，38基本正位萌出。与患者沟通治疗方案后，患者选择将38移植至36缺牙间隙。

6.1　术前评估

38供体牙牙冠形态、大小与36受植区基本匹配（图2）。38供体牙牙根发育状态为完全发育，术前完善根管治疗。36受植区缺隙大小基本能容纳38供体牙冠并实现形态协调，但可用骨量（高度和宽度）不足以稳固支持供体牙根，术中需使用骨代

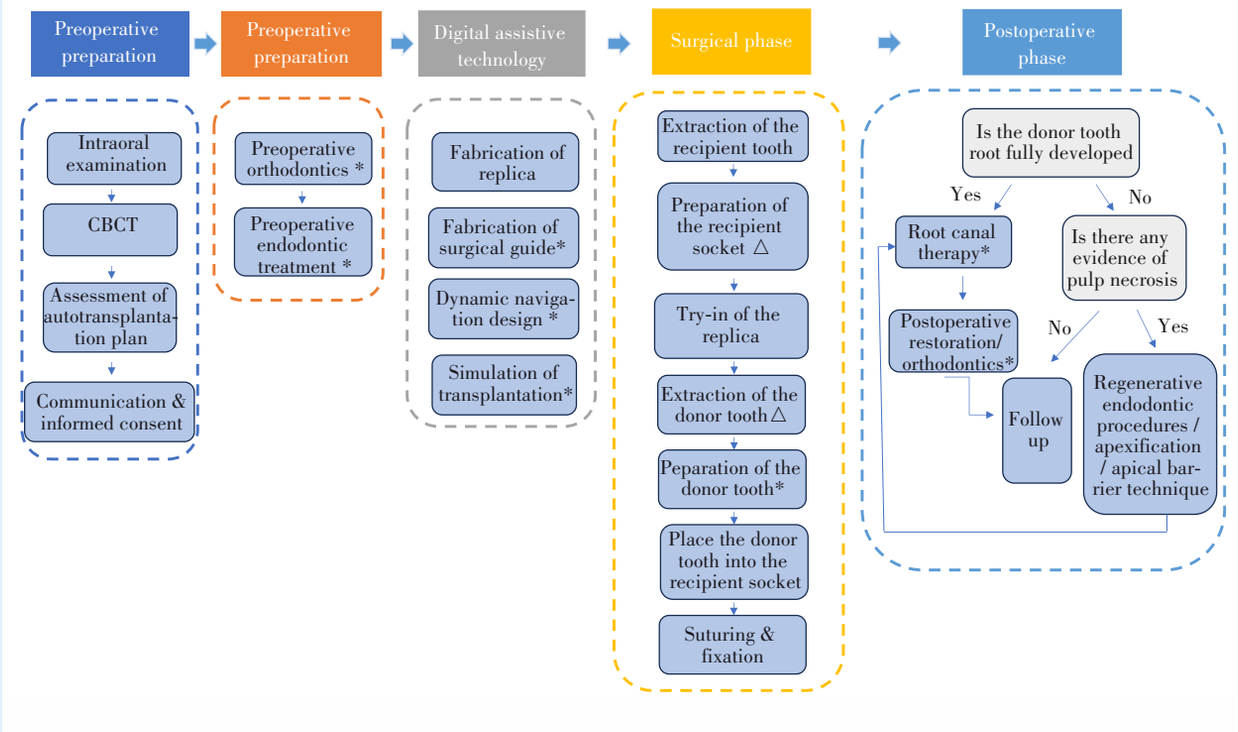

* indicates optional procedures. △ indicates that the sequence could be adjusted according to surgical conditions. CBCT: cone beam computed tomography

Figure 1　Clinical protocol for autotransplantation of teeth

图1　自体牙移植术临床操作流程

用品及CGF行骨增量及引导骨再生。本病例36拔除3月余，36受植区牙槽窝预备难度增加，38供体牙基本正位萌出、拔出难度适中，移植方案考虑先拔松38，保留至原牙槽窝内，待完成36受植区初预备以及供体牙模型试植、受植区牙槽窝修整后再完整拔出38供体牙，以减少供体牙体外时间。

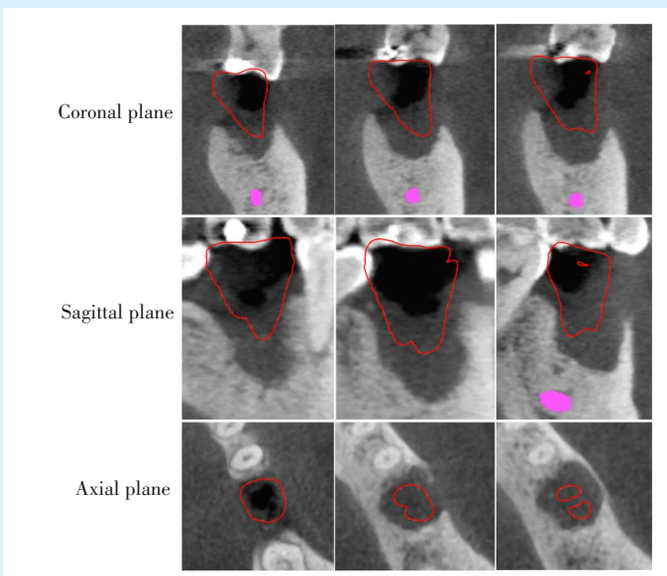

The red linear markings indicate the outline of donor tooth 38, and the purple markings delineate the region of the inferior alveolar nerve

Figure 2　Preoperative cone beam computed tomography and digital simulation to evaluate anatomic compatibility between donor tooth and recipient site

图2　术前CBCT及数字模拟评估供体牙与受植区匹配程度

6.2　数字化导板设计

根据患者CBCT数据及数字化口腔扫描信息，3D打印制作供体牙模型、供体牙牙冠模型、受植区牙槽窝预备导板（图3）。

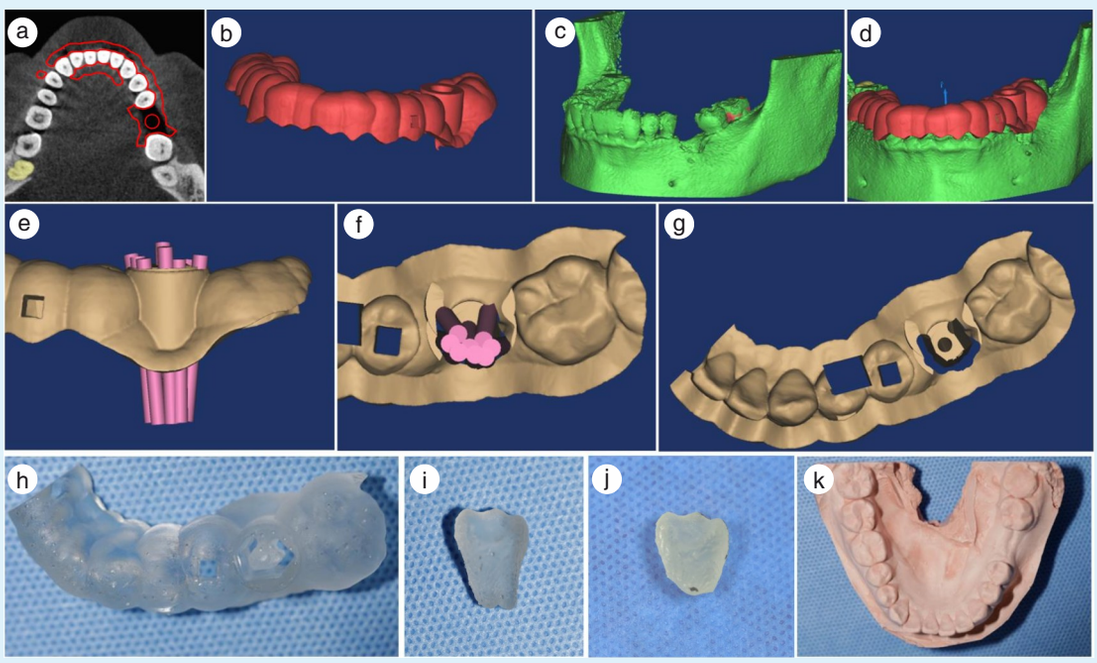

a-d: the alveolar socket preparation guide for tooth 36 was designed based on CBCT and digital scan data to fit the mandible and dentition. e-g: a refinement plan for the socket was developed according to the root surface contour. h: the socket preparation guide was 3D-printed. i: donor tooth replica was 3D-printed. j: crown of replica was 3D-printed. k: a plaster mandible model was produced

Figure 3　Design and fabrication of the guide for the recipient site of tooth 36 and the replica of donar tooth 38

图3　36受植区导板及38供体牙模型的设计与制作

6.3　术前体外模拟自体牙移植

使用制作的模型体外模拟ATT过程（图4）。

6.4　自体牙移植术实施

自体牙移植术实施过程见图5。

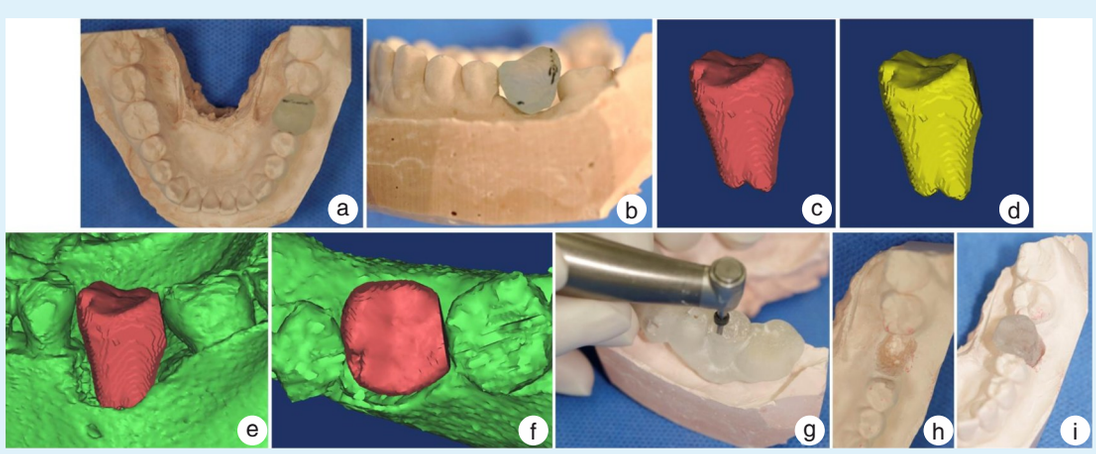

a-b: trial placement of donor tooth 38 revealed excessive distal convexity and mesial inclination of tooth 37, requiring adjustment for proper seating. c: 3D reconstruction of original donor tooth 38. d: 3D reconstruction after virtual adjustment. e-f: virtual autotransplantation. g-h: template-guided alveolar socket preparation on a plaster model. i: replica matched the prepared socket

Figure 4　*In vitro* simulation of the transplantation of donor tooth 38 into the recipient site of tooth 36

图4　体外模拟38供体牙移植至36受植区

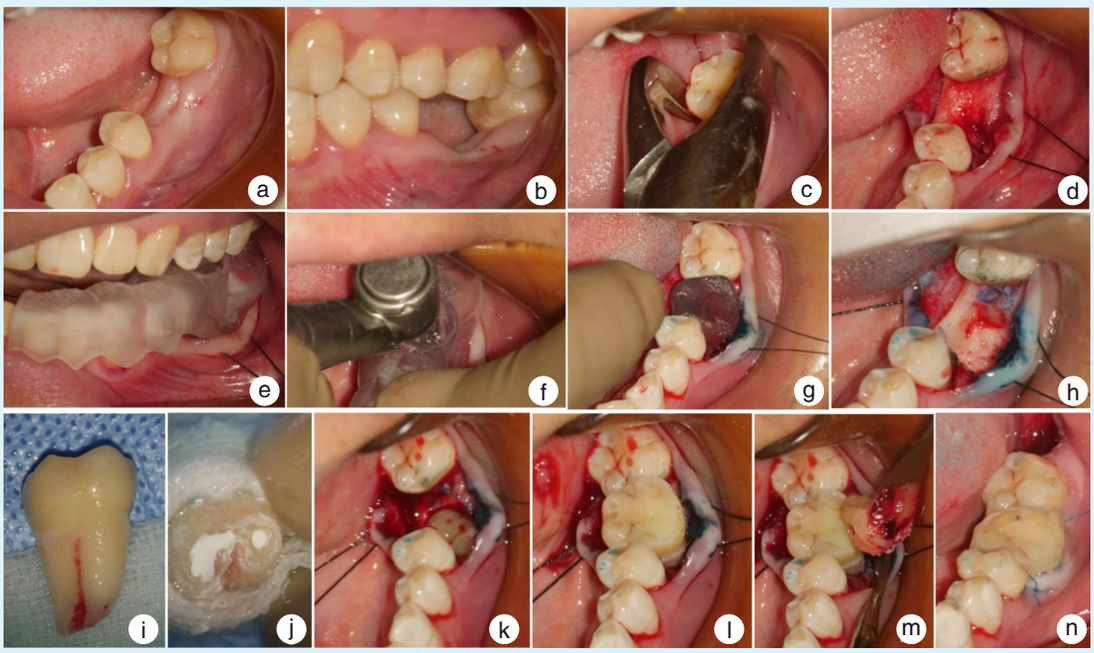

a: edentulous space of tooth 36. b: preoperative occlusion examination showed normal occlusal relationship. c: donor tooth 38 was luxated and retained within its socket. d: flap reflection. e: digital surgical guide positioned. f: guided preparation of the recipient alveolar socket. g: trial placement of the donor tooth replica. h: completed recipient alveolar socket after refinement. i: complete extraction of donor tooth 38. j: apicectomy and retrograde filling with bioceramic material performed on tooth 38. k: placement of concentrated growth factors(CGF). l: implantation of donor tooth 38. m: placement of CGF and bone substitute for guided bone regeneration. n: suturing and occlusal adjustment

Figure 5　Surgical procedure of autotransplantation of teeth: transplantation of donor tooth 38 into the recipient site of tooth 36

图5　自体牙移植术实施过程:38供体牙植入36受植区

6.5　术后复查

术后随访复查,38供体牙、36受植区牙槽骨愈合良好,38周围牙槽骨低密度影消失、牙龈及牙槽嵴高度维持良好、牙周附着正常(图6)。



a: preoperative root canal treatment of donor tooth 38 was completed. b: at 1 week postoperatively, donor tooth 38 was put in place of the tooth 36 recipient site, with a large periapical radiolucent area. c: at 1 month postoperatively, periapical radiolucency began to blur; alveolar bone reconstruction initiated. d: at 3 months postoperatively, periapical radiolucent area markedly reduced. e: at 7 months postoperatively, periapical radiolucency resolved; gingival and alveolar ridge height was well-maintained, with normal periodontal attachment

Figure 6　Postoperative radiographic evaluation of autotransplantation of teeth

图6　自体牙移植术后随访影像学检查

7　自体牙移植术预后

根据移植牙在口腔内的临床表现、影像学检查等,大多文献将移植牙的预后分为成功、存留与失败三类,各文献评判标准基本一致但细节略有差异[3, 95]。根据《自体牙移植术规范化操作流程中国专家共识》(2020)[2],成功的移植牙临床应有正常咀嚼功能、生理性动度(≤Ⅰ度松动)、无疼痛或炎症体征(如溢脓、红肿)且牙周探诊深度≤3 mm;影像学表现牙周膜间隙与骨硬板清晰、无进行性牙根吸收,牙根未发育完全者应存在持续牙根发

育及牙髓再血管化征象，牙根发育完全者应完成根管治疗。存留指随访期内移植牙未脱落但未达成功标准，表现为Ⅰ~Ⅱ度松动伴轻度牙周炎症（探诊出血，PD=4~5 mm）或部分功能受限。失败则定义为移植牙脱落、Ⅲ度松动、严重牙根吸收或牙周破坏（PD≥6 mm，骨丧失＞50%）导致功能丧失。所有结局判定需基于≥1年的随访证据。

Li等[48]报道ATT的1年成功率为70%~100%；Han等[13]研究发现6年成功率为97.6%，Barendregt等[23]对1 654颗移植牙进行10年随访，发现其成功率为88.3%~99.4%。Singh等[7]的系统评价表明，自体移植牙1年存留率为97.4%~98.0%，5年存留率为81%~98.2%。Tan等[96]对比发现牙根未发育完成组较发育完成组的存留率更高，5年存留率为97.3%，10年存留率仍可达96.63%。ATT整体失败率范围为2.0%~10.32%[7]。可能影响预后的因素包括患者年龄、供体牙根尖发育阶段、受植区骨量、手术微创程度、固定的方式以及牙髓治疗方式等[97-98]。

常见的术后并发症主要包括牙髓坏死、牙根吸收、骨粘连与牙周炎[30, 99]。根尖直径小于1 mm的移植牙应在术前或术后完成根管治疗；而对于牙根未发育完全的年轻恒牙，其牙髓坏死发生率仅约4%[100]，移植后应密切观察，如出现牙髓坏死，可根据牙根发育情况选择根尖诱导成形术、血运重建术、根尖屏障术或根管治疗术。

牙根吸收主要表现为牙根表面的凹陷样缺损，常伴有邻近牙槽骨的吸收，其发生与牙周膜损伤、牙体离体时间过长及牙根发育已成熟密切相关，其发生率约为4.6%[100]，一经确诊，应尽快行根管治疗以阻断其快速进展。

骨粘连，亦称替代性吸收，与更广泛的牙周膜损伤及愈合延迟有关，其发生率介于2.4%~4.4%[22]。其典型特征是在影像学上表现为牙周膜间隙消失，牙齿与牙槽骨形成骨性结合，临床叩诊可闻高调实音。成年患者的骨粘连进展缓慢且无明显症状，需定期观察；而青少年患者可能因此影响牙槽骨垂直向发育，此时可考虑采用截冠术予以干预[37]。此外，维持良好的口腔卫生、严格控制菌斑，并明确建议患者戒烟，是预防与管理移植牙牙周炎的重要基础。

8　小结与展望

ATT作为技术敏感性较高的术式，术者需要具备牙槽外科、牙周病学、牙体牙髓病学、修复学及正畸学等多学科知识。必要时应进行多学科协作，通过严谨的病例筛选与预后评估以优化疗效。尽管由于供体牙来源困难及医者培训不足等原因，导致其应用尚不广泛，但现有证据表明该技术不仅有可靠的长期成功率与存留率，还具有独特的骨诱导能力与软组织保存优势，尤其适用于青少年牙缺失的咬合功能维持与颌骨发育引导。而数字化技术及人工智能辅助规划的应用，为精准评估供体牙和受植区适配度、保护牙周膜等关键环节提供了临床实践成功的有力保障。因此，ATT应被视为一种值得临床推广的有效治疗方案，通过规范化培训与技术宣传提升其普及度和成功率。

【Author contributions】 Ma XY collected the references, wrote the article. Tan XL provided the clinical case, revised the article. Duan PP revised the article. Huang DM conceptualized and reviewed the article. All authors read and approved the final manuscript as submitted.

【Ethics statement】 The case report in the review article has obtained written informed consent from the patient.

【Funding】 This study was supported by the grants from Sichuan Natural Science Foundation (No. 2021YFS0031); Chengdu Science and Technology Program (No. 2024-YF05-02478-SN); West China Hospital of Stomatology, Sichuan University Clinical Research Project (No. LCYJ-MS-202304). The funder had no role in the study design, data collection and analysis, decision to publish, or preparation of the manuscript.

【Competing interests】 All authors have completed the ICMJE uniform disclosure form at www.icmje.org/disclosure-of-interest/ and declare: support from Sichuan Natural Science Foundation (No. 2021YFS0031); Chengdu Science and Technology Program (No. 2024-YF05-02478-SN); West China Hospital of Stomatology, Sichuan University Clinical Research Project (No. LCYJ-MS-202304) for the submitted work; no financial relationships with any organisations that might have an interest in the submitted work in the previous three years; no other relationships or activities that could appear to have influenced the submitted work.

【Data availability statement】 Data sharing is not applicable to this article as no datasets were generated or analyzed during the current study.

【Generative AI statement】 The authors declared that generative AI was not used in the creation of this manuscript.

参考文献

[1] Wei X, Du Y, Zhou X, et al. Expert consensus on digital guided therapy for endodontic diseases[J]. Int J Oral Sci, 2023, 15(1): 54. doi: 10.1038/s41368-023-00261-0.

[2] 中华口腔医学会牙及牙槽外科专业委员会. 自体牙移植术规范化操作流程中国专家共识[J]. 中国口腔颌面外科杂志, 2020,

18(5): 390-394. doi: 10.19438/j.cjoms.2020.05.002.
Professional Committee of Teeth and Alveolar Surgery, Chinese Stomatological Association. Chinese expert consensus on standardized operation process of autotransplantation of teeth[J]. China J Oral Maxillofac Surg, 2020, 18(5): 390-394. doi: 10.19438/j.cjoms.2020.05.002.

[3] García-Miralles E, Marqués-Martínez L, Borrell-García C, et al. Tooth autotransplantation with immature donors in children and adolescents: a systematic review with quality-assessed evidence[J]. J Clin Med, 2025, 14(23): 8387. doi: 10.3390/jcm14238387.

[4] Sasaki A, Fujimoto M, Fujimoto K, et al. Orthodontic treatment of a skeletal class III malocclusion with severe root resorption of the maxillary anterior teeth. Autotransplantation using a 3-dimensional printed replica of the donor tooth[J]. Am J Orthod Dentofacial Orthop, 2022, 161(2): 281-292. doi: 10.1016/j.ajodo.2020.10.028.

[5] de Freitas Coutinho NB, Nunes FC, Gagno Intra JB, et al. Success, survival rate, and soft tissue esthetic of tooth autotransplantation [J]. J Endod, 2021, 47(3): 391-396. doi: 10.1016/j.joen.2020.11.013.

[6] Beltrame LSA, Bronzato JD, Almeida TJDS, et al. A new approach for analyzing root development in autogenous tooth transplants using computed tomography[J]. Dent Traumatol, 2025, 41(2): 152-160. doi: 10.1111/edt.13006.

[7] Singh AK, Khanal N, Acharya N, et al. What are the complications, success and survival rates for autotransplanted teeth? An overview of systematic reviews and metanalyses[J]. Healthcare (Basel), 2022, 10(5): 835. doi: 10.3390/healthcare10050835.

[8] Williams BO, Jean-Baptiste M, Divaris K, et al. "In their own words": families' experiences with tooth autotransplantation for the replacement of maxillary incisors in children[J]. Dent Traumatol, 2025, 41(1): 104-117. doi: 10.1111/edt.12990.

[9] Yang Z, Wang Y, Zheng L, et al. Multidisciplinary combination therapy of precision autotransplantation in complex impacted teeth based on CAD/CAM digital navigation[J]. J Stomatol Oral Maxillofac Surg, 2025, 126(4S): 102144. doi: 10.1016/j.jormas.2024.102144.

[10] Suwanapong T, Waikakul A, Boonsiriseth K, et al. Pre- and perioperative factors influence autogenous tooth transplantation healing in insufficient bone sites[J]. BMC Oral Health, 2021, 21(1): 325. doi: 10.1186/s12903-021-01686-x.

[11] Abbasi AI, Shetty SS, de Arruda JAA. Autotransplantation of teeth: an alternative for patients with malignant transformation of oral submucous fibrosis[J]. Oral Oncol, 2022, 124: 105644. doi: 10.1016/j.oraloncology.2021.105644.

[12] Aravena-Salazar JP, Matus-Miranda G, Dethlefs-Canto J, et al. New complementary alternatives in third molar autotransplantation: a systematic review[J]. Med Oral Patol Oral Cir Bucal, 2024, 29(2): e241-e247. doi: 10.4317/medoral.26233.

[13] Han B, Liu L, Jiang Z, et al. Efficacy of root canal treatment for autotransplanted third molars: a 6-year cohort study of 167 teeth in Southern China[J]. PeerJ, 2025, 13: e18824. doi: 10.7717/peerj.18824.

[14] Jonsson T, Jonsdottir HB, Aspelund T, et al. Long-term survival of 57 premolars consecutively transplanted to premolar sites[J]. Am J Orthod Dentofacial Orthop, 2024, 166(5): 480-489. e3. doi: 10.1016/j.ajodo.2024.07.003.

[15] Doomen R, Barendregt D, Temmerman L, et al. Premolar autotransplantation to the anterior maxilla region-aesthetic outcome and patient satisfaction[J]. Dent Traumatol, 2025, 41(5): 534-547. doi: 10.1111/edt.13057.

[16] Velozo C, Nogueira LR, Nogueira Filho LR, et al. Tooth autotransplantation using an interdisciplinary approach to rehabilitation in a young patient: case report with 7-year follow-up[J]. Dent Traumatol, 2021, 37(3): 521-530. doi: 10.1111/edt.12637.

[17] Czochrowska E, Plakwicz P. Alveolar bone regeneration after transplantation of immature teeth in orthodontic patients[J]. Periodontol 2000, 2025. doi: 10.1111/prd.70023.

[18] Ma Z, Chen G, Liu Z, et al. Autotransplantation of an impacted immature third molar following orthodontic activation without endodontic intervention[J]. J Endod, 2026, 52(6): 1032-1039. doi: 10.1016/j.joen.2026.01.014.

[19] Cernochova P, Cernoch C, Klimo Kanovska K, et al. Treatment options for impacted maxillary canines and occurrence of ankylotic and resorptive processes: a 20-year retrospective study[J]. BMC Oral Health, 2024, 24(1): 877. doi: 10.1186/s12903-024-04662-3.

[20] 金作林. 埋伏阻生牙的正畸综合治疗[J]. 口腔疾病防治, 2023, 31(5): 305-311. doi: 10.12016/j.issn.2096-1456.2023.05.001.
Jin ZL. Comprehensive orthodontic treatment of impacted teeth[J]. J Prev Treat Stomatol Dis, 2023, 31(5): 305-311. doi: 10.12016/j.issn.2096-1456.2023.05.001.

[21] Lucas-Taulé E, Bofarull-Ballús A, Llaquet M, et al. Does root development status affect the outcome of tooth autotransplantation? A systematic review and meta-analysis[J]. Materials (Basel), 2022, 15(9): 3379. doi: 10.3390/ma15093379.

[22] Chhana AA, Moretti AJ, Lietzan AD, et al. A narrative and case-illustrated review on dental autotransplantation identifying current gaps in knowledge[J]. J Clin Med, 2024, 14(1): 17. doi: 10.3390/jcm14010017.

[23] Barendregt D, Andreasen JO, Leunisse M, et al. An evaluation of 1654 premolars transplanted in the posterior region-a retrospective analysis of survival, success and complications[J]. Dent Traumatol, 2023, 39 Suppl 1: 50-62. doi: 10.1111/edt.12849.

[24] Moorrees CF, Fanning EA, Hunt EE Jr. Age variation of formation stages for ten permanent teeth[J]. J Dent Res, 1963, 42: 1490-1502. doi: 10.1177/00220345630420062701.

[25] Lejnieks M, Akota I, Jākobsone G, et al. Clinical efficacy of CBCT and 3D-printed replicas in molar autotransplantation: a controlled clinical trial[J]. Dent Traumatol, 2025, 41(2): 161-170. doi: 10.1111/edt.13012.

[26] Atala-Acevedo C, Abarca J, Martínez-Zapata MJ, et al. Success rate of autotransplantation of teeth with an open apex: systematic review and meta-analysis[J]. J Oral Maxillofac Surg, 2017, 75(1): 35-50. doi: 10.1016/j.joms.2016.09.010.

[27] Bernal JD, Suresh N, Nagendrababu V, et al. Guided autotransplantation of a supernumerary tooth into a surgically created

socket using osseodensification and a palatal connective tissue graft: a case report[J]. J Endod, 2026, 52(3): 472-478. doi: 10.1016/j.joen.2025.12.001.

[28] Hoss F, El-Mahdy K, Linsenmann R, et al. Primary tooth autotransplantation: update and retrospective clinical study[J]. Acta Odontol Scand, 2021, 79(8): 582-592. doi: 10.1080/00016357.2021.1917656.

[29] Raabe C, Bornstein MM, Ducommun J, et al. A retrospective analysis of autotransplanted teeth including an evaluation of a novel surgical technique[J]. Clin Oral Investig, 2021, 25(6): 3513-3525. doi: 10.1007/s00784-020-03673-y.

[30] Marton J, Žižka R, Kučerová L, et al. Prevalence of post-operative complications in autotransplanted teeth: a long-term retrospective cohort[J]. Dent Traumatol, 2025. doi: 10.1111/edt.70038.

[31] Plakwicz P, Andreasen JO, Górska R, et al. Status of the alveolar bone after autotransplantation of developing premolars to the anterior maxilla assessed by CBCT measurements[J]. Dent Traumatol, 2021, 37(5): 691-698. doi: 10.1111/edt.12680.

[32] Testori T, Simion M, Carù FG, et al. Immature tooth autotransplantation with buccal bone fenestration treated with GBR and immature tooth autotransplantation in regenerated bone: proof of principles with medium- (55 months) to long-term (252 months) follow-ups[J]. Int J Periodontics Restorative Dent, 2026, 46(2): 186-201. doi: 10.11607/prd.7356.

[33] Verweij JP, Wes JT, van Teeseling RA, et al. Pre-autotransplantation alveolar process augmentation and premolar autotransplantation as a treatment method for single tooth replacement in adolescents[J]. Int J Oral Maxillofac Surg, 2021, 50(12): 1632-1637. doi: 10.1016/j.ijom.2021.04.010.

[34] Park YS, Baek SH, Lee WC, et al. Autotransplantation with simultaneous sinus floor elevation[J]. J Endod, 2012, 38(1): 121-124. doi: 10.1016/j.joen.2011.10.009.

[35] Yoshihashi N. Feasibility and outcomes of cell-based regenerative endodontic therapy in postautogenous transplantation of a mature tooth: a case report[J]. J Endod, 2025, 51(1): 85-93. doi: 10.1016/j.joen.2024.11.003.

[36] Cremona M, Bister D, Sherriff M, et al. Prognostic factors, outcomes, and complications for dental autotransplantation: an umbrella review[J]. Eur J Orthod, 2024, 46(1): cjad067. doi: 10.1093/ejo/cjad067.

[37] Zhang J, An Y, Gao LN, et al. The effect of aging on the pluripotential capacity and regenerative potential of human periodontal ligament stem cells[J]. Biomaterials, 2012, 33(29): 6974-6986. doi: 10.1016/j.biomaterials.2012.06.032.

[38] Louropoulou A, Andreasen JO, Leunisse M, et al. An evaluation of 910 premolars transplanted in the anterior region-a retrospective analysis of survival, success, and complications[J]. Dent Traumatol, 2024, 40(1): 22-34. doi: 10.1111/edt.12887.

[39] Martin K, Nathwani S, Bunyan R. Autotransplantation of teeth: an evidence-based approach[J]. Br Dent J, 2018, 224(11): 861-864. doi: 10.1038/sj.bdj.2018.432.

[40] 李永清, 惠小勇, 许广杰, 等. 自体牙移植修复单颗牙缺失预后因素的筛选及分析[J]. 中华口腔医学杂志, 2022, 57(5): 495-502. doi: 10.3760/cma.j.cn112144-20220209-00050.
Li YQ, Hui XY, Xu GJ, et al. Screening and analysis of prognostic factors of repairing single missing tooth by autotransplantation of teeth[J]. Chin J Stomatol, 2022, 57(5): 495-502. doi: 10.3760/cma.j.cn112144-20220209-00050.

[41] Barraco A, Marcoux C, Richert R, et al. Treatment by preplanned virtual autotransplantation of a microdont immature third molar to a maxillary central incisor socket using a 3D printed tooth replica: a case report[J]. Dent Traumatol, 2025, 41(4): 484-491. doi: 10.1111/edt.13044.

[42] Ong DV, Dance GM. Posterior tooth autotransplantation: a case series[J]. Aust Dent J, 2021, 66(1): 85-95. doi: 10.1111/adj.12757.

[43] Companioni S, Nguyen T, Divaris K, et al. Optimizing donor tooth selection for autotransplantation in the anterior maxilla *via* CBCT-based root width and crown-root angle measurements[J]. Dent Traumatol, 2023, 39 Suppl 1: 63-69. doi: 10.1111/edt.12847.

[44] Wei L, Wu S, Huang Z, et al. Autologous transplantation tooth guide design based on deep learning[J]. J Oral Maxillofac Surg, 2024, 82(3): 314-324. doi: 10.1016/j.joms.2023.09.014.

[45] Sahoo HS, Kumar ARP, Durvasulu A, et al. Comparative analysis of diagnostic prediction and clinical reasoning of large language models in complex endodontic case scenarios[J]. J Dent, 2026, 166: 106309. doi: 10.1016/j.jdent.2025.106309.

[46] Mohammad-Rahimi H, Ourang SA, Pourhoseingholi MA, et al. Validity and reliability of artificial intelligence chatbots as public sources of information on endodontics[J]. Int Endod J, 2024, 57(3): 305-314. doi: 10.1111/iej.14014.

[47] Chang HM, Ko HH, Chi CW, et al. Prosthetic-driven autotransplantation with the assistance of medical image-processing software and a real-time navigation system: a case report[J]. Int J Periodontics Restorative Dent, 2024, 44(2): 197-203. doi: 10.11607/prd.6498.

[48] Li Y, Lin Z, Liu Y, et al. Fully guided system for position-predictable autotransplantation of teeth: a randomized clinical trial [J]. Int Endod J, 2025, 58(4): 550-565. doi: 10.1111/iej.14193.

[49] Wu Y, Chen JM, Xie FP, et al. Simulation of postoperative occlusion and direction in autotransplantation of teeth: application of computer-aided design and digital surgical templates[J]. Br J Oral Maxillofac Surg, 2019, 57(7): 638-643. doi: 10.1016/j.bjoms.2019.05.011.

[50] Lucas-Taulé E, Llaquet M, Muñoz-Peñalver J, et al. Fully guided tooth autotransplantation using a multidrilling axis surgical stent: proof of concept[J]. J Endod, 2020, 46(10): 1515-1521. doi: 10.1016/j.joen.2020.06.017.

[51] Zhang J, Han Y, Zhong H. Accuracy assessment between computer-guided surgery planning and actual tooth position during tooth autotransplantation[J]. Dent Traumatol, 2024, 40(6): 649-657. doi: 10.1111/edt.12971.

[52] Tsukiboshi Y. Digital simulation and designing of a novel osteotomy guide for autotransplantation in the anterior region[J]. Dent Traumatol, 2025, 41 Suppl 1: 80-89. doi: 10.1111/edt.12994.

[53] Abella Sans F, Garcia-Font M, Nagendrababu V, et al. Accuracy of CAD-CAM surgically guided tooth autotransplantation using

guided templates and custom-designed osteotomes in human cadaver mandibles[J]. J Endod, 2023, 49(8): 1035-1043. doi: 10.1016/j.joen.2023.06.008.

[54] Riad Deglow E, Lazo Torres NZ, Gutiérrez Muñoz D, et al. Influence of static navigation technique on the accuracy of autotransplanted teeth in surgically created sockets[J]. J Clin Med, 2022, 11(4): 1012. doi: 10.3390/jcm11041012.

[55] Anssari Moin D, Derksen W, Verweij JP, et al. A novel approach for computer-assisted template-guided autotransplantation of teeth with custom 3D designed/printed surgical tooling. an *ex vivo* proof of concept[J]. J Oral Maxillofac Surg, 2016, 74(5): 895-902. doi: 10.1016/j.joms.2016.01.033.

[56] Slutzky-Goldberg I, Oren D, Faibishevsky V, et al. Enhanced socket preparation during autotransplantation: a new treatment protocol[J]. Quintessence Int, 2023, 54(2): 142-148. doi: 10.3290/j.qi.b3649031.

[57] 侯锐, 惠小勇, 许广杰, 等. 供牙三维打印模型在自体牙移植围手术期应用的临床观察[J]. 中华口腔医学杂志, 2020, 55(9): 647-653. doi: 10.3760/cma.j.cn112144-20200204-00033.
Hou R, Hui XY, Xu GJ, et al. Clinical observation of three-dimensional printing donor tooth model in peri-operative period of autotransplantation of tooth[J]. Chin J Stomatol, 2020, 55(9): 647-653. doi: 10.3760/cma.j.cn112144-20200204-00033.

[58] Lee SJ, Jung IY, Lee CY, et al. Clinical application of computer-aided rapid prototyping for tooth transplantation[J]. Dent Traumatol, 2001, 17(3): 114-119. doi: 10.1034/j. 1600-9657.2001.017003114.x.

[59] Lee CKJ, Foong KWC, Sim YF, et al. Evaluation of the accuracy of cone beam computed tomography (CBCT) generated tooth replicas with application in autotransplantation[J]. J Dent, 2022, 117: 103908. doi: 10.1016/j.jdent.2021.103908.

[60] Han S, Wang H, Chen J, et al. Application effect of computer-aided design combined with three-dimensional printing technology in autologous tooth transplantation: a retrospective cohort study[J]. BMC Oral Health, 2022, 22(1): 5. doi: 10.1186/s12903-021-02030-z.

[61] Chi J, Yin L, Ma S, et al. 3D printed guides and finite element analysis in dental autotransplantation: biomechanical efficiency and clinical workflow optimization[J]. Dent Traumatol, 2026, 42(1): 104-113. doi: 10.1111/edt.13087.

[62] Plakwicz AM, Majdanik-Bojarczuk W, Czochrowska EM, et al. Survey of patients and parents on the autotransplantation of developing premolars to replace traumatised maxillary incisors[J]. Dent Traumatol, 2023, 39 Suppl 1: 90-98. doi: 10.1111/edt.12848.

[63] Yu HJ, Jia P, Lv Z, et al. Autotransplantation of third molars with completely formed roots into surgically created sockets and fresh extraction sockets: a 10-year comparative study[J]. Int J Oral Maxillofac Surg, 2017, 46(4): 531-538. doi: 10.1016/j.ijom.2016.12.007.

[64] Ainiwaer A, Gong Z, Zuolipahaer Z, et al. Midterm outcomes of autogenous mature third molars transplantation into surgically created sockets: a retrospective cohort study[J]. Dent Traumatol, 2024, 40(5): 573-585. doi: 10.1111/edt.12958.

[65] Xia JJ, Ge ZY, Fu XH, et al. Autotransplantation of third molars with completely formed roots to replace compromised molars with the computer-aided rapid prototyping[J]. J Esthet Restor Dent, 2020, 32(3): 265-271. doi: 10.1111/jerd.12573.

[66] Chai HY, Lin KH, Huang YW, et al. Use of three-dimensional-printed tooth replica for autogenous tooth transplantation at an anatomically challenging site[J]. J Dent Sci, 2023, 18(1): 472-474. doi: 10.1016/j.jds.2022.08.019.

[67] Chou YC, Chen WH, Lee HN, et al. Navigation-guided autotransplantation: a novel technique for precise and predictable tooth placement[J]. J Dent Sci, 2026, 21(1): 599-603. doi: 10.1016/j.jds.2025.08.027.

[68] Liu C, Li Y, Wang F, et al. Development and validation of a robotic system for milling individualized jawbone cavities in oral and maxillofacial surgery[J]. J Dent, 2024, 150: 105380. doi: 10.1016/j.jdent.2024.105380.

[69] Wu XY, Shi JY, Qiao SC, et al. Accuracy of robotic surgery for dental implant placement: a systematic review and meta-analysis[J]. Clin Oral Implants Res, 2024, 35(6): 598-608. doi: 10.1111/clr.14255.

[70] Liu Y, Song J, Chen X, et al. Robot-assisted autotransplantation of third molars in the maxilla: two case reports[J]. Front Oral Health, 2025, 6: 1661873. doi: 10.3389/froh.2025.1661873.

[71] Chen G, Ma Z, Luo Z, et al. Feasibility and precision of robot-assisted autotransplantation of teeth: an *in vitro* study[J]. Int Endod J, 2026, 59(4): 632-642. doi: 10.1111/iej.70082.

[72] Tsukiboshi M, Tsukiboshi C, Levin L. A step-by step guide for autotransplantation of teeth[J]. Dent Traumatol, 2023, 39 Suppl 1: 70-80. doi: 10.1111/edt.12819.

[73] Andreasen JO. Pulp and periodontal tissue repair - regeneration or tissue metaplasia after dental trauma. A review[J]. Dent Traumatol, 2012, 28(1): 19-24. doi: 10.1111/j.1600-9657.2011.01058.x.

[74] 黄定明, 李继遥, 徐欣. 意向性牙再植术的临床管理[J]. 中华口腔医学杂志, 2018, 53(6): 392-397. doi: 10.3760/cma.j.issn.1002-0098.2018.06.006.
Huang DM, Li JY, Xu X. Clinical management of the intentional tooth replantation[J]. Chin J Stomatol, 2018, 53(6): 392-397. doi: 10.3760/cma.j.issn.1002-0098.2018.06.006.

[75] Restrepo-Restrepo FA, Uribe-Jaramillo DF, Villa-Machado PA, et al. Retrospective follow-up assessment of risk variables influencing the outcome of autologous tooth transplantation[J]. J Endod, 2024, 50(6): 747-757. doi: 10.1016/j.joen.2024.02.021.

[76] Plotino G, Abella Sans F, Duggal MS, et al. European Society of Endodontology position statement: surgical extrusion, intentional replantation and tooth autotransplantation: European Society of Endodontology developed by[J]. Int Endod J, 2021, 54(5): 655-659. doi: 10.1111/iej.13456.

[77] Yang X, Yin L, Guo D, et al. Effectiveness of root canal therapy in auto-transplanted third molars: a systematic review, meta-analysis and case series report[J]. Clin Oral Investig, 2025, 29(4): 209. doi: 10.1007/s00784-025-06264-x.

[78] Kuo HY, Lo YJ, Huang YW. New era of tooth autotransplantation. Part I: thoughts on clinical aspects[J]. J Dent Sci, 2024, 19(1): 8-

10. doi: 10.1016/j.jds.2023.10.027.

[79] Huang J, Gan Y, Han S, et al. Outcomes of autotransplanted third molars with complete root formation: a systemic review and meta-analysis[J]. J Evid Based Dent Pract, 2023, 23(2): 101842. doi: 10.1016/j.jebdp.2023.101842.

[80] Tso KY, Chiu WC, Wu YH. Assessing the impact of apicoectomy on autotransplantation success rates: a six-year retrospective cohort study in Taiwan[J]. J Dent Sci, 2025, 20(4): 2273-2282. doi: 10.1016/j.jds.2025.05.031.

[81] Liao F, Wang H, Zhao J, et al. Effectiveness evaluation of autotransplanted teeth after performing extraoral endodontic surgery instead of conventional root canal therapy[J]. BMC Oral Health, 2023, 23(1): 1005. doi: 10.1186/s12903-023-03733-1.

[82] Plakwicz P, Cudziło D, Czochrowska EM, et al. Pulp revascularization after autotransplantation of the mandibular canines with partially resected roots: report of 5 cases with follow-ups between 26 and 80 months[J]. J Endod, 2023, 49(5): 478-486. doi: 10.1016/j.joen.2023.03.006.

[83] Gaviño Orduña JF, García García M, Dominguez P, et al. Successful pulp revascularization of an autotransplantated mature premolar with fragile fracture apicoectomy and plasma rich in growth factors: a 3-year follow-up[J]. Int Endod J, 2020, 53(3): 421-433. doi: 10.1111/iej.13230.

[84] Gonzalez-Ocasio J, Stevens M. Autotransplantation of third molars with platelet-rich plasma for immediate replacement of extracted non-restorable teeth: a case series[J]. J Oral Maxillofac Surg, 2017, 75(9): 1833.e1-1833.e6. doi: 10.1016/j.joms.2017.04.018.

[85] Ainiwaer A, Tuerdi M, Zuolipahaer Z, et al. Combined application of artificial bone powders and concentrated growth factor membranes on the autotransplantation of mature third molars: a 5-year retrospective case series[J]. Dent Traumatol, 2024, 40(6): 636-648. doi: 10.1111/edt.12974.

[86] Chen L, Cheng J, Cai Y, et al. Efficacy of concentrated growth factor (CGF) in the surgical treatment of oral diseases: a systematic review and meta-analysis[J]. BMC Oral Health, 2023, 23(1): 712. doi: 10.1186/s12903-023-03357-5.

[87] Genc A, Gedik B, Erdem MA, et al. Short-term effects of platelet-rich plasma on the clinical outcomes of dental autotransplantation in teeth with complete and incomplete root development: a randomized cohort study[J]. Int J Med Sci, 2025, 22(14): 3617-3624. doi: 10.7150/ijms.113282.

[88] Pedrinaci I, Calatrava J, Couso-Queiruga E, et al. Tooth autotransplantation with adjunctive application of enamel matrix derivatives using a digital workflow: a prospective case series[J]. J Dent, 2024, 148: 105131. doi: 10.1016/j.jdent.2024.105131.

[89] Murata M, Nakanishi Y, Kusano K, et al. Immediate tooth autotransplantation with root canal filling and partially demineralized dentin/cementum matrix into congenital missing tooth region[J]. J Funct Biomater, 2022, 13(2): 82. doi: 10.3390/jfb13020082.

[90] Jang Y, Choi YJ, Lee SJ, et al. Prognostic factors for clinical outcomes in autotransplantation of teeth with complete root formation: survival analysis for up to 12 years[J]. J Endod, 2016, 42(2): 198-205. doi: 10.1016/j.joen.2015.10.021.

[91] Ferraresso LFOT, Besegato JF, Maler GL, et al. Tooth autotransplantation and resin composite reshaping as a multidisciplinary approach for treating dental agenesia: a 10-year follow-up[J]. J Esthet Restor Dent, 2025, 37(2): 307-313. doi: 10.1111/jerd.13284.

[92] Lim SW, Choi IS, Lee BN, et al. Periodontal ligament preloading and rapid prototyping of the donor tooth in the autotransplantation of premolars with complete root formation[J]. Am J Orthod Dentofacial Orthop, 2022, 162(1): 108-121. doi: 10.1016/j.ajodo.2021.01.039.

[93] Yang Y, Bai Y, Li S, et al. Effect of early orthodontic force on periodontal healing after autotransplantation of permanent incisors in beagle dogs[J]. J Periodontol, 2012, 83(2): 235-241. doi: 10.1902/jop.2011.110099.

[94] Declerck E, EzEldeen M, Wyatt J, et al. Application of orthodontic force in autotransplanted teeth: a longitudinal study[J]. Clin Oral Investig, 2025, 29(1): 69. doi: 10.1007/s00784-024-06106-2.

[95] Sicilia-Pasos J, Kewalramani N, Peña-Cardelles JF, et al. Autotransplantation of teeth with incomplete root formation: systematic review and meta-analysis[J]. Clin Oral Investig, 2022, 26(5): 3795-3805. doi: 10.1007/s00784-022-04435-8.

[96] Tan BL, Tong HJ, Narashimhan S, et al. Tooth autotransplantation: an umbrella review[J]. Dent Traumatol, 2023, 39 Suppl 1: 2-29. doi: 10.1111/edt.12836.

[97] Xia J, Ge Z, Zhang Y, et al. Prognostic factors for autotransplanted third molars with completely formed roots: a retrospective cohort study[J]. J Am Dent Assoc, 2025, 156(1): 46-56. doi: 10.1016/j.adaj.2024.10.004.

[98] Akhlef Y, Hosseini M, Schwartz O, et al. Autotransplantation of premolars to the anterior maxilla: a long-term retrospective cohort study of survival, success, esthetic, and patient-reported outcome with up to 38-year follow-up[J]. Dent Traumatol, 2025, 41(3): 322-337. doi: 10.1111/edt.13025.

[99] Lucas-Taulé E, Llaquet M, Muñoz-Peñalver J, et al. Mid-term outcomes and periodontal prognostic factors of autotransplanted third molars: a retrospective cohort study[J]. J Periodontol, 2021, 92(12): 1776-1787. doi: 10.1002/JPER.21-0074.

[100] Andreasen JO, Paulsen HU, Yu Z, et al. A long-term study of 370 autotransplanted premolars. Part I. Surgical procedures and standardized techniques for monitoring healing[J]. Eur J Orthod, 1990, 12(1): 3-13. doi: 10.1093/ejo/12.1.3.

（编辑　张琳）

Open Access
This article is licensed under a Creative Commons Attribution 4.0 International License.
Copyright © 2026 by Editorial Department of Journal of Prevention and Treatment for Stomatological Diseases

官网