[DOI]10.12016/j.issn.2096-1456.202550434

·综述·

# 富含细胞外黏液的唾液腺肿瘤诊断及鉴别诊断

关苇杭，刘苍维，郭昊，李金薇，王丹丹，乔春燕，聂孟冬，曲明，史册
吉林大学口腔医院口腔病理科，吉林省牙发育及颌骨重塑与再生重点实验室，吉林 长春（130021）

【摘要】 本文系统综述了以大量细胞外黏液为主要或显著特征的唾液腺肿瘤诊断及鉴别诊断要点，明确了核心鉴别特征。“富含细胞外黏液”在此特指黏液成为肿瘤的主要构成成分，而非局灶性或少量存在，这种现象与独特的组织发生学机制相关：一方面源于特定基因突变（如黏液腺癌中的AKT1 E17K）促使导管上皮分化为黏液细胞并大量分泌黏液；另一方面则源于肌上皮细胞分泌糖胺聚糖形成黏液样间质。含大量细胞外黏液的唾液腺肿瘤包括黏液性囊腺瘤、乳头状涎腺瘤样导管内乳头状瘤、黏液性肌上皮瘤、间质富含黏液的多形性腺瘤、黏液腺癌、低级别黏液表皮样癌、富黏液型唾液腺导管癌及肠型腺癌。此类肿瘤在诊断上面临双重挑战：大量黏液既可作为某些肿瘤的典型特征，也可能在其他肿瘤中掩盖其诊断性结构，导致组织学形态重叠与特征区域隐匿。核心鉴别要点包括：组织学上需仔细辨识被黏液掩盖的典型结构（如黏液表皮样癌中的表皮样细胞、唾液腺导管癌的大汗腺特征）；在免疫组化方面，应用CK20可鉴别肠型腺癌（阳性）与黏液腺癌（阴性），而应用雄激素受体可以鉴别唾液腺导管癌（阳性）与黏液表皮样癌（阴性）；分子检测对确诊具有关键作用（如AKT1 E17K突变见于黏液腺癌，MAML2重排见于黏液表皮样癌，MEF2C：：SS18融合见于微分泌性腺癌）。本文系统梳理了富含细胞外黏液唾液腺肿瘤的核心病理特征与鉴别要点，以期为临床病理诊断提供实用参考。

【关键词】 唾液腺肿瘤；　黏液；　诊断；　黏液腺癌；　黏液性囊腺瘤；　多形性腺瘤；　黏液表皮样癌；　肌上皮瘤；　免疫组织化学；　病理学
【中图分类号】 R78　【文献标志码】 A　【文章编号】 2096-1456（2026）06-0606-14
【引用著录格式】 关苇杭，刘苍维，郭昊，等. 富含细胞外黏液的唾液腺肿瘤诊断及鉴别诊断[J]. 口腔疾病防治, 2026, 34(6): 606-619. doi:10.12016/j.issn.2096-1456.202550434.

微信公众号

**Diagnosis and differential diagnosis of mucin-rich salivary gland tumors**

GUAN Weihang, LIU Cangwei, GUO Hao, LI Jinwei, WANG Dandan, QIAO Chunyan, NIE Mengdong, QU Ming, SHI Ce. Department of Oral Pathology, Hospital of Stomatology, Jilin University & Jilin Provincial Key Laboratory of Tooth Development and Bone Remodeling, Changchun 130021, China
Corresponding author: QU Ming, Email: quming808@163.com; SHI Ce, Email: ceshi@jlu.edu.cn

【Abstract】 This paper systematically elaborates on the key points of diagnosis and differential diagnosis of salivary gland tumors characterized by a substantial amount of extracellular mucus as a main or prominent feature, and clarifies the core differential features. The term "mucus-rich" specifically denotes that mucus is a major component of the tumor, rather than a focal or minor one. This phenomenon is associated with distinct histogenetic mechanisms: it may result from specific genetic mutations (e.g., AKT1 E17K in mucinous adenocarcinoma) that drive ductal epithelial differentiation into mucus-secreting cells, or from myoepithelial cells secreting glycosaminoglycans that form a myxoid stroma. Salivary gland tumors with abundant extracellular mucus include mucinous cystadenoma, sialadenoma papilliferum-like intraductal papillary tumors, mucinous myoepithelioma, pleomorphic adenoma with mucin-rich stroma, mucinous adeno-

【收稿日期】2025-09-19；【修回日期】2026-01-28
【基金项目】吉林省财政厅科技项目（JCSZ2021893-36）；吉林省自然科学基金项目（YDZJ202201ZYTS039）；中央高校基本科研业务费专项资金
【作者简介】关苇杭，住院医师，硕士研究生在读，Email：2227484734@qq.com
【通信作者】曲明，初级技师，硕士，Email：quming808@163.com；史册，主任医师，博士，Email：ceshi@jlu.edu.cn

carcinoma, low-grade mucoepidermoid carcinoma, mucin-rich salivary duct carcinoma and intestinal-type adenocarcinoma. The diagnosis of these tumors is complicated by the dual nature of extracellular mucus: while it is a defining feature of some entities, it can also obscure key diagnostic architectural features in others, leading to histological overlap and inconspicuous diagnostic areas. Given the frequent histological morphological overlap among these tumors, immunohistochemical findings and molecular characteristics have emerged as crucial differential diagnostic criteria. Core differential diagnostic points include the following: histologically, there must be meticulous identification of typical structures obscured by mucin (such as squamoid cells in mucoepidermoid carcinoma and apocrine features in salivary duct carcinoma); in immunohistochemical staining, CK20 is useful for distinguishing intestinal-type adenocarcinoma (positive) from mucinous adenocarcinoma (negative), while androgen receptor aids in differentiating salivary duct carcinoma (positive) from mucoepidermoid carcinoma (negative); and molecular testing plays a critical role in definitive diagnosis (e.g., the AKT1 E17K mutation for mucinous adenocarcinoma, MAML2 rearrangement for mucoepidermoid carcinoma, and MEF2C::SS18 fusion for microsecretory adenocarcinoma). This paper systematically summarizes the core pathological features and differential diagnostic points of mucin-rich salivary gland tumors, aiming to provide a practical reference for clinical pathological diagnosis.

**【Key words】** salivary gland tumors; mucus; diagnosis; mucinous adenocarcinoma; mucinous cystadenoma; pleomorphic adenoma; mucoepidermoid carcinoma; myoepithelioma; immunohistochemistry; pathology

**J Prev Treat Stomatol Dis, 2026, 34(6): 606-619.**

**【Competing interests】** The authors declare no competing interests.

This study was supported by the grants from Jilin Province Department of Finance (No. JCSZ2021893-36), Jilin Province Natural Science Foundation Project (No. YDZJ202201ZYTS039) and Special Funds for Basic Research of Central Universities.

大量细胞外黏液可见于多种原发性唾液腺肿瘤，尽管正常唾液腺及许多肿瘤均可产生黏液，但本文所讨论的“富含细胞外黏液”并非指局灶、少量的黏液分泌，而是指黏液成为肿瘤的主要或显著构成成分，并可能主导其组织学形态和生物学行为。从组织发生学上看，这种现象可能与以下机制相关：①分子机制改变导致肿瘤细胞定向分化：特定基因突变如黏液腺癌（mucinous adenocarcinoma，MA）中的AKT1 E17K突变，可能直接调控黏液相关基因的表达和分泌过程，来源于导管上皮的肿瘤细胞分化为黏液细胞，大量合成和分泌黏液，如黏液性囊腺瘤（mucinous cystadenoma，MCA）和MA；②肿瘤细胞分泌糖胺聚糖形成黏液样结构：肿瘤细胞来源于闰管或闰管储备细胞分化为肌上皮细胞，分泌糖胺聚糖等物质，形成假性黏液样间质，如多形性腺瘤（pleomorphic adenoma，PA）和肌上皮瘤（myoepithelioma，ME）。因此，富含细胞外黏液的肿瘤与那些仅含少量黏液或细胞内黏液的肿瘤存在本质差异。这些差异不仅体现在形态学上，更反映了其独特的组织学发生、分子通路和潜在的临床行为，这正是对其进行独立归类、诊断和鉴别诊断的价值所在。大量细胞外黏液既可作为某些肿瘤的典型特征，如MCA、MA及低级别黏液表皮样癌（low-grade mucoepidermoid carcinoma，LG-MEC），亦可仅代表其他肿瘤的形态学变异，包括ME、乳头状涎腺瘤样导管内乳头状瘤（sialadenoma papilliferum-like intraductal papillary tumor，SP-IPT）、PA、唾液腺导管癌（salivary duct carcinoma，SDC）、分泌性癌（secretory carcinoma，SC）及肠型腺癌（intestinal-type adenocarcinoma）。此类肿瘤在组织学上常表现为丰富的黏液细胞或印戒细胞伴大量细胞外黏液，而其具有诊断价值的特征性区域可能较为隐匿。组织学形态的重叠性与诊断性区域的隐匿性构成主要诊断挑战，加之罕见黏液亚型缺乏明确定义且文献报道有限，进一步加剧了诊断难度。大量细胞外黏液在唾液腺肿瘤诊断中具有双重性：它既是某些肿瘤的特征性成分，也可能因掩盖典型结构而干扰诊断。因此，镜检关键在于仔细甄别，寻找被黏液隐藏的典型区域。本文根据第5版WHO《头颈部肿瘤病理学和遗传学分类》（下文简称为WHO头颈部肿瘤分类）及文献中涵盖的富含细胞外黏液唾液腺肿瘤，对其组织学表现、免疫组化结构及分子机制进行综述，总结诊断与鉴别诊断思路为临床病理诊断提供参考。

## 1　富含细胞外黏液唾液腺良性肿瘤

### 1.1　黏液性囊腺瘤

唾液腺囊腺瘤(cystadenoma of the salivary glands)是一种罕见的良性肿瘤,以多囊性生长为特征[1-2]。它占所有唾液腺肿瘤的1%～4%,大小唾液腺发病率相近[3],女性多于男性[4],50~70岁多见[5]。

囊腺瘤界限清楚但是包膜常不完整,缺乏高度特异性的组织学特征。镜下可见肿瘤内衬不同类型上皮细胞,伴有不同程度的乳头状结构[6]。内衬上皮可见柱状细胞、立方细胞和嗜酸细胞(oncocytic cells)以不同比例混合存在。黏液性上皮、鳞状上皮和纤毛上皮少见。囊腺瘤缺乏细胞异型性、核分裂活性及浸润性生长。

MCA作为一种罕见的囊腺瘤亚型,主要由黏液细胞构成。肿瘤体积常较大,为多房含黏液肿瘤。光镜下可见大小不等的多个囊腔样结构,内衬含丰富黏液的高柱状黏液上皮细胞,表现为乳头状生长,囊腔内含丰富的黏液[7]。

囊腺瘤免疫组化染色显示内衬上皮细胞表达细胞角蛋白8/18(cytokeratin 8/18,CK8/18),下方基底细胞层表达p63[8]。S100和SOX10通常阴性或仅局灶表达。

MCA的诊断需重点排除MA和LG-MEC。与黏液性腺癌相鉴别,MCA无浸润性生长模式、显著细胞异型性及病理性核分裂象。与LG-MEC相鉴别,LG-MEC p63的表达模式与MCA存在显著差异,即囊壁内衬的基底细胞和靠近腔面的基底上层细胞均表达p63。此外,LG-MEC镜下可见微小浸润现象如实性上皮结节和微囊性结构,分子检测可见MAML2基因(mastermind-like transcriptional activator 2,MAML2)融合。

囊腺瘤可通过手术切除治愈,复发率低。偶有文献报道囊腺瘤恶变为浸润癌的病例[9]。

### 1.2　乳头状涎腺瘤样导管内乳头状瘤

SP-IPT是一种罕见的唾液腺肿瘤,其组织学表现类似于乳头状涎腺瘤(sialadenoma papilliferum,SP)[10],呈现出类似于SP导管成分的乳头状—囊性生长方式但缺乏SP的外生性鳞状上皮[11](图1)。目前关于SP-IPT的报道较少,见于舌及磨牙后区,好发于老年患者;因病例数较少,其性别倾向性尚不明确[12]。

SP-IPT典型组织学为病变表面被平坦的黏膜鳞状上皮覆盖,缺乏外生性鳞状上皮,黏膜下可见界限清楚多囊性结节[13-14]。囊内乳头状增生上皮周围绕基底细胞。部分病例存在BRAF原癌基因(B-Raf proto-oncogene,BRAF)所编码的丝氨酸/苏氨酸蛋白激酶在第600位发生缬氨酸至谷氨酸的置换(BRAF V600E)[15-16],少数为HRAS基因(harvey rat sarcoma viral oncogene homolog,HRAS)的Q61R突变或共突变。有病例报道SP-IPT存在形态类似MA的区域[17]。部分MA病例可见BRAF V600E突变,表明部分MA可能起源于SP-IPT。

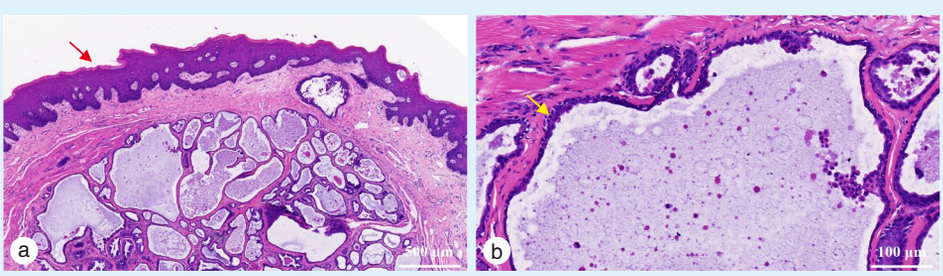


a: HE staining showing that in sialadenoma papilliferum-like intraductal papillary tumors there are a lack of exophytic mucosal squamous epithelium (as indicated by the arrow); b: HE staining showing that in sialadenoma papilliferum-like intraductal papillary tumors, there is a multicystic structure with papillary infoldings in the deeper portion of the lesion (as indicated by the arrow). These images were from the Department of Pathology at the Stomatological Hospital of Jilin University

Figure 1　HE staining findings of a sialadenoma papilliferum-like intraductal papillary tumor

**图1**　乳头状涎腺瘤样导管内乳头状瘤的HE染色

### 1.3　黏液性/分泌性肌上皮瘤

ME是一种良性唾液腺肿瘤,几乎完全由肌上皮细胞及其产生的间质构成[18]。ME占所有唾液腺肿瘤的1%以下[19],常见于腮腺[20]和腭部[21-24]。通常表现为无痛性缓慢生长的肿块[25]。发病年龄跨度广[26],性别分布均等[27-30]。

ME边界清晰且常有包膜[31]。肌上皮细胞形态可表现为梭形、上皮样、浆细胞样或透明状[32-34]，排列方式呈巢状、条索状、小梁状或网状。间质可为黏液样、胶原性(collagenous)或富于血管[35]。

黏液性/分泌性肌上皮瘤作为一种罕见报道的ME变异型[36-39]，特征为细胞内含黏液物质[40]，可呈现印戒样细胞形态(图2)。肿瘤细胞胞质丰富，呈嗜酸性至泡沫状灰蓝色，常见细胞内黏液；核轻度多形性，染色质细腻胡椒盐样，核仁不明显[39]。黏液性/分泌性肌上皮瘤表达≥1种肌上皮标志物[39]。目前认为黏液性/分泌性肌上皮瘤生物学行为良性至低度恶性[41]，但需更多病例明确其特性。

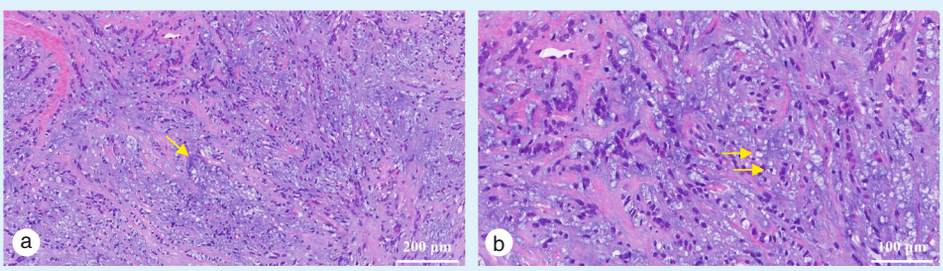


a: HE staining showing abundant extracellular mucin (as indicated by the arrow); b: HE staining showing that the tumor cells exhibited prominent cytoplasmic clearing due to intracellular mucin accumulation, a feature that could manifest as a signet-ring cell morphology (as indicated by the arrows). These images were from the Department of Pathology at the Stomatological Hospital of Jilin University

Figure 2　HE staining findings of mucinous/secretory myoepithelioma

**图2**　黏液性/分泌性肌上皮瘤的HE染色

黏液性/分泌性肌上皮瘤需与LG-MEC、含印戒细胞或黏液湖的MA及富黏液型唾液腺导管癌(mucin-rich salivary duct carcinoma, mSDC)鉴别。LG-MEC虽含黏液细胞，但同时含有表皮样细胞和中间细胞且肌上皮标志物阴性；MA可以通过肌上皮标志物阴性鉴别；mSDC含大汗腺样细胞学特征且表达AR。此外，还需要结合临床排除转移性肿瘤。

### 1.4　多形性腺瘤

PA是一种以细胞形态和组织结构多样化为特征的良性上皮性肿瘤[42]。作为最常见的唾液腺肿瘤[43]，PA主要发生于腮腺[44-45]，其次为口腔(oral cavity)[46]及下颌下腺[47-52]，女性多于男性[53, 54]，常见于30~50岁[53, 55-56]。

PA的组织学特征是其形态学的多样性，具有双层导管状、肌上皮细胞及间质的混合[57]。典型表现为导管细胞与肌上皮细胞混合增生[58-59]，通常嵌于软骨黏液样[60]或纤维性间质成分中[60-61]。

免疫组化染色显示PA主要表达黏蛋白1(mucin 1, MUC1)(主要标记管状结构腔缘[62-63])和黏蛋白6(mucin 6, MUC6)，而黏蛋白2(mucin 2, MUC2)、黏蛋白4(mucin 4, MUC4)、黏蛋白5AC(mucin 5AC, MUC5AC)表达量较低。MUC1/DF3的表达可能与复发风险增加[64]及PA癌变相关[65]。

肿瘤的包膜大多完整，但在黏液样组织的表面常出现包膜消失[66]。少数PA尤其复发的PA中，黏液样组织可称为肿瘤的主要成分(图3)。黏液样组织中的细胞呈星形或梭形，排列疏松，胞质突彼此相连成网状，黏液成分为结缔组织性黏液。

间质富含黏液的PA需要与LG-MEC和ME相鉴别，与LG-MEC相比，PA可见成熟角化珠、存在肌上皮分化，以及MAML2基因重排阴性；ME与PA相比罕见或缺失导管成分。

## 2　富含细胞外黏液唾液腺恶性肿瘤

### 2.1　黏液腺癌

MA是一种极为罕见的原发性唾液腺腺癌，其特征为具有显著的细胞内和/或细胞外黏液，而缺乏其他类型肿瘤的诊断特征，并且通常与*AKT1*基因改变相关。MA最常见于口腔内的小唾液腺[9, 67-68]，性别分布均等[9, 67-68]，好发年龄为80岁左右。目前被归为MA的肿瘤其命名长期存在争议，曾使用黏液性囊腺癌、胶样癌、印戒细胞癌、肠型腺癌及乳头状腺癌等多种术语。由于该肿瘤罕见，已报道病例数有限，加之其形态学谱系广泛，学界既往难以界定这些病变应归属于单一疾病实体还是多个独立病种。2005年第3版WHO头颈部肿瘤分类虽设立了MA类别(特指胶样型)，但2017年第4版WHO分类则将所有未能明确归类的富黏液腺癌均归类为“非特指型腺癌(adenocarcinoma

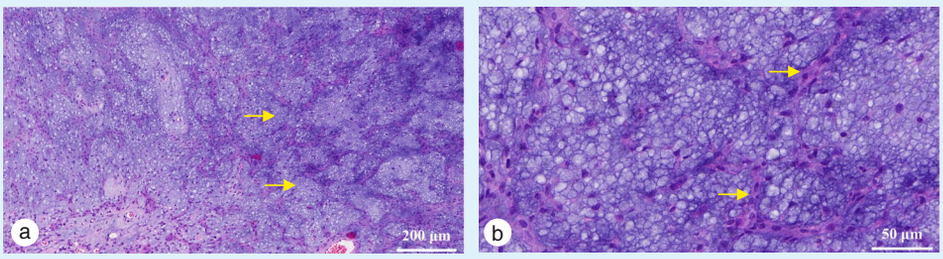


a: HE staining showing abundant extracellular mucin (as indicated by the arrows); b: HE staining showing that the tumor cells exhibited a stellate or spindle-shaped morphology and were loosely arranged, with interconnecting cytoplasmic processes forming a reticulated network (as indicated by the arrows). These images were from the Department of Pathology at the Stomatological Hospital of Jilin University

Figure 3　HE staining findings of pleomorphic adenoma

**图3**　多形性腺瘤的HE染色

not otherwise specified)"类别,其依据在于黏液分化被视为非特异性特征。在第5版WHO中将具有共同的AKT1 E17K基因突变的乳头样、胶样和印戒细胞样恶性肿瘤均归类为MA。

MA的组织学表现高度异质,唯一共性为大量的细胞内和/或细胞外黏液,肉眼观肿瘤呈实性或囊性,切面呈胶冻样。镜下可见杯状细胞样空泡、顶端黏液帽、胃小凹型胞质黏液滴及间质黏液湖。肿瘤结构多变,可呈乳头状、胶样(黏液湖)或印戒细胞样,其中40%MA表现为混合型结构[67-69]。大多数肿瘤可见复杂的或简单的乳头状结构突入囊腔内(图4a&4b)。胶样(黏液湖)结构表现为肿瘤细胞巢悬浮于黏液湖中。最罕见的结构是肿瘤中含有离散的印戒细胞。免疫组织化学染色显示NKX3.1和CK7阳性(图4c),CK20(图4d)、CDX2、p63、p40、TTF1、S100、calponin、SMA和AR阴性[68-69]。Rooper等[68]研究表明,无论哪种组织形态的MA,均可发生AKT1 E17K基因突变。在导管内乳头状黏液性肿瘤(intraductal papillary mucinous neoplasm, IPMN)中也有同样的基因突变。IPMN是一种新命名的疾病,类似于胰腺导管黏液性病变(pancreatic duct mucinous lesions),组织学特点为导管上皮增殖且伴有黏液成分,目前其在唾液腺肿瘤中的分类尚不确定[70]。Feitosa等[71]研究表明,IPMN可能不同于乳头状唾液腺瘤(sialadenoma papilliferum),前者含有AKT1 E17K突变,后者含有BRAF V600E突变。然而,IPMN是独立于MA的与导管乳头状瘤(ductal papilloma)有关的疾病,还是MA的前驱病变,抑或MA的导管内变异型,目前尚不清楚。

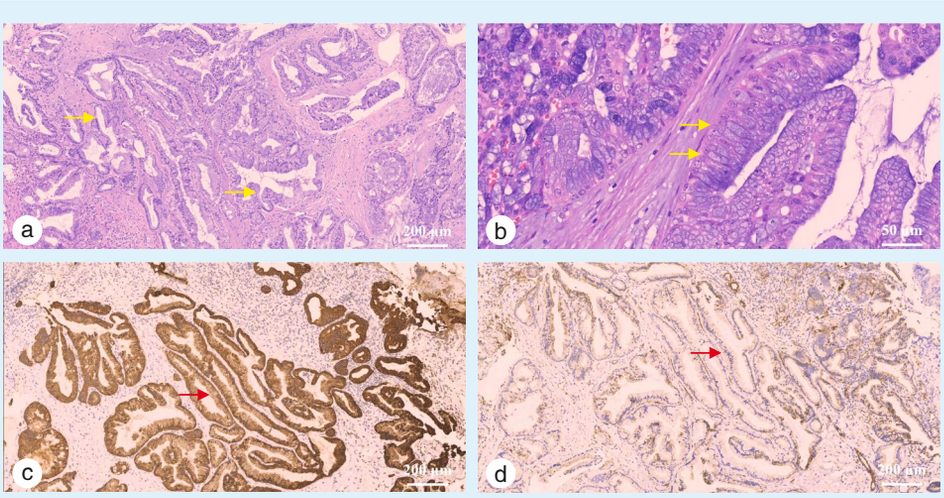


a: HE staining showing complex mucin-producing papillary fronds projecting into cystic spaces (as indicated by the arrows); b: HE staining showing abundant mucin (as indicated by the arrows); c: immunohistochemical staining demonstrating that the cystic structures were lined by a continuous layer of CK7-positive mucinous cells; d: immunohistochemical staining showing that the cystic structures were lined by a continuous layer of mucinous cells that were negative for CK20. These images were from the Department of Pathology at the Stomatological Hospital of Jilin University

Figure 4　Morphological and immunohistochemical features of mucinous adenocarcinoma

**图4**　黏液腺癌形态学和免疫表型特点

在诊断MA时，需严格排除其他产生黏液的唾液腺恶性肿瘤，主要包括以下类型：LG-MEC组织学特征为存在表皮样细胞和中间细胞，并且表达p63/p40；mSDC具有大汗腺样细胞学特征，免疫组织化学染色显示AR阳性；分泌性肌上皮癌肿瘤细胞排列成巢状或索状结构，免疫组织化学染色显示S100、Calponin或SMA阳性[37]。此外，必须通过全面的临床评估排除来自胃肠道、胰胆管系统或肺的转移性腺癌。

### 2.2　微分泌性腺癌

微分泌性腺癌（microsecretory adenocarcinoma，MSA）是一种低度恶性肿瘤，具有闰管样表型（phenotype）及特征性MEF2C::SS18基因融合[72-73]。MSA迄今报道病例不足30例。绝大多数MSA发生于口腔，最常见于腭部及颊黏膜[74]，好发于中年女性[75-76]。

MSA并不像本文中其他肿瘤一样富含黏液，但是镜下可见管腔内有类似黏液样物质的嗜碱性分泌物（图5），导致在临床中易与MA相混淆[17]。MSA由Bishop等于2019年首次提出，并作为唾液腺肿瘤的新病种被正式纳入第5版WHO头颈部肿瘤分类。

MSA具有高度一致的组织学特征[77]：以微囊性结构为主的生长模式，偶见筛状或条索状结构；均匀一致的闰管样肿瘤细胞，胞质稀疏呈嗜酸性至透明状，核分裂象罕见[78]；管腔内有丰富的嗜碱性分泌物[79]；推挤状边界伴轻微浸润性生长，可侵犯邻近骨骼肌、脂肪或小唾液腺。

MSA免疫组织化学染色显示S100和SOX10弥漫强阳性[75]，部分病例p63阳性[80]，p40、mammaglobin、calponin阴性，部分病例SMA局灶阳性。

MSA需要与MA和SC鉴别。MA不表达S100、SOX10、p63；SC胞质更为丰富，可见粉染分泌物，表达mammaglobin，且携带特征性基因融合（多为ETV6::NTRK3）。

MSA生物学行为通常表现为惰性，可通过手术切除治愈，远处或区域转移病例罕见。

### 2.3　低级别黏液表皮样癌

黏液表皮样癌（mucoepidermoid carcinoma，MEC）是一种恶性唾液腺肿瘤，其特征在于由黏液细胞、中间细胞及表皮样肿瘤细胞构成，并形成囊性与实性并存的生长模式。MEC好发于腮腺[81]，年龄分布广泛，女性略多[82]。

LG-MEC多表现为边界清楚、部分囊性，可见成簇的黏液细胞和大量细胞外黏液（图6）。

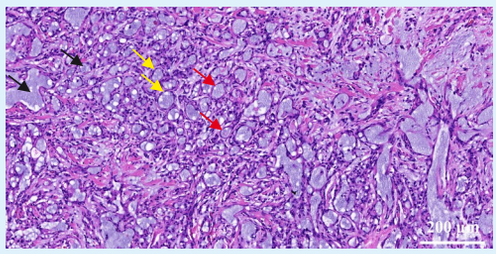

HE staining revealing a predominantly microcystic growth pattern. The tumor was composed of uniform intercalated duct-like tumor cells with cytoplasm that ranged from eosinophilic to clear. Mitotic figures were rare. The lumens contained abundant basophilic secretions. Red arrows indicate the microcystic structures; yellow arrows indicate the intercalated duct-like tumor cells; and black arrows indicate the abundant basophilic secretions within the lumens. The image provided by courtesy of Prof. Jiang Li, Department of Oral Pathology, Shanghai Ninth People's Hospital, Shanghai Jiao Tong University School of Medicine

Figure 5　HE staining findings of microsecretory adenocarcinoma

**图5**　微分泌性腺癌的HE染色

免疫组化染色显示LG-MEC以MUC4、MUC5AC、黏蛋白5B（mucin 5B，MUC5B）及MUC6高表达于黏液细胞及细胞外黏液为特征；MUC4与MUC6的缺失与高级别转化、淋巴结转移及早期复发显著相关[83-84]，联合检测MUC1、MUC4与MUC6可早期识别预后不良的LG-MEC患者。

LG-MEC需要与MA、MCA和SDC鉴别诊断，关键在于找到更具典型MEC形态的区域——即混合存在表皮样细胞和中间细胞，免疫组织化学染色显示p40/p63局灶阳性[85-86]，同时存在MAML2基因融合[87-88]。

### 2.4　富黏液型唾液腺导管癌

SDC是一种侵袭性唾液腺恶性肿瘤，形态学类似于乳腺导管癌，具有顶浆分泌特征。好发于大唾液腺[89-92]，男性多见，50~70岁高发[71, 93]。

SDC镜下可见大汗腺特征（apocrine features）[94]，肿瘤细胞排列呈实性、筛状和乳头—囊性结构，常伴有粉刺样坏死（comedonecrosis）[95]。肿瘤细胞核大、多形性明显，核仁显著；胞质丰富、嗜酸性[93-94]。常见淋巴管、血管（lymphovascular invasion）和神经周侵犯（perineural invasion）。

SDC免疫组化染色显示AR阳性[94]。约33%的SDC可见Erb-B2受体酪氨酸激酶2（Erb-B2 receptor tyrosine kinase 2，ERBB2）的弥漫性强阳

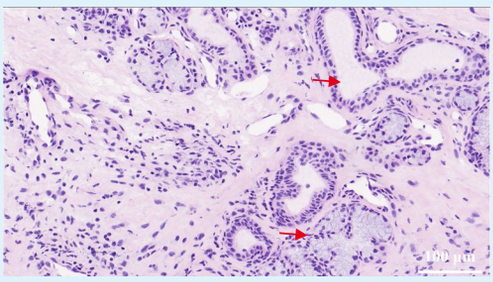

HE staining showing that in low-grade mucoepidermoid carcinoma, there are cystic spaces that are partly lined by mucous cells (as indicated by the arrows). This image was from the Department of Pathology at the Stomatological Hospital of Jilin University

Figure 6　HE staining findings of low-grade mucoepidermoid carcinoma

**图6**　低级别黏液表皮样癌的HE染色

性[96-97]。CK7阳性[98]，而S100和SOX10阴性。肿瘤细胞周围的基底/肌上皮细胞p63阳性[99]。mSDC的MUC2-MUC6阳性与黏液性乳腺癌中所见表现存在重叠，由此提示了SDC与乳腺癌（carcinomas of the breast）之间存在相似性（a novel analogy）。

根据Simpson等[100]对mSDC的定义，当黏液成分占肿瘤面积>40%时，可明确诊断为mSDC。mSDC作为SDC的一种罕见亚型，表现为显著的细胞外黏液湖（pools of extracellular mucin）伴有经典型SDC区域（图7）[101-102]。有报道称mSDC黏液湖内肿瘤细胞呈单个、簇状或腺管样排列；胞质嗜酸性或空泡状，部分细胞可见核偏位的印戒样形态；细胞核多形性明显，可见奇异核，核分裂象易见[101]。

mSDC主要需要与MA鉴别，MA中黏液成分范围更广泛，核异型性多为轻至中度，核分裂象少见，缺乏经典型SDC区域。

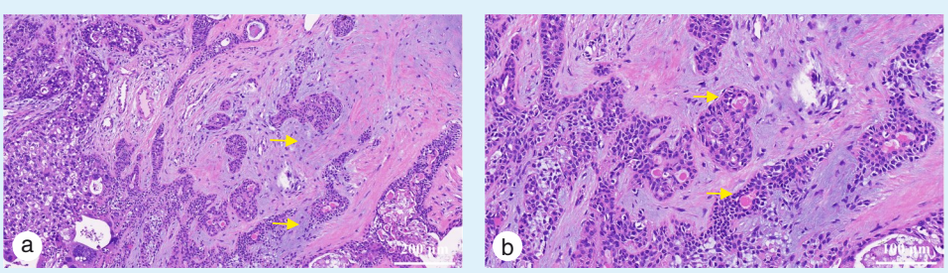

a: HE staining showing that in mucin-rich salivary duct carcinoma, there are significant pools of extracellular mucin (as indicated by the arrows); b: HE staining showing that mucin-rich salivary duct carcinoma are commonly accompanied by areas of conventional salivary duct carcinoma (as indicated by the arrows). These images were from the Department of Pathology at the Stomatological Hospital of Jilin University

Figure 7　HE staining findings of mucin-rich salivary duct carcinoma

**图7**　富黏液型唾液腺导管癌的HE染色

### 2.5　分泌性癌

SC是一种细胞形态单一的唾液腺恶性肿瘤，该肿瘤通常以ETV6或RET基因特异性重排为分子特征[103]，绝大多数病例存在ETV6::NTRK3基因融合即ETS变体转录因子6::神经营养受体酪氨酸激酶3基因融合（ETS variant transcription factor 6::Neurotrophic receptor tyrosine kinase 3 gene fusion，ETV6::NTRK3），或ETV6::RET基因融合即ETS变体转录因子6::转染过程中重排原癌基因基因融合（ETS variant transcription factor 6::Rearranged during transfection proto-oncogene gene fusion，ETV6::RET）[104]。SC最常见于腮腺及下颌下腺[105-108]，通常发生于成人，男女比例均等[105-110]。

SC边界清楚但通常无包膜。肿瘤细胞常排列成实性、管状及乳头囊状。腔内含有嗜酸性分泌物，肿瘤细胞胞质丰富，嗜酸性或多泡状，核分裂象罕见。

SC免疫组织化学染色显示为肿瘤细胞S100和mammaglobin弥漫强阳性，二者对SC诊断的灵敏度高达95%以上。SC通常还表达CK7、SOX10、Vimentin、mammaglobin、MUC1和MUC4[111]，不表达p63、p40、NR4A3和DOG1[105, 107, 112]。

SC通常不属于富含黏液的肿瘤，但是存在罕见病例报道其出现MA样高级别转化[113]：部分区域失去典型小管结构，由黏液湖及黏液细胞取代[113]；mammaglobin局灶阳性且S100阴性，但是ETV6::RET融合仍存在[113]。鉴别诊断需依赖寻找残留的SC成分。

### 2.6　肠型腺癌

唾液腺非特异性腺癌(salivary gland carcinoma,NOS)是指一组异质性的癌,它们形成上皮性、导管性和/或腺体性结构[114-115]。非特异性腺癌目前仅占所有唾液腺癌的5%～10%[116-118],好发于腮腺[117-118]和小唾液腺,患者年龄分布范围广[117, 119]。但是在儿童中极为罕见。肠型腺癌是唾液腺非特异性腺癌的罕见亚型,具有侵袭性生物学行为。组织形态与原发性结肠腺癌相似,由高柱状细胞形成腺样/管状结构。在部分病例中还发现了大量的黏液成分[120],肠型腺癌常表达CK20和CDX2[120-122]。

肠型腺癌的诊断需排除所有其他已明确定义的唾液腺癌类型,包括:MA、LG-MEC、mSDC、其他唾液腺恶性肿瘤的高级别转化,MA具有显著细胞外黏液,免疫组化染色显示CK7阳性、CK20阴性的黏液细胞;LG-MEC其组织学特征为存在表皮样细胞和中间细胞,并且表达p63/p40;mSDC具有大汗腺样细胞学特征,免疫组织化学染色显示AR阳性。

## 3　总　结

本文系统梳理了2022年第5版WHO《头颈部肿瘤病理学和遗传学分类》及相关最新文献中关于富含细胞外黏液的唾液腺肿瘤的内容。第5版WHO分类进一步明晰了部分肿瘤的界定,例如强调了MA作为一种独立的组织学类型,并与AKT1 E17K突变密切相关;正式确立了微分泌性腺癌这一新类型,其特征性的*MEF2C::SS18*基因融合成为诊断关键。这些更新凸显了免疫组织化学(如NKX3.1、S100、SOX10、AR、p40/p63、CDX2/CK20组合等)和分子检测(如AKT1、MAML2、MEF2C::SS18、ETV6重排等)在鉴别诊断中的核心地位。本文系统梳理了富含细胞外黏液唾液腺肿瘤的核心病理特征与鉴别要点,以期为临床病理诊断及治疗方案提供实用参考(表1)。例如,存在AKT1 E17K突变的MA可能对AKT抑制剂敏感;携带*ETV6::NTRK3*融合的SC可使用TRK抑制剂;人类表皮生长因子受体2(human epidermal growth factor receptor 2,HER2)阳性的mSDC可能从抗HER2靶向治疗中获益。目前,部分罕见黏液亚型(如分泌性肌上皮癌)在明确定义与分类归属方面仍存争议,需更多病例以形成共识;某些肿瘤(如IPMN)的生物学行为及其向MA演化的关系尚不完全明确。临床上准确识别被大量细胞外黏液掩盖的经典组织结构仍是重要挑战,同时必须谨慎排除转移性腺癌。因此,尽管2022年第5版WHO分类为这类肿瘤提供了更清晰的诊断路径,其鉴别诊断体系仍有待完善,未来仍需依托更大样本的研究和新型生物标志物的探索,以进一步提升诊断准确性及对临床治疗指导意义。

**表1**　富含细胞外黏液唾液腺肿瘤鉴别诊断:部位、关键形态学特征、免疫组织化学特征及分子特征

Table 1　Differential diagnosis of mucin-rich salivary gland: localization, key morphological, immunohistochemical and molecular findings

| Entity | Localization | Key morphological features | Immunohistochemistry | Molecular findings |
|---|---|---|---|---|
| MCA | The parotid gland and the minor salivary glands of the lip and buccal mucosa | A unicystic or multicystic non-invasive bland neoplasm with an oncocytic or mixed epithelial lining; a variable papillary component; a demonstrable basal cell layer; no lymphoid stroma | The lining cells show a simple luminal phenotype (CK8/18$^+$), supported by a p63$^+$ basal cell layer; S100 and SOX10 are usually absent or only focally expressed | None |
| Mucinous/secretory variant of myoepithelioma | The parotid gland, palate, and submandibular gland | Composed almost exclusively of myoepithelial cells with no invasive growth; the tumor is typically encapsulated (except in minor salivary glands); the stroma may be myxoid; abundant intracellular mucin is a rare finding | The myoepithelial cells were positive for keratins, S100, SOX10, and myoepithelial markers such as p63, calponin, and SMA | PLAG1 rearrangement |

续表1

| Entity | Localization | Key morphological features | Immunohistochemistry | Molecular findings |
|---|---|---|---|---|
| SP-IPT | The tongue and retromolar area | The lesion is comprised of multiple tubular and cystic structures of variable size and shape; these tubulocystic structures are lined by a double or multilayered epithelium, often exhibiting a micropapillary growth pattern; the outer layer consists of myoepithelial cells, and the inner layer is composed of ductal cells, indicative of intercalated duct differentiation | The outer myoepithelial cells were positive for CK7, p63, SMA, vimentin, S100, and SOX10, whereas the inner ductal cells expressed CK7, S100, and SOX10 | BRAF p.V600E mutations were identified in a subset of cases |
| PA | The parotid gland, palate, and submandibular gland | It is characterized by an admixture of bilayered ductal structures, myoepithelial cells, and a chondromyxoid or fibrous stroma, with no evidence of invasive growth or malignant cytomorphological features | The tumor typically shows strong, diffuse positivity for pancytokeratin and CK7 (accentuated in ductal areas), along with various myoepithelial/basal markers (calponin, SMA, S100, SOX10, p40, CK5/6). GFAP is often strong in myxoid/myoepithelial regions | PLAG1 or HMGA2 alterations (in select cases) |
| MA | The intraoral minor salivary glands | A salivary gland malignancy with abundant intracellular or extracellular mucin; no features of other mucin-producing salivary gland neoplasms | The tumor is positive for CK7 and negative for CK20 | AKT1 p.E17K mutation (in select cases) |
| MSA | The palate and buccal mucosa | A salivary gland malignancy with a microcystic-predominant growth pattern; bluish secretions; fibromyxoid stroma; monotonous tumor cells | The tumor is positive for S100 and p63 but negative for p40 or mammaglobin | MEF2C::SS18 fusion |
| LG-MEC | The parotid gland, submandibular and sublingual glands, palate and buccal mucosa | Salivary gland carcinoma with mucous, intermediate, and squamoid cells | In most cases, LG-MEC is positive for p63/p40 and negative for S100/SOX10 | MAML2 rearrangement (in select cases) |
| mSDC | The major salivary glands | A complex architecture, including solid, cribriform, and papillary-cystic patterns, with frequent comedonecrosis; the tumor cells typically exhibit apocrine features | The tumor is positive for AR | The potential relevant molecular alterations may include androgen receptor (AR) expression/amplification, ERBB2 amplification, PI3K pathway abnormalities (including PIK3CA mutations and PTEN loss), and a BRAF p.V600E mutation |
| SC | The parotid gland, submandibular gland, oral cavity, lip, soft palate and buccal mucosa | A malignant salivary gland neoplasm of a single cell type with vacuolated, colloid-like secretory material; no zymogen cytoplasmic granules | The tumor is positive for S100, SOX10, and mammaglobin; negative for p40/p63 | ETV6::NTRK3 fusion is present in most cases |
| Intestinal-type adenocarcinoma | The parotid gland, hard palate, buccal mucosa and lips | A salivary gland carcinoma characterized by tall columnar cells forming a glandular/tubular architecture and lacking the morphological, immunohistochemical, and molecular features of other salivary gland or metastatic carcinomas | The tumor is positive for CK20, CDX2 and CK7 | None |

MCA: mucinous cystadenoma; SP-IPT: sialadenoma papilliferum-like intraductal papillary tumor; PA: pleomorphic adenoma; MA: mucinous adenocarcinoma; MSA: microsecretory adenocarcinoma; LG-MEC: low-grade mucoepidermoid carcinoma; mSDC: mucin-rich salivary duct carcinoma; SC: secretory carcinoma

【Author contributions】 Guan WH wrote the article. Liu CW, Guo H, Li JW, Wang DD, Qiao CY and Nie MD collected the references and revised the article. Qu M and Shi C conceptualized and reviewed the article. All authors read and approved the final manuscript as submitted.

## 参考文献

[1] Watabe Y, Shinagawa S, Shigematsu S. Surgery for cystadenoma of the retromolar pad area with reconstruction using a buccal fat pad flap: a case report[J]. Cureus, 2022, 14(7): e27314. doi: 10.7759/cureus.27314.

[2] Caranti A, Spasiano R, Piantanida R, et al. Oncocytic papillary cystadenoma of the larynx: a case report[J]. J Med Case Rep, 2024, 18(1): 172. doi: 10.1186/s13256-024-04425-2.

[3] Kanioura E, Riga D, Potamianos S, et al. Oncocytic papillary cystadenoma: a case of a misdiagnosed laryngeal mass[J]. Cureus, 2024, 16(1): e52147. doi: 10.7759/cureus.52147.

[4] Kavuri SK, Ullah A, Iyoha E, et al. Oncocytic papillary cystadenoma, an unusual variant presenting as a laryngeal ventricular cyst[J]. Curr Health Sci J, 2022, 48(3): 353-355. doi: 10.12865/CHSJ.48.03.15.

[5] Malik V, Dixit M, Sharma S, et al. Papillary cystadenoma of the major salivary gland: a case report and review of literature[J]. Pathol Res Pract, 2023, 251: 154884. doi: 10.1016/j.prp.2023.154884.

[6] de Paiva JPG, Roldán DG, Bezerra HKF, et al. Intraoral salivary gland cystadenomas: a case series study and literature review[J]. Head Neck Pathol, 2024, 18(1): 45. doi: 10.1007/s12105-024-01661-2.

[7] Rai S, Rana AS, Gupta V, et al. Mucinous cystadenoma: a rare entity[J]. Dent Res J, 2013, 10(5): 685-688.

[8] Aggarwal D, Yadav S, Jain A, et al. Role of p63 in determining the histogenesis of low-grade neoplasms versus cystic lesion[J]. J Microsc Ultrastruct, 2022, 12(2): 104-107. doi: 10.4103/jmau.jmau_85_21.

[9] Yasui Y, Uchiyama K, Yamada M, et al. Cystadenocarcinoma of the sublingual gland: a rare subvariant of salivary gland carcinoma [J]. Cureus, 2024, 16(9): e69815. doi: 10.7759/cureus.69815.

[10] Owosho AA, Shasteen AM, Aguirre SE, et al. Clinicopathologic study of sialadenoma papilliferum of the minor salivary glands: a series of 8 new cases with BRAF V600E mutation-specific immunohistochemical analysis[J]. Int J Surg Pathol, 2023, 31(7): 1265-1272. doi: 10.1177/10668969221147170.

[11] Oh KY, Kim JH, Hong SD, et al. Sialadenoma papilliferum-like intraductal papillary tumour: an emerging entity with intercalated duct differentiation showing MAPK pathway activation in both ductal and myoepithelial cells[J]. Pathology, 2024, 56(1): 52-58. doi: 10.1016/j.pathol.2023.09.004.

[12] Nakaguro M, Urano M, Ogawa I, et al. Histopathological evaluation of minor salivary gland papillary-cystic tumours: focus on genetic alterations in sialadenoma papilliferum and intraductal papillary mucinous neoplasm[J]. Histopathology, 2020, 76(3): 411-422. doi: 10.1111/his.13990.

[13] Lee S, Hong SD, Lee JI, et al. Sialadenoma papilliferum-like intraductal papillary tumor of the mandible with BRAF V600E mutation: a rare case report[J]. J Dent Sci, 2025, 20(3): 1996-1998. doi: 10.1016/j.jds.2025.03.035.

[14] Zeng M, Mou L, Guo X, et al. BRAF p.V600E-negative low-grade adenocarcinoma of the mandible with features of sialadenopapillary ductal tumor and prominent mucinous differentiation: report of a unique case[J]. Oral Surg Oral Med Oral Pathol Oral Radiol, 2025, 140(6): 719-727. doi: 10.1016/j.oooo.2025.06.013.

[15] Alsugair Z, Neuhart A, Benzerdjeb N, et al. Sialadenoma papilliferum-like intraductal papillary tumor with unveiling BRAF V600E and PIK3CA H1047R mutations: case report with molecular analysis and literature review[J]. Int J Surg Case Rep, 2024, 118: 109611. doi: 10.1016/j.ijscr.2024.109611.

[16] Borges Marques M, Barbeiro CO, Martins KH, et al. Sialadenopapillary ductal tumor: unifying sialadenoma papilliferum-like intraductal papillary tumor and tubulopapillary hidroadenoma-like tumor of the mandible-report of an additional case[J]. Oral Oncol, 2025, 169: 107655. doi: 10.1016/j.oraloncology.2025.107655.

[17] Bishop JA. Mucin-rich salivary gland tumors[J]. Semin Diagn Pathol, 2024, 41(4): 165-172. doi: 10.1053/j.semdp.2024.06.001.

[18] Mughal A, Danish H, Hassan S, et al. Myoepithelioma of the parotid gland: a case report and literature review[J]. Indian J Otolaryngol Head Neck Surg, 2022, 74(Suppl 3): 6087-6090. doi: 10.1007/s12070-021-02763-x.

[19] Sakhariya SV, Chincholkar A, Waknis PP, et al. Unveiling rarity: myoepithelioma in the minor salivary gland of buccal mucosa - a case report[J]. Int J Surg Case Rep, 2024, 120: 109849. doi: 10.1016/j.ijscr.2024.109849.

[20] França MS, Valente E Silva P, Amaral MHD, et al. Salivary epithelial-myoepithelial carcinoma: clinical, histopathological and molecular study from a Latin American case series with a novel MSH3 driver[J]. Head Neck Pathol, 2025, 19(1): 40. doi: 10.1007/s12105-025-01776-0.

[21] Saeidi A, Alolayan A, Zaki H, et al. A rare case presentation of intraoral palatal myoepithelioma[J]. Reports, 2025, 8(4): 196. doi: 10.3390/reports8040196.

[22] Viswanathan V, Londhe M, Gurwale S, et al. Clear cell myoepithelioma of palate: a rare case report with brief review of literature[J]. J Oral Maxillofac Pathol, 2024, 28(3): 493-496. doi: 10.4103/jomfp.jomfp_372_23.

[23] Bhardwaj S, Krishnan M, Kumar M P S, et al. Myoepithelioma of the palatal minor salivary gland: a case report[J]. Cureus, 2024, 16(3): e56305. doi: 10.7759/cureus.56305.

[24] Young A, Okuyemi OT. Benign salivary gland tumors[M]. Treasure Island (FL): StatPearls Publishing, 2025.

[25] Shenoy S V, Dhawan S, Apoorva KV, et al. Myoepithelioma- an uncommon parotid tumour in an adolescent[J]. Indian J Otolaryngol Head Neck Surg, 2024, 76(1): 1168-1173. doi: 10.1007/s12070-023-04199-x.

[26] Telugu RB, Gaikwad P, Baitule A, et al. Myoepithelial tumors of salivary gland: a clinicopathologic and immunohistochemical study of 15 patients with MIB-1 correlation[J]. Head Neck Pathol, 2021, 15(2): 479-490. doi: 10.1007/s12105-020-01225-0.

[27] Soberanis-Piña PD, Fernández-Ferreira R, Buerba-Vieregge HH, et al. Myoepithelial carcinoma arising in a plasmacytoid myoepithelioma of the parotid gland synchronized with melanoma: a case report and review of the literature[J]. Case Rep Oncol, 2021, 14(1): 173-183. doi: 10.1159/000510937.

[28] Kalra Y, Koppolu S, Babu M, et al. A rare presentation of myoepithelioma of the parotid gland manifesting as an infra-auricular swelling[J]. Cureus, 2024, 16(10): e70746. doi: 10.7759/cureus.70746.

[29] Ochiai S, Yamada M, Suga K, et al. Myoepithelioma arising in the buccal mucosa: a case report and review of the literature[J]. Cureus, 2024, 16(11): e73263. doi: 10.7759/cureus.73263.

[30] Mahmood MN. Cutaneous syncytial myoepithelioma: a unique variant worth recognizing[J]. Dermatopathology, 2023, 10(3): 219-225. doi: 10.3390/dermatopathology10030030.

[31] Mireles MG, Julián A, Salgado-Chavarría F, et al. Benign myoepithelioma of the soft palate: an unusual clinical entity[J]. BMJ Case Rep, 2021, 14(6): e240384. doi: 10.1136/bcr-2020-240384.

[32] Urias Barreras CM, Soto Sañudo AK, Vega Imperial J, et al. Intraoral exophytic lesion in an adolescent: a case report of myoepithelioma with unique clinical presentation[J]. J Stomatol Oral Maxillofac Surg, 2023, 124(4): 101419. doi: 10.1016/j.jormas.2023.101419.

[33] Saravanam PK, Manimaran V, Rajendran R. Clear cell, giant myoepithelioma of tongue base: a diagnostic and surgical challenge[J]. BMJ Case Rep, 2019, 12(1): e226764. doi: 10.1136/bcr-2018-226764.

[34] Cormier C, Agarwal S. Myoepithelial carcinoma ex-pleomorphic adenoma: a rare pathology misdiagnosed as pleomorphic adenoma; with a novel TERT promoter mutation and high PD-L1 expression [J]. Head Neck Pathol, 2022, 16(1): 322-330. doi: 10.1007/s12105-021-01346-0.

[35] Agarwal S. Pitfalls in diagnosis of myoepithelial carcinoma of salivary glands: a study of 3 cases with cytologic-histologic correlation and molecular analysis[J]. Head Neck Pathol, 2024, 18(1): 96. doi: 10.1007/s12105-024-01698-3.

[36] Thakur A, Lipi L, Sarin H, et al. Fine-needle aspiration cytology of parotid mucinous myoepithelioma with follow-up histopathology: a case report[J]. Diagn Cytopathol, 2023, 51(6): E181-E184. doi: 10.1002/dc.25121.

[37] Oyama T, Shioya A, Ikeda H, et al. Unique cytopathological findings of a mucinous myoepithelioma showing a mucous globule and a "sieve-like" structure[J]. Cureus, 2024, 16(8): e67697. doi: 10.7759/cureus.67697.

[38] Żurek M, Fus Ł, Niemczyk K, et al. Salivary gland pathologies: evolution in classification and association with unique genetic alterations[J]. Eur Arch Otorhinolaryngol, 2023, 280(11): 4739-4750. doi: 10.1007/s00405-023-08110-w.

[39] Skálová A, Gnepp DR, Lewis JS, et al. Newly described entities in salivary gland pathology[J]. Am J Surg Pathol, 2017, 41(8): e33-e47. doi: 10.1097/PAS.0000000000000883.

[40] Val-Bernal JF, Lazuen S, Calapaquí-Terán AK, et al. Pure extracellular mucin-producing (colloid) myoepithelioma of the parotid gland[J]. Pathol Res Pract, 2022, 239: 154162. doi: 10.1016/j.prp.2022.154162.

[41] Patel S, Wald AI, Bastaki JM, et al. NKX3.1 expression and molecular characterization of secretory myoepithelial carcinoma (SMCA): advancing the case for a salivary mucous acinar phenotype[J]. Head Neck Pathol, 2023, 17(2): 467-478. doi: 10.1007/s12105-023-01524-2.

[42] Suter VGA, Stanowska O. Pleomorphic adenoma of the upper lip [J]. Swiss Dent J, 2025, 135(2): 1-7. doi: 10.61872/sdj-2025-02-01.

[43] Xu X, Xie J, Ling R, et al. Single-cell transcriptomic analysis uncovers the origin and intratumoral heterogeneity of parotid pleomorphic adenoma[J]. Int J Oral Sci, 2023, 15(1): 38. doi: 10.1038/s41368-023-00243-2.

[44] Agaimy A, Ihrler S, Baněčková M, et al. HMGA2-WIF1 rearrangements characterize a distinctive subset of salivary pleomorphic adenomas with prominent trabecular (canalicular adenoma-like) morphology[J]. Am J Surg Pathol, 2022, 46(2): 190-199. doi: 10.1097/PAS.0000000000001783.

[45] Çağlayan F, Sümbüllü MA, Şahin A, et al. A distinct radiologic perspective on parotid pleomorphic adenoma: sialo-CBCT case report[J]. BMC Oral Health, 2025, 26(1): 124. doi: 10.1186/s12903-025-07506-w.

[46] Jose DA, Mohiyuddin SMA, Mohammadi K, et al. Extra-parotid pleomorphic adenoma and low-grade salivary malignancy in the head and neck region[J]. Cureus, 2023, 15(5): e39463. doi: 10.7759/cureus.39463.

[47] Birigi M, Mweya CN. Surgical tumour excision of pleomorphic adenoma of submandibular salivary gland: a case report and literature review[J]. Int J Surg Case Rep, 2023, 106: 108236. doi: 10.1016/j.ijscr.2023.108236.

[48] Singh K, Kumar Mishra A, Kour A, et al. Novel approach for management of extremely rare pleomorphic adenoma of soft palate (minor salivary glands)[J]. Indian J Otolaryngol Head Neck Surg, 2022, 74(Suppl 2): 1989-1991. doi: 10.1007/s12070-020-01946-2.

[49] Su HZ, Yang DH, Hong LC, et al. Machine learning model for preoperative classification of stromal subtypes in salivary gland pleomorphic adenoma based on ultrasound histogram analysis[J]. BMC Oral Health, 2025, 25(1): 898. doi: 10.1186/s12903-025-06298-3.

[50] Modrić A, Gabelica M, Mihovilović A, et al. Eleven-year incidence of salivary gland tumors-a retrospective, single-centered study in Croatia[J]. Clin Pract, 2025, 15(6): 104. doi: 10.3390/clinpract15060104.

[51] Cunha JLS, Hernandez-Guerrero JC, de Almeida OP, et al. Salivary gland tumors: a retrospective study of 164 cases from a single private practice service in Mexico and literature review[J]. Head Neck Pathol, 2021, 15(2): 523-531. doi: 10.1007/s12105-020-01231-2.

[52] 王张嵩, 谢舒乐, 张汉卿, 等. 2 456例唾液腺肿瘤临床病理分析[J]. 口腔疾病防治, 2020, 28(5): 298-302. doi: 10.12016/j.issn.2096-1456.2020.05.005.
Wang ZS, Xie SL, Zhang HQ, et al. Clinical and pathological analysis of

2 456 cases of salivary gland tumor[J]. J Prev Treat Stomatol Dis, 2020, 28(5): 298-302. doi: 10.12016/j. issn. 2096-1456.2020.05.005.

[53] Lianou AD, Zarachi A, Derka S, et al. Pleomorphic adenoma of minor salivary glands: a rare case report[J]. Maedica, 2024, 19(2): 434-438. doi: 10.26574/maedica.2024.19.2.434.

[54] Valstar MH, Schaapveld M, van den Broek EC, et al. Risk of breast cancer in women after a salivary gland carcinoma or pleomorphic adenoma in the Netherlands[J]. Cancer Med, 2021, 10(1): 424-434. doi: 10.1002/cam4.3598.

[55] Usman S, Ahmed S, Iqbal S, et al. Pleomorphic adenoma of minor salivary gland[J]. J Coll Physicians Surg Pak, 2022, 32(4): S70-S72. doi: 10.29271/jcpsp.2022.Supp1.S70.

[56] Xu W, Zhang X, Wu Y, et al. Recurrent pleomorphic adenoma of the parotid gland: a population-based study with emphasis on re-recurrence and malignant transformation[J]. Head Neck, 2023, 45 (3): 697-705. doi: 10.1002/hed.27286.

[57] Sheereen S, Manva MZ, Sheereen S, et al. "Pleomorphic adenoma in salivary glands: insights from a 100-patient analysis"[J]. J Oral Maxillofac Pathol, 2024, 28(1): 42-48. doi: 10.4103/jomfp.jomfp_452_23.

[58] Samia M, Amin K, Rihab O, et al. Case series: pleomorphic adenoma in minor salivary gland[J]. F1000Res, 2024, 13: 243. doi: 10.12688/f1000research.146682.2.

[59] de Lima-Souza RA, Bělohlávková K, Michal M, et al. Atypical and worrisome histological features in pleomorphic adenoma: challenging and potentially significant diagnostic pitfall[J]. Virchows Arch, 2025, 487(3): 543-555. doi: 10.1007/s00428-024-04015-z.

[60] Brodetskyi IS, Malanchuk VA, Sorokin BV, et al. Tumors and tumor-like lesions of the salivary glands: morphological characteristics of the surgical material[J]. Wiad Lek, 2021, 74(4): 929-933. doi: 10.36740/wlek202104122.

[61] Mantsopoulos K, Thimsen V, Gostian AO, et al. Histopathology of parotid pleomorphic adenomas: a "pleomorphic approach" to a demanding lesion[J]. Laryngoscope, 2022, 132(1): 73-77. doi: 10.1002/lary.29726.

[62] Mannweiler S, Beham A, Langner C. MUC1 and MUC2 expression in salivary gland tumors and in non-neoplastic salivary gland tissue [J]. APMIS, 2003, 111(10): 978-984. doi: 10.1034/j. 1600-0463.2003.1111010.x.

[63] Yamada K, Tanaka T, Mori M, et al. Immunohistochemical expression of MAM-3 and MAM-6 antigens in salivary gland tumours[J]. Virchows Arch A Pathol Anat Histopathol, 1989, 415(6): 509-521. doi: 10.1007/BF00718644.

[64] Hamada T, Matsukita S, Goto M, et al. Mucin expression in pleomorphic adenoma of salivary gland: a potential role for MUC1 as a marker to predict recurrence[J]. J Clin Pathol, 2004, 57(8): 813-821. doi: 10.1136/jcp.2003.014043.

[65] Kinoshita I, Jin D, Higashino M, et al. Increase in chymase-positive mast cells in recurrent pleomorphic adenoma and carcinoma ex pleomorphic adenoma of the parotid gland[J]. Int J Mol Sci, 2021, 22(23): 12613. doi: 10.3390/ijms222312613.

[66] Rajbhar R, Margam S, Fernandes G. Oral cavity salivary gland pleomorphic adenoma: a histomorphological case series[J]. Ann Diagn Pathol, 2024, 71: 152306. doi: 10.1016/j. anndiagpath.2024.152306.

[67] Yakirevich E, Sabo E, Klorin G, et al. Primary mucin-producing tumours of the salivary glands: a clinicopathological and morphometric study[J]. Histopathology, 2010, 57(3): 395-409. doi: 10.1111/j.1365-2559.2010.03639.x.

[68] Rooper LM, Argyris PP, Thompson LDR, et al. Salivary mucinous adenocarcinoma is a histologically diverse single entity with recurrent AKT1 E17K mutations: clinicopathologic and molecular characterization with proposal for a unified classification[J]. Am J Surg Pathol, 2021, 45(10): 1337-1347. doi: 10.1097/PAS.0000000000001688.

[69] Abdelmoneim NA, Elfouly AM, Abou Madawi NA. Microsecretory adenocarcinoma: simplifying the diagnosis of a recently recognized salivary gland and cutaneous adnexal neoplasm[J]. Diagn Pathol, 2025, 20(1): 34. doi: 10.1186/s13000-025-01628-z.

[70] Wang Y, Li X, Yao C, et al. Intraductal papilloma of minor salivary gland: a case report and literature review[J]. Front Oral Health, 2025, 6: 1508614. doi: 10.3389/froh.2025.1508614.

[71] Feitosa S, Oliveira R, Bezerra T, et al. Tumor budding and poor prognosis in oral cancer: a systematic review and meta-analysis[J]. Asian Pac J Cancer Prev, 2023, 24(8): 2565-2573. doi: 10.31557/APJCP.2023.24.8.2565.

[72] Weinreb I, Hahn E, Dickson BC, et al. Microcribriform adenocarcinoma of salivary glands: a unique tumor entity characterized by an SS18: : ZBTB7A fusion[J]. Am J Surg Pathol, 2023, 47(2): 194-201. doi: 10.1097/PAS.0000000000001980.

[73] Bishop JA, Koduru P, Veremis BM, et al. SS18 break-apart fluorescence in situ hybridization is a practical and effective method for diagnosing microsecretory adenocarcinoma of salivary glands [J]. Head Neck Pathol, 2021, 15(3): 723-726. doi: 10.1007/s12105-020-01280-7.

[74] Bishop JA, Williams EA, McLean AC, et al. Microsecretory adenocarcinoma of the skin harboring recurrent SS18 fusions: a cutaneous analog to a newly described salivary gland tumor[J]. J Cutan Pathol, 2023, 50(2): 134-139. doi: 10.1111/cup.14271.

[75] Dibbern ME, Gru AA, Stelow EB. Microsecretory adenocarcinoma of the external ear canal[J]. J Cutan Pathol, 2023, 50(2): 106-109. doi: 10.1111/cup.14277.

[76] Bishop JA, Sajed DP, Weinreb I, et al. Microsecretory adenocarcinoma of salivary glands: an expanded series of 24 cases[J]. Head Neck Pathol, 2021, 15(4): 1192-1201. doi: 10.1007/s12105-021-01331-7.

[77] Razack R, Bishop JA, Alwan J, et al. Cytopathology of a newly described salivary gland neoplasm: a case report of microsecretory adenocarcinoma presenting in the parotid gland[J]. Acta Cytol, 2024, 68(6): 516-524. doi: 10.1159/000541997.

[78] Jurmeister P, Haas C, Eisterer W, et al. New entity of microsecretory adenocarcinoma of salivary glands: first case with recurrence and metastases - proof of malignancy[J]. Virchows Arch, 2022, 481 (6): 963-965. doi: 10.1007/s00428-022-03374-9.

[79] Lu Y, Wen Y, Feng S, et al. Microsecretory adenocarcinoma of the

hard palate: a case report and literature review[J]. Diagn Pathol, 2024, 19(1): 95. doi: 10.1186/s13000-024-01514-0.

[80] Bogiatzi S, Estenaga A, Louveau B, et al. Microsecretory adenocarcinoma of the skin, a novel type of sweat gland carcinoma: report of three additional cases[J]. J Cutan Pathol, 2023, 50(10): 897-902. doi: 10.1111/cup.14408.

[81] Dahan LS, Giorgi R, Vergez S, et al. Mucoepidermoid carcinoma of salivary glands: a French network of rare head and neck tumors (REFCOR) prospective study of 292 cases[J]. Eur J Surg Oncol, 2021, 47(6): 1376-1383. doi: 10.1016/j.ejso.2020.11.123.

[82] Mashiana S, Duarte EM. Metastatic mucoepidermoid carcinoma to the pleura: a case report[J]. J Med Case Rep, 2022, 16(1): 69. doi: 10.1186/s13256-022-03285-y.

[83] Chen C, Patel A, Demirkhanyan L, et al. The role of mucins in cancer and cancer progression: a comprehensive review[J]. Curr Issues Mol Biol, 2025, 47(6): 406. doi: 10.3390/cimb47060406.

[84] Dwertmann Rico S, Schliesser SJA, Gorbokon N, et al. Pattern of MUC6 expression across 119 different tumor types: a tissue microarray study on 15 412 tumors[J]. Pathol Int, 2023, 73(7): 281-296. doi: 10.1111/pin.13322.

[85] Bishop JA, Thompson LDR, Siegele B, et al. Mucoepidermoid carcinoma may be devoid of squamoid cells by immunohistochemistry: expanding the histologic and immunohistochemical spectrum of MAML2- rearranged salivary gland tumours[J]. Histopathology, 2023, 82(2): 305-313. doi: 10.1111/his.14817.

[86] Sams RN, Gnepp DR. P63 expression can be used in differential diagnosis of salivary gland acinic cell and mucoepidermoid carcinomas[J]. Head Neck Pathol, 2013, 7(1): 64-68. doi: 10.1007/s12105-012-0403-2.

[87] Ahn B, Choi SH, Kim D, et al. Salivary gland neoplasms with a unique trabecular histology and MAML2 translocation: a trabecular variant of a mucoepidermoid carcinoma[J]. Am J Surg Pathol, 2023, 47(10): 1085-1095. doi: 10.1097/PAS.0000000000002110.

[88] Okumura Y, Nakano S, Murase T, et al. Prognostic impact of CRTC1/3-MAML2 fusions in salivary gland mucoepidermoid carcinoma: a multiinstitutional retrospective study[J]. Cancer Sci, 2020, 111(11): 4195-4204. doi: 10.1111/cas.14632.

[89] Kusafuka K, Sato Y, Nakatani E, et al. The implicated clinical factors for outcomes in 304 patients with salivary duct carcinoma: multi-institutional retrospective analysis in Japan[J]. Head Neck, 2022, 44(6): 1430-1441. doi: 10.1002/hed.27034.

[90] Agaimy A, Mueller SK, Bishop JA, et al. Primary and secondary/metastatic salivary duct carcinoma presenting within the sinonasal tract[J]. Head Neck Pathol, 2021, 15(3): 769-779. doi: 10.1007/s12105-020-01271-8.

[91] Steuer CE, Hanna GJ, Viswanathan K, et al. The evolving landscape of salivary gland tumors[J]. CA Cancer J Clin, 2023, 73(6): 597-619. doi: 10.3322/caac.21807.

[92] Kim Y, Park JU. Cystic salivary duct carcinoma penetrated by facial nerve[J]. Arch Plast Surg, 2022, 49(4): 523-526. doi: 10.1055/s-0042-1751108.

[93] Verma S, Khan E, Samadi FM, et al. Salivary duct carcinoma: a case report with cytological and immunohistochemical study and review of literature[J]. Cureus, 2025, 17(3):e80815. doi: 10.7759/cureus.80815.

[94] Chiosea SI, Williams L, Griffith CC, et al. Molecular characterization of apocrine salivary duct carcinoma[J]. Am J Surg Pathol, 2015, 39(6): 744-752. doi: 10.1097/PAS.0000000000000410.

[95] Perri F, Fusco R, Sabbatino F, et al. Translational insights in the landscape of salivary gland cancers: ready for a new era?[J]. Cancers, 2024, 16(5): 970. doi: 10.3390/cancers16050970.

[96] Mayer M, Wolber P, Prinz J, et al. The extent of androgen receptor and HER2 expression allows for targeted therapy in most cases of salivary duct carcinoma: analysis of clinical and histopathological data in a tertiary care center[J]. Eur Arch Otorhinolaryngol, 2024, 281(7): 3779-3789. doi: 10.1007/s00405-024-08627-8.

[97] Williams CYK, Townson AT, Terry N, et al. Role of HER2 in prognosis of salivary duct carcinoma: a systematic review and meta-analysis[J]. Laryngoscope, 2023, 133(3): 476-484. doi: 10.1002/lary.30214.

[98] Serinelli S, Mirchia K, Gitto L, et al. PAX-8 expression in salivary duct carcinoma[J]. Appl Immunohistochem Mol Morphol, 2021, 29(9): 680-684. doi: 10.1097/PAI.0000000000000951.

[99] Dababneh MN, Griffith CC, Magliocca KR, et al. Salivary duct carcinoma with squamous differentiation: histomorphological and immunophenotypical analysis of six cases[J]. Histopathology, 2024, 85(4): 590-597. doi: 10.1111/his.15217.

[100] Simpson RH, Prasad AR, Lewis JE, et al. Mucin-rich variant of salivary duct carcinoma: a clinicopathologic and immunohistochemical study of four cases[J]. Am J Surg Pathol, 2003, 27(8): 1070-1079. doi: 10.1097/00000478-200308000-00004.

[101] Jain R, Sansoni ER, Angel J, et al. Salivary duct carcinoma with rhabdoid features of the parotid gland with no E-cadherin expression: a report with anti-HER2 therapy and review of the literature [J]. Dent J, 2023, 11(10): 229. doi: 10.3390/dj11100229.

[102] Kusafuka K, Maeda M, Honda M, et al. Mucin-rich salivary duct carcinoma with signet-ring cell feature ex pleomorphic adenoma of the submandibular gland: a case report of an unusual histology with immunohistochemical analysis and review of the literature[J]. Med Mol Morphol, 2012, 45(1): 45-52. doi: 10.1007/s00795-011-0554-3.

[103] Fatima S, Ahmed A, Suleman S, et al. Utility of MUC4 in the diagnosis of secretory carcinoma of salivary glands[J]. Ann Diagn Pathol, 2023, 67: 152220. doi: 10.1016/j. anndiagpath.2023.152220.

[104] Rooper LM, Karantanos T, Ning Y, et al. Salivary secretory carcinoma with a novel ETV6-MET fusion: expanding the molecular spectrum of a recently described entity[J]. Am J Surg Pathol, 2018, 42(8): 1121-1126. doi: 10.1097/PAS.0000000000001065.

[105] Xu B, Viswanathan K, Umrau K, et al. Secretory carcinoma of the salivary gland: a multi-institutional clinicopathologic study of 90 cases with emphasis on grading and prognostic factors[J]. Histopathology, 2022, 81(5): 670-679. doi: 10.1111/his.14772.

[106] Hamamoto Y, Harada H, Kohara M, et al. Usefulness of immunohistochemistry to distinguish between secretory carcinoma and acinic cell carcinoma in the salivary gland[J]. Med Mol Morphol,

2021, 54(1): 23-30. doi: 10.1007/s00795-020-00256-4.

[107] Venkat S, Fitzpatrick S, Drew PA, et al. Secretory carcinoma of the oral cavity: a retrospective case series with review of literature [J]. Head Neck Pathol, 2021, 15(3): 893-904. doi: 10.1007/s12105-021-01310-y.

[108] Wang S, Peng Y, Jiang C, et al. Case series of secretory carcinoma in the parotid glands[J]. Gland Surg, 2024, 13(11): 2198-2205. doi: 10.21037/gs-24-422.

[109] Salerno E, Abati S, Arrigoni G, et al. Rare tumors of oral cavity: a case report and literature review on secretory carcinoma of minor salivary glands[J]. Clin Exp Dent Res, 2025, 11(4): e70200. doi: 10.1002/cre2.70200.

[110] Baněčková M, Thompson LDR, Hyrcza MD, et al. Salivary gland secretory carcinoma: clinicopathologic and genetic characteristics of 215 cases and proposal for a grading system[J]. Am J Surg Pathol, 2023, 47(6): 661-677. doi: 10.1097/PAS.0000000000002043.

[111] Taverna C, Baněčková M, Lorenzon M, et al. MUC4 is a valuable marker for distinguishing secretory carcinoma of the salivary glands from its mimics[J]. Histopathology, 2021, 79(3): 315-324. doi: 10.1111/his.14251.

[112] Rodríguez Cobo J, Lazuén Fernández S, Mayorga Fernández MM, et al. ETV6-NTRK3-positive parotid mammary analogue secretory carcinoma: a case report[J]. Rom J Morphol Embryol, 2021, 62(1): 309-312. doi: 10.47162/RJME.62.1.34.

[113] Petersson F, Michal M, Ptáková N, et al. Salivary gland mucinous adenocarcinoma with minor (mammary analogue) secretory and low-grade in situ carcinoma components sharing the same ETV6-RET translocation and with no other molecular genetic aberrations detected on NGS analysis[J]. Appl Immunohistochem Mol Morphol, 2020, 28(6): e53. doi: 10.1097/PAI.0000000000000806.

[114] Skálová A, Bradová M, Michal M, et al. Molecular pathology in diagnosis and prognostication of head and neck tumors[J]. Virchows Arch, 2024, 484(2): 215-231. doi: 10.1007/s00428-023-03731-2.

[115] Lee YY, Hwang TZ, Jin YT, et al. Sclerosing microcystic adenocarcinoma arising from the tongue: a case report and literature review [J]. Diagnostics, 2022, 12(5): 1288. doi: 10.3390/diagnostics12051288.

[116] Silva Melo T, Isabelly Rodrigues-Fernandes C, Melo de Lima Morais T, et al. Primary intestinal-type adenocarcinoma: report of a rare case involving a young patient[J]. Oral Oncol, 2024, 150: 106697. doi: 10.1016/j.oraloncology.2024.106697.

[117] Westergaard-Nielsen M, Godballe C, Eriksen JG, et al. Salivary gland carcinoma in Denmark: a national update and follow-up on incidence, histology, and outcome[J]. Eur Arch Otorhinolaryngol, 2021, 278(4): 1179-1188. doi: 10.1007/s00405-020-06205-2.

[118] Spiro RH, Huvos AG, Strong EW. Adenocarcinoma of salivary origin. Clinicopathologic study of 204 patients[J]. Am J Surg, 1982, 144(4): 423-431. doi: 10.1016/0002-9610(82)90416-0.

[119] Żurek M, Jasak K, Jaros K, et al. Clinico-epidemiological analysis of most prevalent parotid gland carcinomas in Poland over a 20-year period[J]. Int J Environ Res Public Health, 2022, 19(16): 10247. doi: 10.3390/ijerph191610247.

[120] Bell D, Kupferman ME, Williams MD, et al. Primary colonic-type adenocarcinoma of the base of the tongue: a previously unreported phenotype[J]. Hum Pathol, 2009, 40(12): 1798-1802. doi: 10.1016/j.humpath.2009.01.028.

[121] AlMaden N, AlYami R, Almotairi A, et al. Relative frequency of primary salivary gland tumors: multicenter study of 796 cases from Riyadh, Saudi Arabia[J]. Medicina, 2024, 60(12): 2022. doi: 10.3390/medicina60122022.

[122] Slova D, Paniz Mondolfi A, Moisini I, et al. Colonic-type adenocarcinoma of the base of the tongue: a case report of a rare neoplasm [J]. Head Neck Pathol, 2012, 6(2): 250-254. doi: 10.1007/s12105-011-0301-z.

（编辑　周春华）

Open Access
This article is licensed under a Creative Commons Attribution 4.0 International License.
Copyright © 2026 by Editorial Department of Journal of Prevention and Treatment for Stomatological Diseases

官网