乳腺癌新辅助化疗疗效预测：基于DCE-MRI瘤内及瘤周区域的影像组学模型

王倩倩[1]，王文娟[2]，崔运福[1]，刘菲菲[2]，姜兴岳[1]，王茹茹[1]
山东医药大学附属医院[1]放射科，[2]超声医学科，山东 滨州 256600

摘要：目的 探讨基于化疗前乳腺癌原发灶动态对比增强磁共振成像（DCE-MRI）瘤内、瘤周区域特征构建影像组学模型对乳腺癌新辅助化疗（NAC）疗效的预测价值。**方法** 回顾性分析2018年1月~2025年7月山东医药大学附属医院具有完整DCE-MRI图像的388例乳腺癌NAC患者，对图像中乳腺癌原发灶及瘤周区域进行病灶分割、影像组学特征提取，采用最小冗余最大相关（mRMR）算法、最小绝对收缩和选择算子（LASSO）回归算法对影像组学特征进行降维筛选，分别构建瘤内模型、瘤周模型及瘤内+瘤周影像组学模型预测乳腺癌NAC疗效，并通过ROC曲线下面积（AUC）及决策曲线评估3种模型的预测性能，通过校准曲线评估性能最佳模型的拟合优度。**结果** DCE-MRI瘤内、瘤周ROI分别提取1361、1286个影像组学特征，最终筛选出与NAC疗效最相关的特征均5个，分别构建瘤内模型、瘤周模型，基于筛选后的共10个特征构建瘤内+瘤周联合模型。联合模型训练队列和验证队列AUC分别为0.913、0.846，高于瘤内模型（AUC=0.845、0.771）、瘤周模型（AUC=0.788、0.747），决策曲线显示联合模型具有较高临床净收益，且瘤内+瘤周联合模型的校准曲线显示预测概率与实际发生概率具有良好的一致性。**结论** 基于化疗前DCE-MRI瘤内及瘤周区域特征构建的影像组学模型能较有效预测乳腺癌患者NAC疗效，辅助临床决策。

关键词：影像组学；磁共振成像；乳腺癌；新辅助化疗；瘤周

Prediction of neoadjuvant chemotherapy efficacy in breast cancer: a radiomics model based on intratumoral and peritumoral regions of DCE-MRI

WANG Qianqian[1], WANG Wenjuan[2], CUI Yunfu[1], LIU Feifei[2], JIANG Xingyue[1], WANG Ruru[1]
[1]Department of Radiology, [2]Department of Ultrasound Medicine, Shandong Medical and Pharmaceutical University Hospital, Binzhou 256600, China

Abstract: Objective To investigate the predictive value of radiomics models developed from pre-neoadjuvant chemotherapy intratumoral and peritumoral features of primary breast lesions on dynamic contrast-enhanced magnetic resonance imaging for neoadjuvant chemotherapy response in breast cancer. **Methods** A total of 388 breast cancer patients with complete pretreatment dynamic contrast-enhanced magnetic resonance imaging who received neoadjuvant chemotherapy at the Shandong Medical and Pharmaceutical University Hospital from January 2018 to July 2025 were retrospectively enrolled. After lesion segmentation and radiomic feature extraction from intratumoral and peritumoral ROIs, feature dimension reduction and selection were performed sequentially using the minimum redundancy maximum relevance algorithm and least absolute shrinkage and selection operator regression. Three radiomics models (intratumoral, peritumoral, and combined intratumoral-peritumoral) were established to predict neoadjuvant chemotherapy response. Model discrimination was assessed via the area under receiver operating characteristic curve and decision curve analysis, and the calibration of the optimal model was verified by calibration curves. **Results** In total, 1361 intratumoral and 1286 peritumoral radiomic features were extracted from dynamic contrast-enhanced magnetic resonance imaging ROIs. Five predictive features were screened for the intratumoral model and another five for the peritumoral model; the combined model was built incorporating all 10 selected features. The combined model achieved AUCs of 0.913 in the training cohort and 0.846 in the validation cohort, superior to the intratumoral model (0.845, 0.771) and peritumoral model (0.788, 0.747). Decision curve analysis demonstrated superior net clinical benefit of the combined model, and its calibration curve revealed favorable consistency between predicted and observed response probabilities. **Conclusion** The intratumoral and peritumoral imaging-based radiomics model before chemotherapy can effectively predict the efficacy of neoadjuvant chemotherapy in breast cancer patients, which is expected to assist clinical decision-making.

Keywords: radiomics; magnetic resonance imaging; breast cancer; neoadjuvant chemotherapy; peritumoral regions

新辅助化疗（NAC）是目前局部晚期乳腺癌患者的标准治疗方案[1]，其可控制肿瘤的发展与扩散[2]。NAC后获得病理完全缓解（pCR）的患者无病生存期和总生存期明显延长、预后更好[3]，但接受NAC的患者若对药物的敏感性差，在治疗过程中则会承担不必要的药物毒副作用及昂贵的治疗费用，甚至导致疾病进展，因此在早期预测乳腺癌新辅助化疗疗效具有重要意义[4]。

超声、MRI等影像学检查方式可对乳腺癌原发灶的变化情况进行估测[5]，相较于超声检查，动态对比增强磁共振成像（DCE-MRI）能更敏感地检测出乳腺残留病灶，并且能反映组织内水分子运动等信息[6]，已成为评估

收稿日期：2025-10-29
基金项目：山东省自然科学基金项目（ZR2023QH231）；滨州医学院科技计划项目（BY2021KJ13）
作者简介：王倩倩，硕士，主治医师，E-mail: wqbyfy77@126.com
通信作者：王茹茹，硕士，主治医师，E-mail: 951886761@qq.com

乳腺癌患者是否获得pCR的有效检查方式。近年来影像组学发展迅速,其可在医学影像图像中提取肿瘤原发灶的高通量综合性信息[7],包括一阶统计特征及高阶纹理特征,通过机器学习算法构建影像组学模型期望辅助临床应用[8]。目前乳腺癌NAC疗效评估主要依赖术后病理结果,操作有创且存在滞后性,因此亟需无创的方式进行预测。凭借海量的影像资料及迅速发展的影像组学技术,目前已有多项研究构建影像组学模型对乳腺癌NAC病理反应进行早期预测[9-11],有研究显示纳入紧邻肿瘤实质部分的正常或接近正常的部分瘤周区域后,包含更多与肿瘤生物学特征相关的信息且构建的预测模型性能得以提高[12],因其包括多种复杂的细胞成分及细胞外基质,一定程度上反映了乳腺癌病灶的异质性及侵袭性,因此瘤内核心病灶与瘤周微环境特征均对NAC疗效具有重要预测价值,但其研究仅局限于HER2阳性乳腺癌单一亚型患者术前靶向治疗的病理反应,并未针对临床应用更广泛的乳腺癌NAC进行疗效预测分析;有学者基于DCE-MRI图像的影像组学模型可有效预测肿瘤缩小模式,肿瘤缩小模式与乳腺癌NAC疗效密切相关,而其仅预测乳腺癌肿瘤缩小模式,未直接探究模型与NAC病理反应的直接关联[13]。因此,本研究拟基于DCE-MRI瘤内及瘤周区域特征构建影像组学模型评估乳腺癌NAC疗效。

1 资料与方法

1.1 一般资料

收集山东医药大学附属医院2018年1月~2025年7月接受NAC的乳腺癌患者的临床信息及DCE-MRI图像。纳入标准:治疗前病理证实为乳腺癌,且术前穿刺活检免疫组化及术后病理信息完整;治疗前进行MRI平扫及增强检查;乳腺癌患者完整化疗周期后接受手术,化疗中无化疗方案变更。排除标准:图像存在明显伪影;合并其它肿瘤病史;未完成完整化疗周期即进行手术;中途变更化疗方案及临床药物试验患者;发生远处转移。最终共纳入NAC患者388例。乳腺癌患者NAC疗效的评估标准为Miller-Payne分级:1~4级均表现为不同程度的肿瘤细胞残留,5级表现为肿瘤细胞完全消失或仅导管原位癌存在。1~4级或腋窝淋巴结阳性定义为非pCR,5级且腋窝淋巴结阴性定义为pCR[14]。将纳入的388例乳腺癌患者按照7:3随机划分为训练队列271例,验证队列117例,随机种子为2532,年龄25~73(48.3±7.1)岁。根据病理受体状态将乳腺癌分为4种分子亚型:Luminal A型、Luminal B型、HER-2过表达型、三阴型。本研究遵守《赫尔辛基宣言》,经滨州医学院附属医院科研伦理委员会批准(审批号:2023-KT-05),免除受试者知情同意。

1.2 DCE-MRI图像采集

所有NAC患者化疗前均采用GE Signal 3.0T扫描仪进行检查,乳腺专用8通道相控线圈,采用高压注射器经手臂静脉注射,统一对比剂剂量0.1 mmol/kg(0.2 mL/kg),流率2.0 mL/s。横轴面VIBRANT多时相动态增强扫描:连续无间隔扫描8次,控制时间60 s/次,TR 6.03 ms,TE 2.9 ms,层厚3.2 mm,层间距0 mm,矩阵512×512,FOV 360 mm。脂肪抑制采用频率选择性脂肪抑制。由1位工作10年以上的高年资放射科医师对DCE-MRI图像进行图像质量控制,以DICOM格式导出至硬盘。

1.3 影像组学特征提取与筛选

基于时间-信号强度曲线选取强化峰值期DCE-MRI第3期图像[13]导入3DSlicer5.4.0软件,由2位具有5年以上工作经验的放射诊断医师对乳腺癌病灶进行逐层勾画,获得瘤内感兴趣区域(VOI),设置参数扩展瘤周5 mm[15],获得瘤周感兴趣区域(图1)。利用Pyradiomics包从病灶瘤内和瘤周ROI中分别提取影像组学特征,包括一阶统计特征及高阶纹理特征。设置特征提取参数:在特征提取前,对影像进行像素间距重采样,统一为1 mm×1 mm×1 mm,以保证不同病例之间体素尺寸一致性。插值方式采用B样条插值法,以在重采样过程中保持影像灰度的平滑与连续性。灰度归一化用于减少不同扫描条件对灰度分布造成的影响。灰度离散化的分箱宽度根据计算不同分箱宽度下特征的组内相关系数(ICC)值和预测模型AUC变化选择最优值为25,以构建灰度直方图和纹理矩阵时划分灰度级区间。ICC双向随机效应评价2位医师单次勾画、提取影像组学特征的一致性,大于0.75认为一致性良好,并通过最小冗余最大相关性(mRMR)算法、最小绝对收缩和选择算子(LASSO)回归算法筛选影像组学特征。训练队列与验证队列划分在特征提取与标准化之前完成,特征筛选过程和模型训练均严格限定在训练队列内完成,验证队列数据在最终模型评估前完全隔离,以防止任何形式的信息泄漏。

1.4 NAC疗效预测模型构建与性能评估

筛选出DCE-MRI图像瘤内与瘤周的最佳影像组学特征,采用多因素逻辑回归算法分别构建瘤内模型、瘤周模型、瘤内+瘤周联合模型。标准化仅以训练队列拟合,在验证队列进行模型性能验证,采用ROC曲线下面积(AUC)、准确度、敏感度、特异度及决策曲线评估3个模型对乳腺癌NAC疗效的预测效能,为避免数据划分的偶然性且不牺牲样本,应用Bootstrap自助重抽样迭代1000次对模型进行内部验证,并计算模型的平均AUC,并为最佳模型绘制校准曲线评估模型的拟合优度。

1.5 统计学分析

采用SPSS27.0、R4.3.1软件进行统计分析。符合正态分布的计量资料以均数±标准差表示,采用独立样本t检验进行组间比较;计数资料以n(%)表示,采用χ^2检验进行组间比较。采用DeLong检验分析各个模型之间的AUC差异。以P<0.05为差异有统计学意义。

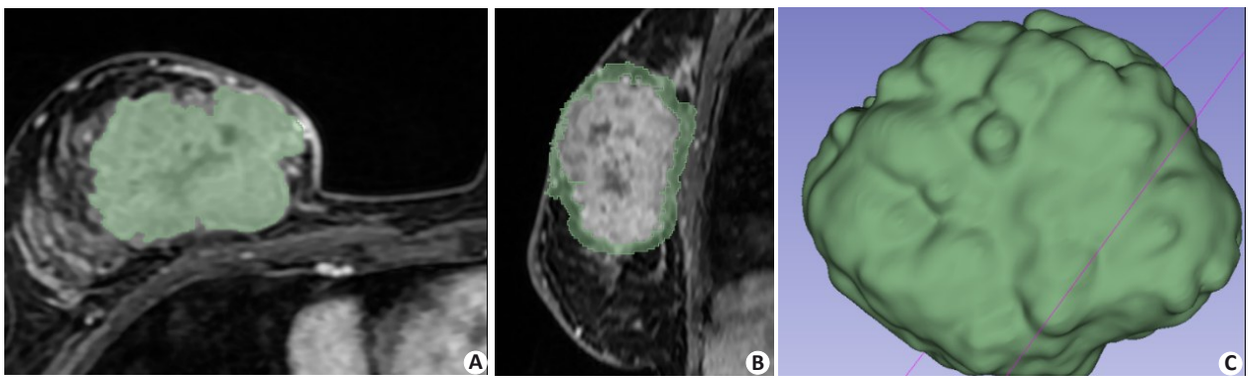

图1 乳腺癌原发灶及分割示意图

Fig.1 Schematic diagram of primary breast cancer lesions and segmentation. **A:** Manual delineation of intratumoral ROI on breast cancer DCE-MRI; **B:** Peritumoral region automatically expanded by 5 mm; **C:** 3D VOI generated via slice-by-slice delineation on DCE-MRI in breast cancer patients.

2 结果

2.1 患者一般资料比较

纳入的患者中Luminal A型85例(21.9%),Luminal B型155例(39.9%),HER-2过表达型70例(18.0%),三阴型乳腺癌78例(20.1%)。根据术后病理统计pCR患者128例(训练队列97例,验证队列31例),npCR患者260例(训练队列174例,验证队列86例)。训练队列与验证队列临床病理信息比较差异均无统计学意义(P>0.05,表1)。

表1 训练队列中pCR组与非pCR组NAC患者的临床病理资料比较

Tab.1 Comparison of clinicopathological data between pCR and non-pCR groups in the training cohort of patients with breast cancer undergoing neoadjuvant chemotherapy.

Feature	pCR (n=97)	npCR (n=174)	χ^2/t	P
Age (year, *Mean*±*SD*)	47.1±8.4	48.1±10.3	1.564	0.092
Histological grade [n(%)]			1.791	0.408
Ⅰ	3(3.09)	12(6.89)		
Ⅱ	58(59.79)	100(57.47)		
Ⅲ	36(37.11)	62(35.63)		
ER [n(%)]			14.572	< 0.001
Negative	16(16.49)	88(50.57)		
Positive	81(83.50)	86(49.43)		
PR [n(%)]			6.489	0.011
Negative	36(37.12)	108(62.06)		
Positive	61(62.88)	66(37.93)		
HER-2 [n(%)]			7.260	0.007
Negative	56(57.73)	56(32.18)		
Positive	41(42.26)	118(67.81)		
Ki-67 [n(%)]			0.117	0.732
Negative	21(21.64)	35(20.00)		
Positive	76(78.35)	139(80.00)		

ER: Estrogen receptor; PR: Progesterone receptor; HER-2: Human epidermal growth factor receptor 2; pCR: Pathologic complete response.

2.2 影像组学特征提取及模型建立

DCE-MRI瘤内及瘤周ROI中分别提取了1361、1286个影像组学特征,首先剔除414、322个ICC值<0.75的特征;采用mRMR、LASSO算法从瘤内影像组学特征中筛选出5个最佳组学特征,分别为wavelet.HHH_firstorder_Entropy、wavelet.LLL_firstorder_Skewness、square_firstorder_Minimum、wavelet.HLL_glrlm_GrayLevelVariance、wavelet.LHH_glszm_Small-

AreaLowGrayLevelEmphasis；瘤周影像组学特征中筛选出5个最佳组学特征，分别为original_shape_Elongation、wavelet.HLH_glcm_SumSquares、wavelet.LLL_firstorder_Minimum、wavelet.LLH_glcm_SumEntropy、exponential_firstorder_Minimum，其归属类别（表2），各影像组学特征权重（图2），基于上述提取的影像组学特征采用多因素逻辑回归算法分别构建瘤内模型、瘤周模型及两者联合的瘤内+瘤周模型。公式=0.7634×wavelet.LLH_glcm_SumEntropy+0.6435×wavelet.HHH_firstorder_Entropy+0.6164×exponential_firstor-der_Minimum+0.5325×original_shapeElongation+0.2829×wavelet.LHH_glszm_SmallAreaLowGrayLev-el-Emphasis+0.1931×wavelet.HLH_glcm_SumSquar-es+0.2015×wavelet.HLL_glrlm_GrayLevelVariance+0.1283×square_firstorder_Minimum-0.3763×wavelet.LLL_firstorder_Skewness-0.8123×wavelet.LLL_-first-order_Minimum-0.7466。

表2 经mRMR及LASSO算法筛选出的各预测模型影像组学特征名称及类别

Tab.2 Names and categories of radiomic features for each predictive model screened by mRMR and LASSO algorithms

Region	Selected Radiomic Features	Feature Category
Intratumoral	wavelet.LLH_glcm_SumEntropy	GLCM
	wavelet.HHH_firstorder_Entropy	First-order statistics
	exponential_firstorder_Minimum	Exponential transformed feature
	original_shape_Elongation	Morphological feature
	wavelet.LHH_glszm	GLSZM
	wavelet.HLH_glcm_SumSquares	GLCM
	wavelet.HLL_glrlm_GrayLevelVariance	GLRLM
Peritumoral	square_firstorder_Minimum	Squared transformed feature
	wavelet.LLL_firstorder_Skewness	First-order statistics
	wavelet.LLL_firstorder_Minimum	First-order statistics

GLCM: Gray-Level Co-occurrence Matrix; GLSZM: Gray-Level Size Zone Matrix; GLRLM: Gray-Level Run Length Matrix.

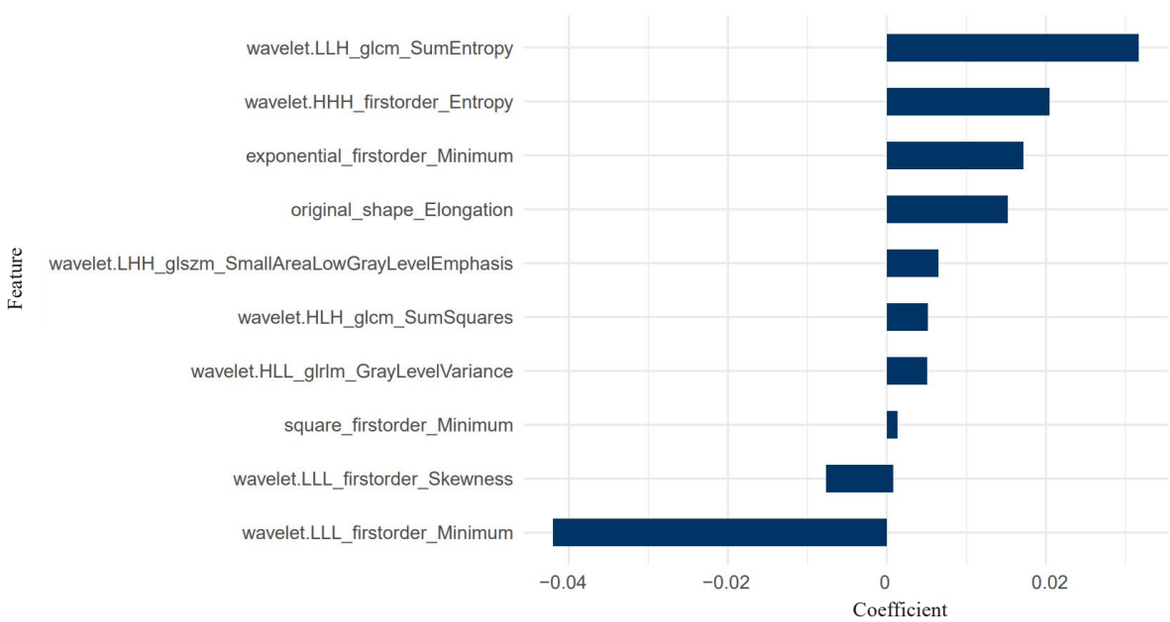

图2 通过mRMR及LASSO算法筛选的瘤内+瘤周模型影像组学特征重要程度可视化

Fig. 2 Visualization of the importance of radiomic features in the combined intratumoral and peritumoral model screened by mRMR and LASSO algorithms. The horizontal axis denotes the regression coefficient of each feature, reflecting the direction and strength of its influence on prediction results. Positive coefficients represent higher feature values. The vertical axis lists feature names sorted by the absolute values of coefficients in descending order.

2.3 模型验证

在训练队列和验证队列中，瘤内组学模型预测NAC疗效的AUC分别为0.845、0.771，瘤周模型预测NAC疗效的AUC分别为0.788、0.747，瘤内+瘤周模型的AUC增加至0.913、0.846，训练队列准确度为87.9%，敏感度为81.5%，特异度为89.9%，均高于单独的瘤内及瘤周模型（图3A、B，表3）。Delong检验显示，瘤内+瘤周模型与瘤内模型和瘤周模型的差异均有统计学意义（FDR校正前原始P=0.027、0.014，FDR校正P=0.041、0.021）；Bootstrap自助重抽样法迭代1000次内部验证计算得到平均AUC=0.900（标准差：0.025，95% *CI*：0.802~0.948），具有较好的稳定性。决策曲线显示瘤内+瘤周模型具有较好的临床应用效能（图3C、D）。校准曲线显示瘤内+瘤周模型的预测发生概率与实际发生概率之间有很好的一致性（图4）。

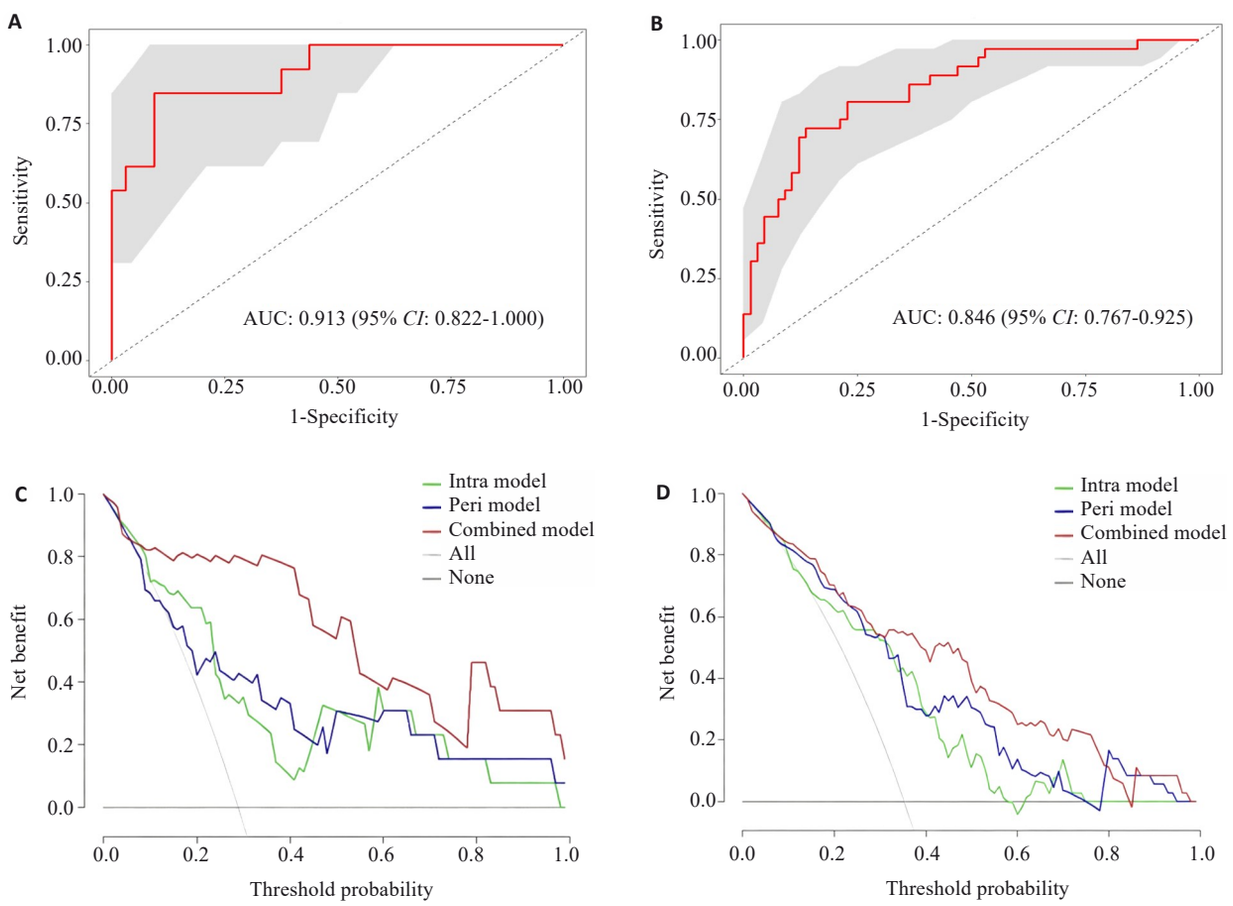

图3 3种NAC疗效预测模型的ROC曲线及决策曲线

Fig.3 Three ROC curves and decision curves of three NAC efficacy prediction models. **A:** ROC curves of the training cohort; **B:** ROC curves of the validation cohort; **C:** Decision curves of the training cohort; **D:** Decision curves of the validation cohort.

3 讨论

由于存在肿瘤异质性和个体差异性，乳腺癌患者的NAC疗效具有较大差异，导致其预后不同[16]，仅19%~30%的患者NAC后获得pCR[17, 18]，5%~20%的患者出现疾病进展。早期无创、准确预测乳腺癌患者是否获得pCR，能辅助临床医师及时更改治疗方案和手术决策，有助于实现个体化精准治疗[19]。

DCE-MRI是乳腺癌NAC疗效的常用检查方式，可作为监测残余肿瘤的有效工具[20]，其不仅可以显示病灶静态解剖信息，也可显示乳腺肿瘤组织血流动力学特点[21]，并且借助影像组学技术构建预测模型可最大化的辅助临床应用。影像组学是通过在医学影像图像中自动、高通量的提取影像组学特征[10]，运用机器学习算法构建二分类预测模型，采用治疗前乳腺癌原发灶的图像输出概率值预测患者是否获得病理完全缓解，即临床医师可用于评估NAC疗效以更加科学地早期、无创地预判患者并及时的调整治疗策略[22, 23]。一项关于影像组学与表观遗传分子特征的关联及定量关系的研究发现，基于T1+C和T2WI序列结合肿瘤内和肿瘤周围影像组学特征的深度学习模型与无复发生存期显著相关，并且对无复发生存期具有较高的预测价值[24]，NAC疗效早期无创预测对于乳腺癌患者的治疗决策至关重要，而其尚未分析NAC疗效的预测价值。有研究发现不同的VOI会导致影像组学特征值与模型预测性能的显著差

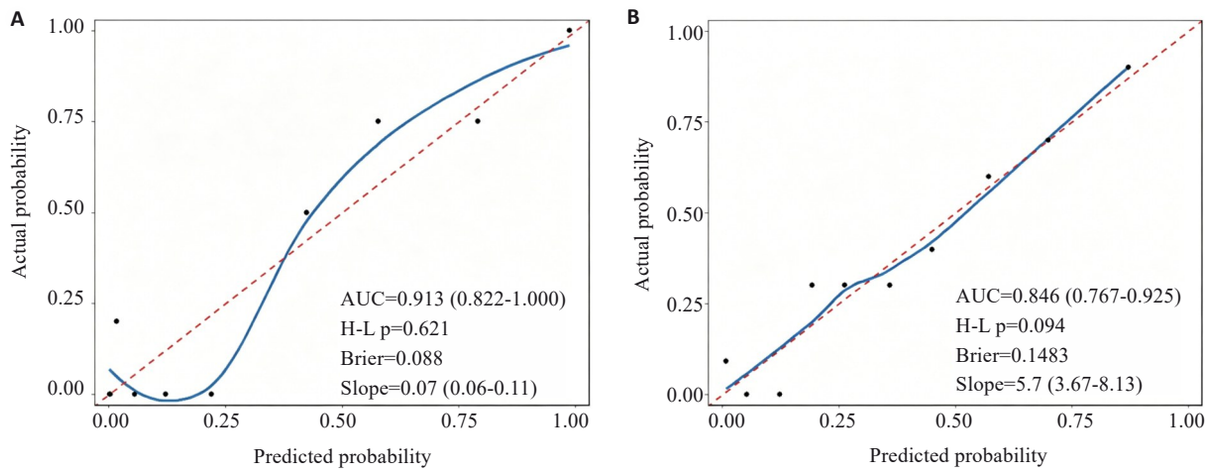

图4 瘤内+瘤周影像组学模型校准曲线

Fig. 4 Calibration curve of intratumoral and peritumoral radiomics model. **A:** Calibration curve of training cohort; **B:** Calibration curve of validation cohort. Red dashed line: Ideal calibration (predicted probability = actual incidence); Blue solid line: Fitted prediction curve of the established model.

异，包括瘤周区域特征的VOI预测性能更高，结果显示本研究瘤内+瘤周模型较单独的瘤内及瘤周模型性能得以提高，AUC值分别为0.913、0.846，并且模型进行Bootstrap内部验证模型的稳定性，Delong检验表明瘤内+瘤周模型的性能提升具有统计学意义且能有效控制多重比较带来的假阳性风险，决策曲线显示由于阈值概率低于20%表示乳腺癌患者全部接受新辅助化疗，而高于60%表示仅在高度怀疑有效的乳腺癌患者中才考虑新辅助化疗，20%~60%的主要临床决策区间内，或可为患者个体的NAC疗效评估及方案选择提供参考[25]。

乳腺癌作为一种高度异质性的恶性肿瘤，其病理特征不仅体现在形态学上的多样性，还涉及复杂的分类、分级及分子分型等方面。因此，深入解析乳腺癌的发生与发展机制对于临床诊疗策略的制定具有重要意义。肿瘤细胞的生物学行为受到肿瘤微环境的影响，尤其是瘤周区域对肿瘤进展及转移的影响不可忽视[26]。有研究纳入磁共振DWI和DCE-MRI两个序列进行NAC疗效预测，结果显示DCE-MRI影像组学模型性能（AUC=0.870）远高于DWI影像组学模型（AUC=0.695），但尚未分析瘤周细胞与微环境信息在肿瘤发生发展中的作用[27]。有学者采用DCE-MRI预测乳腺癌Ki-67表达水平的研究中，基于DCE-MRI图像的瘤内影像组学模型AUC仅为0.689，联合瘤周5 mm范围后AUC提升至0.862，即瘤周影像组学特征的纳入有效提高了模型的预测效能[28]；有学者基于DCE-MRI影像组学模型对乳腺癌前哨淋巴结转移情况进行预测，结果显示DCE-MRI瘤内+瘤周模型预测效能最佳（AUC=0.897）[29]；有研究采用瘤周3 mm研究结果显示模型之间的差异无统计学意义[30]，多项研究显示联合瘤周5 mm预测效能更佳[15, 20, 31]。基于此，本研究将DCE-MRI图像乳腺癌病灶外扩5 mm，构建影像组学模型预测NAC疗效，结果显示瘤周特征的加入使影像组学模型的AUC从0.845提高至0.913，因此瘤周影像组学特征对乳腺癌NAC疗效的有不可忽视的预测价值，乳腺癌肿瘤细胞与其周边微环境之间的相互作用影响肿瘤进程[15]，但具体调控机制仍需进一步研究探索[32, 33]。

深入分析影像组学特征的生物学意义可提高其临床应用价值[34-36]。影像组学一阶特征为单一像素或体素特征[20]，纹理特征包括灰度行程矩阵（GLRLM）、小波特征、邻域灰调差矩阵（NGTDM）、灰度共生矩阵（GLCM）等。影像组学特征综合了病灶的基因、代谢和转录等综合信息，本研究最终筛选7个小波特征、square_firstorder_Minimum、original_shape_Elongation和exponential_firstorder_Minimum，包括了图像中的病灶的形状、强度等信息，其中小波特征占较大比重，小波特征的核心在于提取表征图像边缘与细节的高频信息。本研究观察到nPCR组小波特征值降低，提示病灶可能因内部坏死、液化而边界模糊、纹理均质，其高频空间细节信息随之减少。有研究分析影像组学特征与语义特征的相关性以发现新型无创生物标志物[7]，但仍需进一步研究验证。

本研究具有一定的局限性：本研究为单中心回顾性分析，研究样本量较少；尽管通过Bootstrap重抽样进行了严格的内部验证，但模型缺乏完全独立的外部队列验证，并且缺少临床参数模型对比分析，未来拟扩大数据量并进一步探索多参数、多序列模型对NAC疗效的预测价值。

综上所述，基于化疗前乳腺癌原发灶DCE-MRI瘤内及瘤周区域特征构建的影像组学模型对乳腺癌NAC疗效具有潜在应用价值，有望为患者的治疗决策提供有效依据。

参考文献：

[1] Cardoso MJ, Poortmans P, Senkus E, et al. Breast cancer highlights from 2023: Knowledge to guide practice and future research[J]. Breast, 2024, 74: 103674.

[2] Caballo M, Sanderink WBG, Han LY, et al. Four-dimensional machine learning radiomics for the pretreatment assessment of breast cancer pathologic complete response to neoadjuvant chemotherapy in dynamic contrast-enhanced MRI[J]. J Magn Reson Imaging, 2023, 57(1): 97-110.

[3] Wu L, Ye WT, Liu Y, et al. An integrated deep learning model for the prediction of pathological complete response to neoadjuvant chemotherapy with serial ultrasonography in breast cancer patients: a multicentre, retrospective study[J]. Breast Cancer Res, 2022, 24 (1): 81.

[4] Xu N, Guo XB, Ouyang ZQ, et al. Multiparametric MRI-based radiomics combined with pathomics features for prediction of the efficacy of neoadjuvant chemotherapy in breast cancer[J]. Heliyon, 2024, 10(2): e24371.

[5] Choudhery S, Gomez-Cardona D, Favazza CP, et al. MRI radiomics for assessment of molecular subtype, pathological complete response, and residual cancer burden in breast cancer patients treated with neoadjuvant chemotherapy[J]. Acad Radiol, 2022, 29: S145-54.

[6] Zhang BY, Yu YM, Mao Y, et al. Development of MRI-based deep learning signature for prediction of axillary response after NAC in breast cancer[J]. Acad Radiol, 2024, 31(3): 800-11.

[7] Zhou JY, Bai YS, Zhang Y, et al. A preoperative radiogenomic model based on quantitative heterogeneity for predicting outcomes in triple-negative breast cancer patients who underwent neoadjuvant chemotherapy[J]. Cancer Imaging, 2024, 24(1): 98.

[8] Liu Z, Li Z, Qu J, et al. Radiomics of multiparametric MRI for pretreatment prediction of pathologic complete response to neoadjuvant chemotherapy in breast cancer: a multicenter study[J]. Clin Cancer Res, 2019, 25(12): 3538-47.

[9] Hottat NA, Badr DA, Lecomte S, et al. Value of diffusion-weighted MRI in predicting early response to neoadjuvant chemotherapy of breast cancer: comparison between ROI-ADC and whole-lesion-ADC measurements[J]. Eur Radiol, 2022, 32(6): 4067-78.

[10] Huang JX, Wu L, Wang XY, et al. Delta radiomics based on longitudinal dual-modal ultrasound can early predict response to neoadjuvant chemotherapy in breast cancer patients[J]. Acad Radiol, 2024, 31(5): 1738-47.

[11] Guo LC, Du SY, Gao S, et al. Delta-radiomics based on dynamic contrast-enhanced MRI predicts pathologic complete response in breast cancer patients treated with neoadjuvant chemotherapy[J]. Cancers, 2022, 14(14): 3515.

[12] Braman N, Prasanna P, Whitney J, et al. Association of peritumoral radiomics with tumor biology and pathologic response to preoperative targeted therapy for*HER2 (ERBB2)* – positive breast cancer[J]. JAMA Netw Open, 2019, 2(4): e192561.

[13] Fan M, Wu XL, Yu JD, et al. Multiparametric MRI radiomics fusion for predicting the response and shrinkage pattern to neoadjuvant chemotherapy in breast cancer[J]. Front Oncol, 2023, 13: 1057841.

[14] Ogston KN, Miller ID, Payne S, et al. A new histological grading system to assess response of breast cancers to primary chemotherapy: prognostic significance and survival[J]. Breast, 2003, 12(5): 320-7.

[15] Mao N, Shi YH, Lian C, et al. Intratumoral and peritumoral radiomics for preoperative prediction of neoadjuvant chemotherapy effect in breast cancer based on contrast-enhanced spectral mammography[J]. Eur Radiol, 2022, 32(5): 3207-19.

[16] Guo JM, Meng WJ, Li Q, et al. Pretreatment sarcopenia and MRI-based radiomics to predict the response of neoadjuvant chemotherapy in triple-negative breast cancer[J]. Bioengineering, 2024, 11(7): 663.

[17] Zannetti A. Breast cancer: from pathophysiology to novel therapeutic approaches 2.0[J]. Int J Mol Sci, 2023, 24(3): 2542.

[18] Shi ZW, Huang XM, Cheng ZL, et al. MRI-based quantification of intratumoral heterogeneity for predicting treatment response to neoadjuvant chemotherapy in breast cancer[J]. Radiology, 2023, 308: e222830.

[19] Gu JH, Tong T, Xu D, et al. Deep learning radiomics of ultrasonography for comprehensively predicting tumor and axillary lymph node status after neoadjuvant chemotherapy in breast cancer patients: a multicenter study[J]. Cancer, 2023, 129(3): 356-66.

[20] Huang YH, Zhu T, Zhang XL, et al. Longitudinal MRI-based fusion novel model predicts pathological complete response in breast cancer treated with neoadjuvant chemotherapy: a multicenter, retrospective study[J]. eClinicalMedicine, 2023, 58: 101899.

[21] Yu YF, He ZF, Ouyang J, et al. Magnetic resonance imaging radiomics predicts preoperative axillary lymph node metastasis to support surgical decisions and is associated with tumor microenvironment in invasive breast cancer: a machine learning, multicenter study[J]. eBioMedicine, 2021, 69: 103460.

[22] Bitencourt AGV, Gibbs P, Rossi Saccarelli C, et al. MRI-based machine learning radiomics can predict HER2 expression level and pathologic response after neoadjuvant therapy in HER2 overexpressing breast cancer[J]. EBioMedicine, 2020, 61: 103042.

[23] Zhang H, Cao W, Liu LJ, et al. Noninvasive prediction of node-positive breast cancer response to presurgical neoadjuvant chemotherapy therapy based on machine learning of axillary lymph node ultrasound[J]. J Transl Med, 2023, 21(1): 337.

[24] Yu YF, Ren W, He ZF, et al. Machine learning radiomics of magnetic resonance imaging predicts recurrence-free survival after surgery and correlation of LncRNAs in patients with breast cancer: a multicenter cohort study[J]. Breast Cancer Res, 2023, 25(1): 132.

[25] Hatamikia S, George G, Schwarzhans F, et al. Breast MRI radiomics and machine learning-based predictions of response to neoadjuvant chemotherapy-How are they affected by variations in tumor delineation [J]. Comput Struct Biotechnol J, 2024, 23: 52-63.

[26] Zhu Y, Zhang SN, Wei W, et al. Intra- and peritumoral radiomics nomogram based on DCE-MRI for the early prediction of pathological complete response to neoadjuvant chemotherapy in breast cancer[J]. Front Oncol, 2025, 15: 1561599.

[27] Jiang WY, Meng RQ, Cheng Y, et al. Intra- and peritumoral based radiomics for assessment of lymphovascular invasion in invasive breast cancer[J]. J Magn Reson Imaging, 2024, 59(2): 613-25.

[28] 明 洁, 陈 莹, 刘 莹, 等. 基于DCE-MRI瘤内联合瘤周影像组学模型术前预测乳腺癌Ki-67表达状态的价值[J]. 磁共振成像, 2022, 13 (10): 132-7, 149.

[29] Cheng Y, Xu S, Wang H, et al. Intra- and peri-tumoral radiomics for predicting the sentinel lymph node metastasis in breast cancer based on preoperative mammography and MRI[J]. Front Oncol, 2022, 12: 1047572.

[30] Yoshida K, Kawashima H, Kannon T, et al. Prediction of pathological complete response to neoadjuvant chemotherapy in breast cancer using radiomics of pretreatment dynamic contrast-enhanced MRI[J]. Magn Reson Imaging, 2022, 92: 19-25.

[31] Zhou JJ, Zhang Y, Chang KT, et al. Diagnosis of benign and malignant breast lesions on DCE-MRI by using radiomics and deep learning with consideration of peritumor tissue[J]. J Magn Reson Imaging, 2020, 51(3): 798-809.

[32] Zhao Y, Shen ML, Wu LQ, et al. Stromal cells in the tumor microenvironment: accomplices of tumor progression [J]. Cell Death Dis, 2023, 14: 587.

[33] Zhang JQ, Wu Q, Yin W, et al. Development and validation of a radiopathomic model for predicting pathologic complete response to neoadjuvant chemotherapy in breast cancer patients[J]. BMC Cancer, 2023, 23(1): 431.

[34] Lee HJ, Lee JH, Lee JE, et al. Prediction of early clinical response to neoadjuvant chemotherapy in Triple-negative breast cancer: Incorporating Radiomics through breast MRI[J]. Sci Rep, 2024, 14: 21691.

[35] Zheng GY, Hou J, Shu ZY, et al. Prediction of neoadjuvant chemotherapy pathological complete response for breast cancer based on radiomics nomogram of intratumoral and derived tissue [J]. BMC Med Imaging, 2024, 24(1): 22.

[36] Zhu T, Huang YH, Li W, et al. Multifactor artificial intelligence model assists axillary lymph node surgery in breast cancer after neoadjuvant chemotherapy: multicenter retrospective cohort study [J]. Int J Surg, 2023, 109(11): 3383-94.

（编辑:郎 朗）