

Case Report

Asian Pacific Journal of Tropical Medicine

apjtm.org

doi: 10.4103/apjtm.apjtm_108_24

American tegumentary leishmaniasis mimicking myiasis and granulomatous vasculitis: A case report

Victoria J Arrieta[1], Gastón Morea[2], Leticia M Tennerini[2], María V. Sanchez[1], Esteban S Lozano[1,3], Diego E Cargnelutti[1,3]✉

[1]*Instituto de Medicina y Biología Experimental de Cuyo (IMBECU), Consejo Nacional de Investigaciones Científicas y Técnicas (CONICET), Universidad Nacional de Cuyo (UNCuyo), Mendoza, Argentina*

[2]*Hospital Luis C. Lagomaggiore, Mendoza, Argentina*

[3]*Facultad de Ciencias Médicas (FCM), Universidad Nacional de Cuyo (UNCuyo), Mendoza, Argentina*

ABSTRACT

Rationale: American tegumentary leishmaniasis comprises cutaneous and mucocutaneous manifestations caused by parasitic infections by various *Leishmania* species. This report details the clinical interventions for a patient with American tegumentary leishmaniasis in Mendoza, Argentina, a non-endemic region.

Patient concerns: A 43-year-old male was admitted to a tertiary care hospital in Mendoza, Argentina Republic with a history of progressive nasal discharge, septal perforation, facial pain, and pruritus. Despite treatment for presumed nasal myiasis and vasculitis with granulomatosis, symptoms persisted.

Diagnosis: American tegumentary leishmaniasis.

Interventions: Intravenous liposomal amphotericin B.

Outcomes: Follow-up at 30 days showed no recurrence of symptoms with a remarkable clinical improvement of the nasal lesion.

Lessons: This case sheds light on the necessity of accurate identification for timely intervention and the need to recognize the diverse manifestations of American tegumentary leishmaniasis to avoid misdiagnosis.

KEYWORDS: *Leishmania*; American tegumentary leishmaniasis; Diagnosis methods; Myasis; Vasculitis and granulomatosis; Case report

1. Introduction

In the Americas, cases of American tegumentary leishmaniasis (ATL) extend from the southern United States to northern Argentina. In regions where the disease is endemic, elevated morbidity rates are observed, while in areas where it is less common, it is frequently misdiagnosed as other granulomatous skin pathologies[1]. The diagnosis of ATL can be challenging due to the variety of clinical manifestations, the limited sensitivity and specificity of serological tests, and the risk of superinfection in the lesions[2,3]. However, the main issue lies in the lack of knowledge among healthcare professionals regarding neglected tropical diseases[1]. To the best of our knowledge, no similar case has been reported in the literature in our region. This is the first reported case of ATL masquerading as myiasis and granulomatous vasculitis. This article describes a case of concurrent ATL in a patient with a recent history of nasosinusal

✉To whom correspondence may be addressed. E-mail: diegocargnelutti@hotmail.com

This is an open access journal, and articles are distributed under the terms of the Creative Commons Attribution-Non Commercial-ShareAlike 4.0 License, which allows others to remix, tweak, and build upon the work non-commercially, as long as appropriate credit is given and the new creations are licensed under the identical terms.

For reprints contact: reprints@medknow.com

©2024 *Asian Pacific Journal of Tropical Medicine* Produced by Wolters Kluwer-Medknow.

How to cite this article: Arrieta VJ, Morea G, Tennerini LM, Sanchez MV, Lozano ES, Cargnelutti DE. American tegumentary leishmaniasis mimicking myiasis and granulomatous vasculitis: A case report. Asian Pac J Trop Med 2024; 17(10): 473-476.

Article history: Received 15 February 2024 Revision 20 October 2024
Accepted 21 October 2024 Available online 26 October 2024

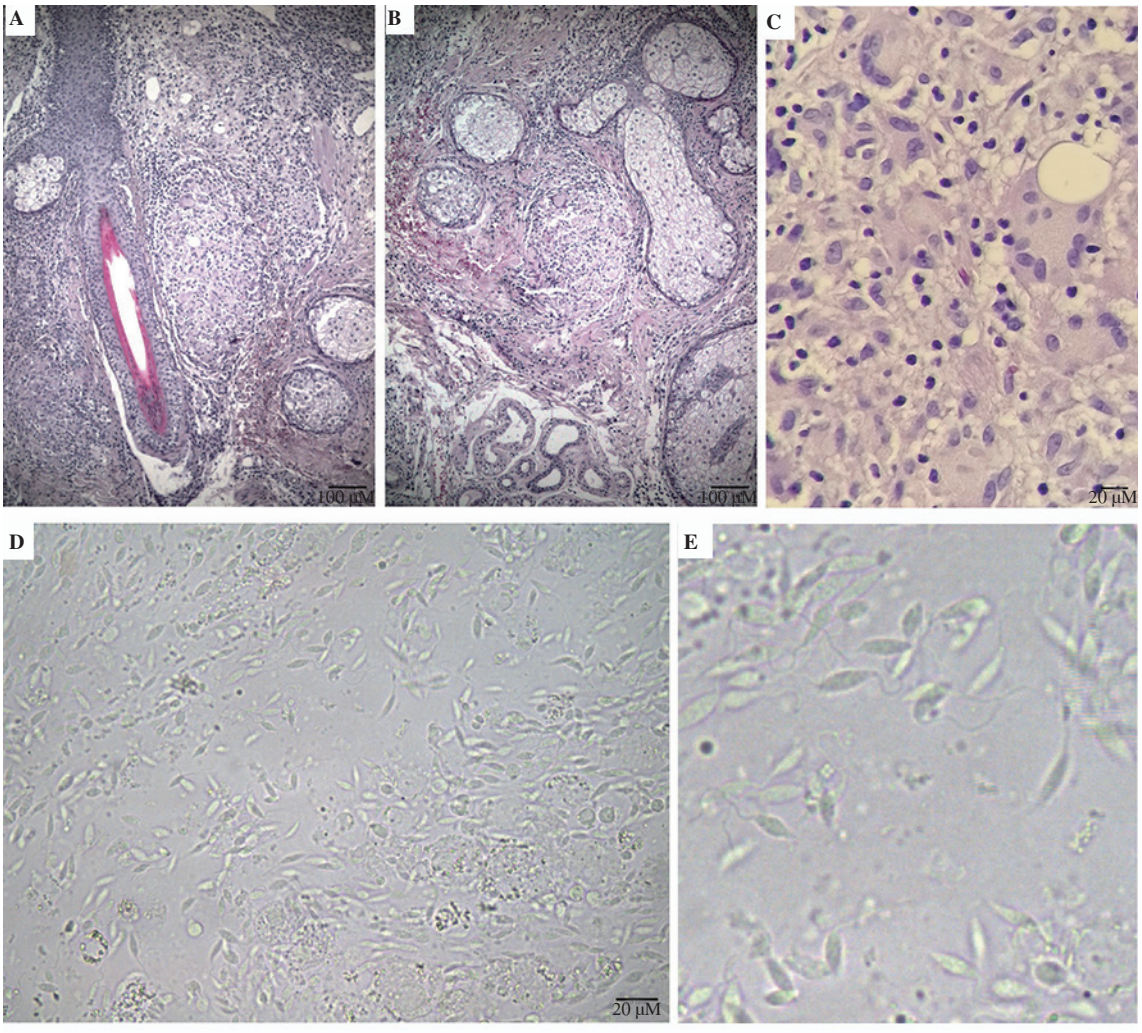

Figure 1. Vascular damage in the nasal mucosa of a 43-year-old male is characterized by endothelial swelling, thickened walls, and extravasated erythrocytes, 40× magnification (A). Granuloma in deep reticular dermis, 40× magnification (B). At higher magnification, empty vacuoles are seen within giant cells in a necrobiotic granuloma, 60× magnification (C). Three months after treatment failure due to misdagnosis, the patient's nasal lesions tissues were sent for culture, and *Leishmania* spp. promastigotes was observed under optic microscopy, 40× magnification (D). Zoom of Figure 1D (E).

myiasis infestation, initially misdiagnosed as vasculitis with granulomatosis. This case highlights the importance of including American tegumentary leishmaniasis as a differential diagnosis, even in areas where the disease is not prevalent. Furthermore, maintaining a broad differential diagnosis is critical, even when dealing with lesions that seem characteristic of a particular condition, as many infectious agents can present with similar features.

2. Case presentation

A 43-year-old male was admitted to a third-level hospital in Mendoza, Argentina. The patient was born in the Plurinational State of Bolivia, with a history of frequent travel to the rainforests. The patient reported the presence of small, immobile ectoparasites and whitish larval remains in the nostril for two months. The day before hospitalization, he reported extracting two larvae from the nostril and applying basil leaves. The physical examination showed the presence of larvae in the nasal fossa with erythema and tenderness of the facial area. Devitalized tissue and septal perforation were found in the nasal cavity. Blood tests revealed leukocytosis with neutrophilia and an elevation of systemic inflammation markers as erythrocyte sedimentation rate with 66 mm/h (reference value: 0-15 mm/h) and C-reactive protein with 28 mg/L (reference value: 0-5 mg/L).

A diagnosis of cutaneous myiasis (sinonasal myiasis) was made, and the patient was prescribed clindamycin (600 mg every 8 hours intravenously) and ampicillin-sulbactam (1 500 mg every six hours intravenously). The patient underwent rhino-sinusal videoendoscopic

surgical exploration to remove larvae and devitalized granulomatous mucosa.

After two months, during follow-up visits, the patient showed signs of inflammation in both vestibules and had a nasal septum perforation with partial erosion. He was readmitted for facial cellulitis and prescribed parenteral antibiotic therapy with vancomycin (1 000 mg every 12 hours intravenously) and piperacillin-tazobactam (4 500 mg every six hours intravenously). Nasal mucosa biopsies showed the presence of granulomas composed of histiocytes in the mid-dermis, multinucleate giant cells, mostly Langhans type, surrounded by a peripheral rim of lymphocytes. The nasal mucosa was characterized by endothelial swelling, thickened walls, and extravasated erythrocytes (Figure 1A). Granuloma in the deep reticular dermis (Figure 1B). At higher magnification, empty vacuoles were observed within giant cells in a necrobiotic granuloma (Figure 1C). With these results, the patient received a diagnosis of vasculitis with granulomatosis. Microbiology tests for mycobacteriosis were negative. Even with medical treatment, the patient continued to experience nasal discharge with septum perforation, facial pain, and pruritus (Supplementary Figure 1A).

Three months after his last visit to the hospital, the patient's nasal lesions did not improve over time, and he was referred to the Parasitology Area at the School of Medicine of the National University of Cuyo (UNCuyo)/National Council for Scientific and Technical Research to diagnosis whether there is *Leishmania* infection. After six days of culture, *Leishmania* spp. promastigotes were observed under an optical microscope (Figure 1D & E).

After six months of multiple outpatient consultations and two hospital admissions, the patient was diagnosed of American tegumentary leishmaniasis and treated with intravenous liposomal amphotericin B (4 mg/kg/day) for five days; followed by two other weekly doses of liposomal amphotericin B (4 mg/kg/dose). Thirty days after the end of treatment, a remarkable clinical improvement of the nasal lesion was observed (Supplementary Figure 1B).

3. Discussion

In American tegumentary leishmaniasis, manifestations often occur in the nasal mucosa, leading to septal destruction[4]. These cases are frequently underdiagnosed in non-endemic areas as the patient’s residence, Mendoza, Argentina, due to limited expertise in tropical parasites[5]. Nasal lesions are commonly misidentified as other conditions such as deep mycoses, squamous cell carcinoma, tuberculosis, lupus erythematosus, or myiasis[6].

ATL is endemic in nine provinces of northern Argentina (located between 22°21'S, 64°39'W and 28°22'S, 65°21'W)[7]. Mendoza City, positioned over 800 km away, is the capital of Mendoza Province (32°53' S, 68°49' W), where the disease has not been reported[5]. In Mendoza, ATL is an exotic infection, and previous cases struggled with accurate diagnosis within the provincial health system[8]. However, this ATL case, initially masquerading as myiasis and granulomatous vasculitis, was efficiently diagnosed by academic-scientific staff and the provincial health system.

In Argentina, leishmaniasis is underdiagnosed, despite being a mandatory notifiable disease to public health authorities[9]. Notification is done through the Argentine Integrated Health Information System, which standardizes reporting across all hospitals. This case report underscores the need for increased clinical awareness and adherence to national guidelines regarding the diagnosis and management of leishmaniasis. Specifically, it highlights the importance of early recognition and reporting, which can enhance timely medical intervention. Integrating this case into Clinical Practice Guidelines could improve diagnostic accuracy in regions where the disease is not prevalent and promote standardized treatment approaches. By ensuring each diagnosed case is accompanied by appropriate documentation and notification, healthcare providers can contribute to more effective disease surveillance and better patient outcomes. Moreover, the availability of no-cost therapeutic regimens reinforces the need to strengthen Clinical Practice Guidelines adherence, ensuring that patients receive proper care regardless of financial barriers[10,11].

The rationale for this study is to emphasize the importance of strengthening diagnostic capabilities for parasitic infections, particularly in non-endemic regions like Mendoza. This case highlights the need for technological collaboration between the scientific-academic and healthcare sectors to ensure accurate diagnosis of parasitoses that might otherwise be missed. Additionally, the study aims to address the critical gap in healthcare practitioners' knowledge about diagnosing and managing both endemic and non-endemic parasitic infections. Given the increasing global spread of these infections due to migration, ongoing education and awareness are essential for improving diagnostic accuracy and patient outcomes in areas beyond traditional endemic zones.

Conflict of interest statement

The authors declare that they have no conflict of interest.

Ethical approval and patient’s consent

The Research Ethics Committee of Hospital Luis Lagomaggiore has granted ethical approval for the publication of this case report

(protocol number: 007-05-03-2024). Informed consent was obtained from the patient for the publication of this case report and any accompanying images.

Acknowledgements

The authors are grateful to the contribution of Dra. Carolina Innocenti for histopathological analyses and Lic. Elisa Pietrobon for her technical work.

Funding

This study was supported by the Consejo Nacional de Investigaciones Cientıfícas y Técnicas (CONICET) (PIP 2021-2023 /11220200102779CO).

Authors' contributuons

All authors participated in the design, data analysis, manuscript preparation, editing, and review of this article. VJA, LMT, ESL, and DEC contributed to defining the intellectual content. VJA and DEC contributed to the literature research. GM and LMT contributed to the clinical studies and data acquisition. DEC served as the guarantor for this research.

References

[1] Sikorska K, Gesing M, Olszański R, Roszko-Wysokińska A, Szostakowska B, Damme-Ostapowicz KV. Misdiagnosis and inappropriate treatment of cutaneous leishmaniasis: A case report. *Trop Dis Travel Med Vaccines* 2022; **8**(1): 18.

[2] Thakur S, Joshi J, Kaur S. Leishmaniasis diagnosis: An update on the use of parasitological, immunological and molecular methods. *J Parasit Dis* 2020; **44**(2): 253-272.

[3] Pavlidakey PG, Huynh T, McKay KM, Sami N. Leishmaniasis panamensis masquerading as myiasis and sporotrichosis: A clinical pitfall. *Case Rep Pathol* 2015; **2015**: 949670.

[4] García Bustos MF, González-Prieto G, Ramos F, Mora MC, Hashiguchi Y, Parodi C, et al. Clinical and epidemiological features of leishmaniasis in northwestern-Argentina through a retrospective analysis of recent cases. *Acta Trop* 2016; **154**: 125-132.

[5] Cargnelutti DE, Borremans CG, Tonelli RL, Carrizo LC, Salomón MC. Diagnosis of *Leishmania* infection in a nonendemic area of South America. *J Microbiol Immunol Infect* 2016; **49**(5): 809-812.

[6] Pavlidakey PG, Huynh T, McKay KM, Sami N. Leishmaniasis panamensis masquerading as myiasis and sporotrichosis: A clinical pitfall. *Case Rep Pathol* 2015; **2015**: 949670.

[7] Salomon OD, Bogado De Pascual M, Molinari ML, Verri V. Study of a cutaneous leishmaniasis outbreak in General Vedia, Province of Chaco, 1996. *Rev Inst Med Trop Sao Paulo* 2001; **43**: 99-104.

[8] Martín-Sánchez J, Navarro-Mari JM, Pasquau-Liaño J, Salomón OD, Morillas-Márquez F. Visceral leishmaniasis caused by *Leishmania infantum* in a Spanish patient in Argentina: What is the origin of the infection? Case report. *BMC Infect Dis* 2004; **4**: 20.

[9] Yadón ZE, Quigley MA, Davies CR, Rodrigues LC, Segura EL. Assessment of leishmaniasis notification system in Santiago del Estero, Argentina, 1990-1993. *Am J Trop Med Hyg* 2001; **65**(1): 27-30.

[10] Montoya NR, Pulgarín JQ, Carvajal LL. Therapeutic response and safety of different treatments for cutaneous leishmaniasis in patients: A retrospective cross-sectional study. *Asian Pac J Trop Med* 2023; **16**(7): 305-312.

[11] Oryan A, Bemani E, Bahrami S. Anti-leishmanial, immunomodulatory and anti-oxidative activity of quercetin against cutaneous leishmaniasis caused by *Leishmania major*. *Asian Pac J Trop Biomed* 2023; **13**(1): 26-34.

Publisher's note

The Publisher of the *Journal* remains neutral with regard to jurisdictional claims in published maps and institutional affiliations.

Edited by Pan Y, Lei Y, Zhang Q

A



B



Supplementary Figure 1. Granulomatous mucosa with erythema, scaling, and

thickening of the nose skin, accompanied by erosion of the nasal septum and columella, and compromise of the nasal architecture (A). Post-treatment examination reveals the resolution of skin alterations, with the nasal and facial skin appearing healthier. However, the absence of the nasal septum and evident deformities in the nasal architecture persist (B).