[DOI]10.12016/j.issn.2096-1456.202550607

·防治实践·

腮腺嗜酸细胞型黏液表皮样癌2例临床病理报告及文献回顾

郑放，聂孟冬，强金彪，金荣豪，王丹丹，史册
吉林大学口腔医院口腔病理科 吉林省牙发育及颌骨重塑与再生重点实验室，吉林 长春（130021）

【摘要】 目的 探讨腮腺嗜酸细胞型黏液表皮样癌（OMEC）的临床病理特征及诊疗方案，以提高临床及病理医师对该罕见变异型黏液表皮样癌的认识。**方法** 回顾性分析2例发生于腮腺的OMEC患者的临床资料、影像学表现、组织病理学形态、免疫表型与分子特征，并复习相关文献。**结果** 病例1，男，50岁，因右耳垂后无痛性肿物2年余就诊。行保留面神经的右腮腺扩大切除术。病理示肿瘤以嗜酸细胞为主，含少量黏液细胞；免疫组化示细胞角蛋白5/6、细胞角蛋白7、P63部分阳性；阿利新蓝、过碘酸Schiff及磷钨酸苏木素特殊染色阳性，确诊为右腮腺OMEC，随访1年未见复发转移。病例2，男，61岁，因左耳下肿物3个月就诊。外院行腮腺部分切除术后于吉林大学口腔医院病理会诊，示肿瘤细胞嗜酸细胞占比近100%，呈浸润性生长，且缺乏典型的黏液细胞、表皮样细胞及中间细胞。经荧光原位杂交检测证实 mastermind 样转录共激活因子2（MAML2）基因断裂阳性，确诊为左腮腺OMEC。后续行保留面神经的腮腺全切除术，短期随访3个月无复发。文献回顾显示，OMEC多发生于腮腺，属低级别肿瘤，预后总体良好。当肿瘤完全由嗜酸细胞组成、缺乏黏液表皮样癌典型细胞特征且异型性低时，极易与嗜酸性腺瘤、结节性嗜酸细胞增生等良性嗜酸性病变混淆。其鉴别诊断依赖于浸润性生长的形态学特征、阳性免疫表型（如P63）以及特征性的MAML2基因重排检测。治疗首选根治性手术切除。**结论** 以嗜酸细胞为主的OMEC具有较高的临床误诊风险。结合病理形态学浸润特征、免疫组化及MAML2分子检测，是避免误诊、准确判断肿瘤性质并指导后续手术决策的关键。

【关键词】 唾液腺肿瘤；　黏液表皮样癌；　嗜酸细胞型；　免疫组织化学；　分子诊断；　基因重排；　mastermind样转录共激活因子2

【中图分类号】 R78　**【文献标志码】** A　**【文章编号】** 2096-1456（2026）06-0576-09

微信公众号

【引用著录格式】 郑放，聂孟冬，强金彪，等. 腮腺嗜酸细胞型黏液表皮样癌2例临床病理报告及文献回顾[J]. 口腔疾病防治, 2026, 34(6): 576-584. doi:10.12016/j.issn.2096-1456.202550607.

Oncocytic mucoepidermoid carcinoma of the parotid gland: a clinicopathological report of two cases and literature review

ZHENG Fang, NIE Mengdong, QIANG Jinbiao, JIN Ronghao, WANG Dandan, SHI Ce. Department of Oral Pathology, Hospital of Stomatology, Jilin University & Jilin Provincial Key Laboratory of Tooth Development and Bone Remodeling, Changchun 130021, China
Corresponding author: SHI Ce, Email: ceshi@jlu.edu.cn; WANG Dandan, Email: kqwdd@jlu.edu.cn

【Abstract】 Objective To investigate the clinicopathological characteristics and diagnostic - therapeutic strategies of oncocytic mucoepidermoid carcinoma (OMEC) of the parotid gland, and to enhance awareness of this rare variant among clinicians and pathologists. **Methods** The clinical data, imaging findings, histopathological features, immunophenotype, and molecular characteristics of two patients with parotid OMEC were retrospectively analyzed, and the relevant literature was reviewed. **Results** Case 1 was a 50-year-old man who presented with a painless mass behind the right earlobe for more than 2 years. The patient underwent extended parotidectomy with preservation of the facial nerve. Histopathological examination revealed that the tumor was predominantly composed of oncocytic cells with a small pro-

【收稿日期】 2025-12-29；　**【修回日期】** 2026-03-03
【基金项目】 吉林省财政厅科技项目（JCSZ2021893-36）
【作者简介】 郑放，住院医师，硕士研究生，Email：zhengfang24@mails.jlu.edu.cn
【通信作者】 史册，主任医师，博士，Email：ceshi@jlu.edu.cn；王丹丹，主治医师，博士，Email：kqwdd@jlu.edu.cn

portion of mucous cells. Immunohistochemically, the tumor cells were partially positive for cytokeratin 5/6, cytokeratin 7, and P63. Special staining with alcian blue, periodic acid-Schiff, and phosphotungstic acid hematoxylin yielded positive results. The diagnosis of right parotid OMEC was established. No recurrence or metastasis was observed during a 1 year follow-up. Case 2 was a 61-year-old man with a 3-month history of a mass beneath the left ear. After partial parotidectomy at an outside institution, pathological consultation at the Stomatological Hospital of Jilin University demonstrated that the tumor consisted almost entirely of oncocytic cells, exhibited infiltrative growth, and lacked typical mucous, epidermoid, and intermediate cells. Fluorescence in situ hybridization confirmed positive mastermind-like transcriptional activator 2 (MAML2) gene rearrangement, establishing the diagnosis of left parotid OMEC. The patient subsequently underwent total parotidectomy with preservation of the facial nerve, and no recurrence was detected during a short-term 3 months follow-up. A review of the literature indicated that OMEC most commonly arises in the parotid gland and is generally a low-grade malignancy with favorable prognosis. When tumors are composed exclusively of oncocytic cells, exhibit minimal cytological atypia, and lack the classical cellular components of mucoepidermoid carcinoma, they are highly prone to misdiagnosis as oncocytoma, nodular oncocytic hyperplasia, or other benign oncocytic lesions. Accurate differential diagnosis relies on recognition of infiltrative growth patterns, supportive immunophenotypic markers (e.g., P63 positivity), and detection of characteristic MAML2 gene rearrangement. Complete surgical excision remains the treatment of choice. **Conclusion**　OMEC dominated by oncocytic cells carries a high risk of clinical misdiagnosis. Integrating the assessment of infiltrative histopathological features with immunohistochemistry and molecular detection of MAML2 rearrangement is crucial for accurate diagnosis, appropriate assessment of tumor behavior, and optimal surgical decision making.

【Key words】 salivary gland neoplasms;　mucoepidermoid carcinoma;　oncocytic variant;　immunohistochemistry;　molecular diagnosis;　gene rearrangement;　mastermind-like transcriptional activator 2 gene

J Prev Treat Stomatol Dis, 2026, 34(6): 576-584.

【Competing interests】 The authors declare no competing interests.

This study was supported by the grants from the Jilin Province Department of Finance (No. JCSZ2021893-36).

黏液表皮样癌（mucoepidermoid carcinoma，MEC）是唾液腺最常见的恶性肿瘤之一，多发生于腮腺，约占所有唾液腺肿瘤的5%，约占唾液腺恶性肿瘤的20%[1]。嗜酸细胞型黏液表皮样癌（oncocytic mucoepidermoid carcinoma，OMEC）是黏液表皮样癌的一种罕见变异型，其病理学上核心特征为肿瘤细胞以嗜酸细胞为主导[2]，目前仅见少数病例报道[3]。当MEC的经典特征（表皮样细胞、中间细胞和黏液细胞）缺失时，OMEC易与其他含有嗜酸细胞的唾液腺肿瘤混淆[4]，因此，对OMEC的正确诊断对于指导患者的治疗与预后具有重要的意义。本文报道2例经病理诊断为OMEC的临床病例，旨在提高病理医师和临床医师对OMEC的认识，为其诊断与治疗提供参考。

1　病例资料

本研究获患者知情同意，并签署书面知情同意书。

1.1　病例1

1.1.1　临床资料　患者，男，50岁，因“右侧耳垂下肿物2年余”，于2024年10月15日收入吉林大学口腔医院治疗。患者2年前发现右耳垂后肿物，缓慢增大，现约3.0 cm×2.0 cm大小，无明显不适。2024年10月10日于外院行腮腺颈部超声检查提示：右侧腮腺内低回声。既往体健，否认家族肿瘤史，无吸烟、饮酒史。

1.1.2　专科检查　患者颜面部轻度不对称，右耳垂后下方可见类圆形肿物，大小约为3.0 cm×2.0 cm，边界清晰，质地较硬，活动度欠佳，无明显触压痛，表面皮肤色泽、温度正常。双侧眼睑闭合良好，双侧鼻唇沟无变浅，双侧额纹无变浅，鼓气时双侧无漏气。双侧腮腺、下颌下腺及舌下腺导管开口未见红肿，分泌液清亮。颏部及双侧耳后、颌下及颈部未触及肿大淋巴结。

1.1.3　辅助检查　2024年10月15日吉林大学口腔医院螺旋CT报告示：考虑右腮腺占位性病变，请结合临床（图1）。

1.1.4　诊断　入院诊断：右腮腺区肿物。

1.1.5　治疗　患者于2024年10月17日在全身麻醉下行保留面神经的右腮腺扩大切除术。手术过



Spiral CT revealed a soft-tissue mass in the right parotid gland with poorly defined boundaries and irregular margins, measuring approximately 2.9 cm×2.0 cm×2.0 cm (the red arrow indicates the space-occupying lesion in the right parotid gland). OMEC: oncocytic mucoepidermoid carcinoma; CT: computed tomography

Figure 1　Spiral CT image of a 50-year-old male patient with a right parotid gland mass before operation

图1　50岁男性右腮腺肿物患者术前螺旋CT图像

程：沿耳前经耳垂至耳后设计切口，切开皮肤、皮下组织及腮腺咬肌筋膜，显露肿物。术中见肿物位于腮腺浅叶，肿物呈不规则结节状，边界不清，无包膜，质地较韧。小心游离保护面神经分支，沿肿物外0.5 cm扩大切除部分腮腺组织。术中快速冰冻病理报告：（右腮腺）唾液腺来源恶性上皮性肿瘤，切缘未见肿瘤细胞。电刀电凝腮腺切缘，预防涎瘘。修整创缘，止血、彻底冲洗，严密缝合腮腺被膜，分层缝合肌肉、皮下组织，皮肤美容缝合。

1.1.6　术后病理检查　大体检查：送检肿物及周围腺体组织大小约3.8 cm×3.0 cm×2.0 cm（图2a），剖面红黑色，质韧（图2b）。

组织学检查：肿瘤位于腺体组织内，与腺体组织界限不清，中央可见大面积坏死区。肿瘤细胞呈嗜酸细胞样，可见黏液细胞。细胞异型性不明显，未见核分裂象、神经侵犯及血管淋巴管侵犯（图2c、2d）。

免疫组织化学检查：肿瘤细胞部分表达细胞角蛋白5/6（cytokeratin 5/6，CK5/6）、细胞角蛋白7（cytokeratin 7，CK7）和P63（图2e~2g）。

特殊染色：阿利新蓝（alcian blue，AB）染色、过碘酸Schiff（periodic acid-Schiff，PAS）染色显示少量黏液细胞及管腔内黏液，肿瘤细胞磷钨酸苏木素（phosphotungstic acid hematoxylin，PTAH）染色阳性，提示嗜酸细胞化生（图2h~2j）。病理诊断：（右腮腺区）嗜酸细胞型黏液表皮样癌（低级别）。临床分期：T2N0M0。

1.1.7　随访　术后定期随访。2025年2月28日复查：患者一般情况良好，术区创口愈合良好，面神经功能正常。超声检查提示：右侧腮腺术后改变，双侧颌下可见9枚淋巴结回声，双侧颈部及颏下未见明确异常淋巴结（图3）。2025年10月17日电话随访：患者自述一般状态良好，面神经功能正常，无复发与转移情况。

1.2　*病例2*

1.2.1　临床资料　患者，男，61岁，因“左侧腮腺部分切除术后5 d”于2025年10月21日入院治疗。患者3个月前发现左耳下肿物，大小约1.5 cm×1.0 cm×1.0 cm，近2个月明显增大至3.8 cm×1.8 cm×2.5 cm，无明显不适。2025年10月7日外院超声检查：左侧腮腺区类圆形低回声影，大小约3.8 cm×1.8 cm×2.5 cm，提示左腮腺区肿物。2025年10月16日于外院行左侧腮腺部分切除术。2025年10月20日外院病理诊断：（左侧腮腺区）嗜酸细胞肿瘤，瘤细胞呈浸润生长，未见确切包膜，倾向涎腺嗜酸细胞癌，建议进一步会诊。患者既往体健，无肿瘤家族史。吸烟史约40年，平均20支/d；饮酒史约40年，平均250 mL/d。

1.2.2　专科检查　患者颜面部不对称，左侧面部肿胀轻微，左侧腮腺后下极见一纵形切口，长约4 cm，缝线在位无松脱。双侧眼睑闭合良好，双侧鼻唇沟无变浅，双侧额纹无变浅，鼓气时双侧无漏气。双侧颞下颌关节运动不对称，无疼痛，双侧颞下颌关节开闭口弹响，无张口受限，开口度约三指，开闭口绞索。双侧腮腺、下颌下腺及舌下腺导管开口未见红肿，分泌液清亮。颏部及双侧耳后、颌下及颈部未触及肿大淋巴结。

1.2.3　病理会诊　患者将外院手术切除的组织切片送至吉林大学口腔医院口腔病理科会诊，结果如下：肿瘤呈实性，无包膜，由体积较大的嗜酸性细胞组成，胞浆丰富，部分细胞核偏位，排列成巢团状，浸润性生长。细胞异型性不明显，未见核分裂象、坏死、神经侵犯及血管淋巴管侵犯。可见细胞外黏液，但周围无明显黏液细胞，也无明显表皮样细胞和中间细胞，嗜酸细胞占比近100%。间质纤维结缔组织增生，伴淋巴细胞、浆细胞浸润，可见出血，部分区域间质硬化（图4a~4c）。免疫组织

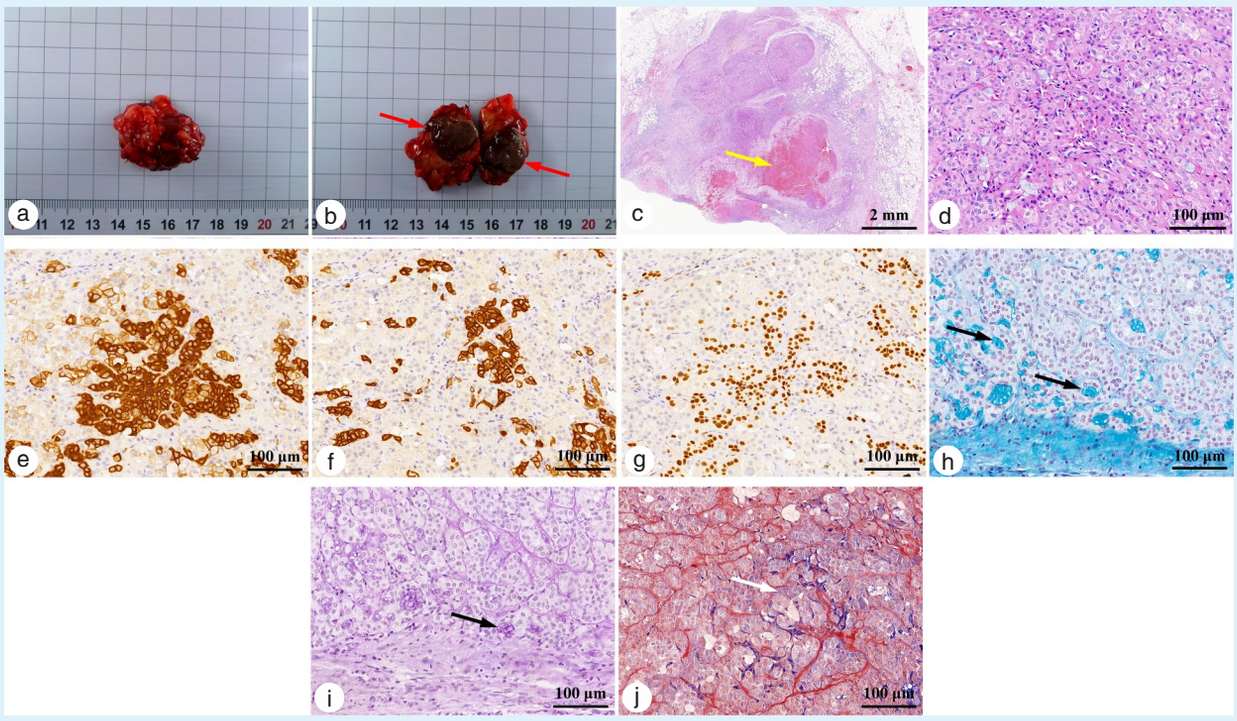

a: the submitted specimen measured 3.8 cm×3.0 cm×2.0 cm; b: the cut surface of the tumor appeared red-black and firm (the red arrows indicate the cut surface of the tumor); c: the tumor showed an ill-defined interface with the surrounding glandular tissue, with extensive central necrosis (the yellow arrow indicates the necrotic area of the tumor); d: tumor cells exhibited oncocytic features with abundant eosinophilic cytoplasm and no obvious cytological atypia; e: partial tumor cells were positive for CK5/6; f: partial tumor cells were positive for CK7; g: scattered tumor cells were positive for P63; h: AB staining demonstrated a small number of mucous cells (the black arrows indicate AB-positive mucous cells); i: PAS staining revealed a small number of mucous cells (the black arrow indicates PAS-positive mucous cells); j: tumor cells showed positive staining for PTAH (the white arrow indicates PTAH-positive cells). CK5/6: cytokeratin 5/6; CK7: cytokeratin 7; AB: alcian blue; PAS: periodic acid-Schiff; PTAH: phosphotungstic acid hematoxylin; OMEC: oncocytic mucoepidermoid carcinoma

Figure 2　Pathological diagnosis of tumor tissue in a 50-year-old male patient with a right parotid gland mass after surgery as OMEC

图2　50岁男性右腮腺肿物患者手术后肿瘤组织病理诊断为OMEC

化学检查：Ki-67阳性率3%~5%（图4d），热点区阳性率为10%（图4e）。分子检测：采用荧光原位杂交（fluorescence in situ hybridization，FISH）检测显示，MAML2基因断裂比例为30%，大于阳性结果判读阈值15%，即MAML2基因断裂（+）（图4f）。

1.2.4　诊断　结合形态学特征、免疫表型及分子检测结果，最终诊断为：（左侧腮腺区）嗜酸细胞型黏液表皮样癌（低级别），临床分期为T2N0M0。

1.2.5　治疗　根据上述诊断，患者在全身麻醉下行保留面神经的左侧腮腺全切除术。于下颌升支与乳突之间打开腮腺被膜，小心剥离后表面可见面神经总干。小心分离面神经，摘除全部腮腺腺体，止血、彻底冲洗。置入生物膜后缝合，可吸收缝线分层缝合皮下组织、美容缝合皮肤。

1.2.6　术后病理检查　送检腺体组织2块，较大者大小约8.5 cm×5.5 cm×3.0 cm，剖面实性，红黄色，质韧，见可疑病灶（图5a、5b）；较小者大小约4.2 cm×4.2 cm×2.0 cm，未见可疑病灶（图5a）。较大组织中可见少量散在肿瘤细胞，位置深在，切缘阴性（图5c、5d）。病理诊断为：（左腮腺区）嗜酸细胞型黏液表皮样癌术后改变。

1.2.7　随访　术后3个月随访：患者一般状态良好，创口愈合良好，面神经功能正常，无复发情况。目前患者处于定期随访中。

2　讨　论

2.1　OMEC的临床特点

黏液表皮样癌是最常见的唾液腺恶性肿瘤之一[5-6]，OMEC是一种罕见且诊断难度较大的黏液表皮样癌变异型[2]。OMEC好发于腮腺，也可发生

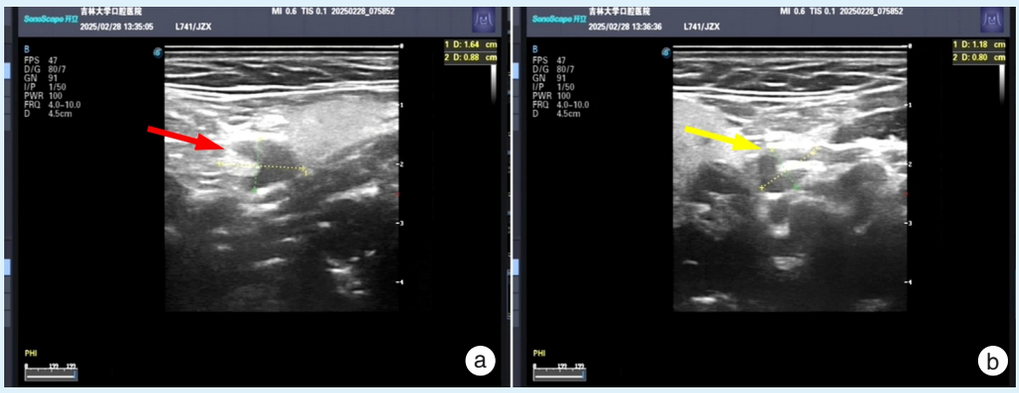

a: a relatively enlarged lymph node measuring 1.6 cm×0.9 cm was detected in the right submandibular region, with well-defined margins and preserved corticomedullary differentiation (the red arrow indicates the relatively enlarged lymph node in the right submandibular region); b: a relatively enlarged lymph node measuring 1.1 cm× 0.8 cm was detected in the left submandibular region, with well-defined margins and preserved corticomedullary differentiation (the yellow arrow indicates the relatively enlarged lymph node in the left submandibular region). OMEC: oncocytic mucoepidermoid carcinoma

Figure 3　Postoperative ultrasound results of a 50-year-old male patient with a right parotid gland mass (OMEC)

图3　50岁男性右腮腺肿物(OMEC)患者手术后复查超声结果

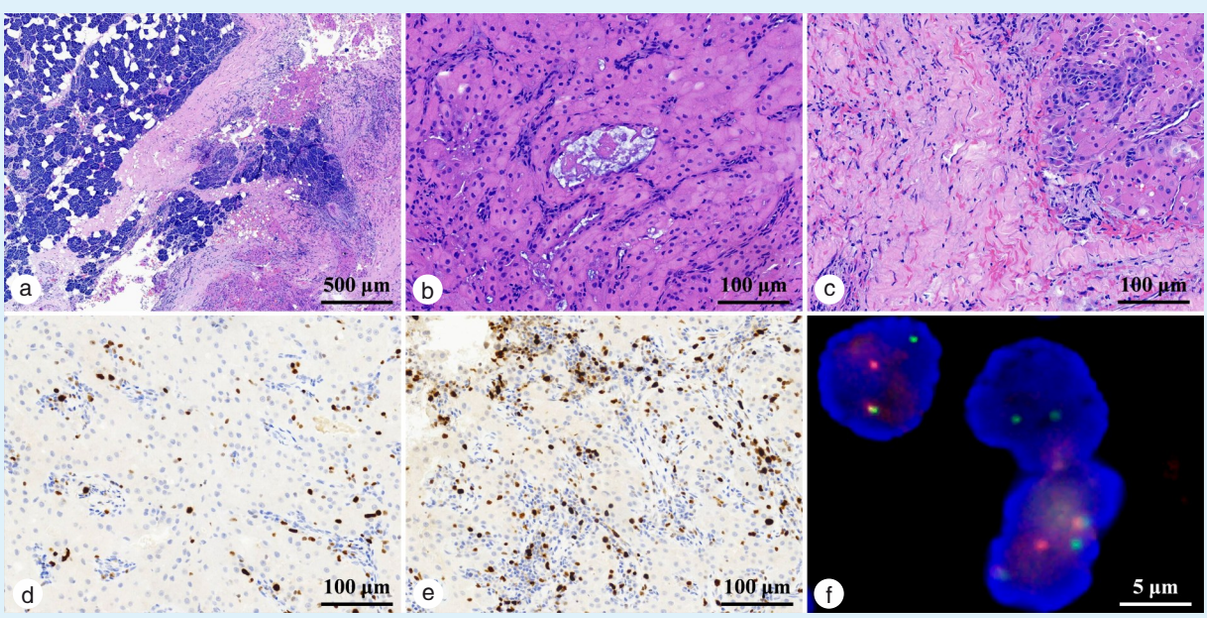

a: tumor cells infiltrate the adjacent glandular tissue; b: the tumor is composed of large oncocytic cells with abundant eosinophilic cytoplasm and tumor cells show no obvious cytological atypia. Extracellular mucin is present, while mucous cells are not identified; c: stromal fibrous connective tissue proliferation with infiltration of lymphocytes and plasma cells; hemorrhage is observed and focal stromal sclerosis is present; d: Ki-67 labeling index was 3% - 5%; e: Ki-67 labeling index in hotspot areas was approximately 10%; f: FISH analysis revealed positive MAML2 gene rearrangement, with split red and green signals observed in approximately 30% of the tumor cells, exceeding the established cutoff value of 15%. OMEC: oncocytic mucoepidermoid carcinoma; MAML2: mastermind-like transcriptional activator 2; FISH: fluorescence in situ hybridization

Figure 4　Pathological consultation of tumor tissue in a 61-year-old male patient with a left parotid gland mass after surgery in an external hospital, diagnosed as OMEC

图4　61岁男性左腮腺肿物患者在外院手术后的肿瘤组织病理会诊为OMEC

于舌下腺、小唾液腺、颈部等部位[7]，多数为低级别肿瘤，预后较好[8]，少数高级别或伴淋巴结转移者预后较差[9]。OMEC的发病年龄范围较广，多发生于成年人，但亦可见于青年患者[9-10]。现有病例

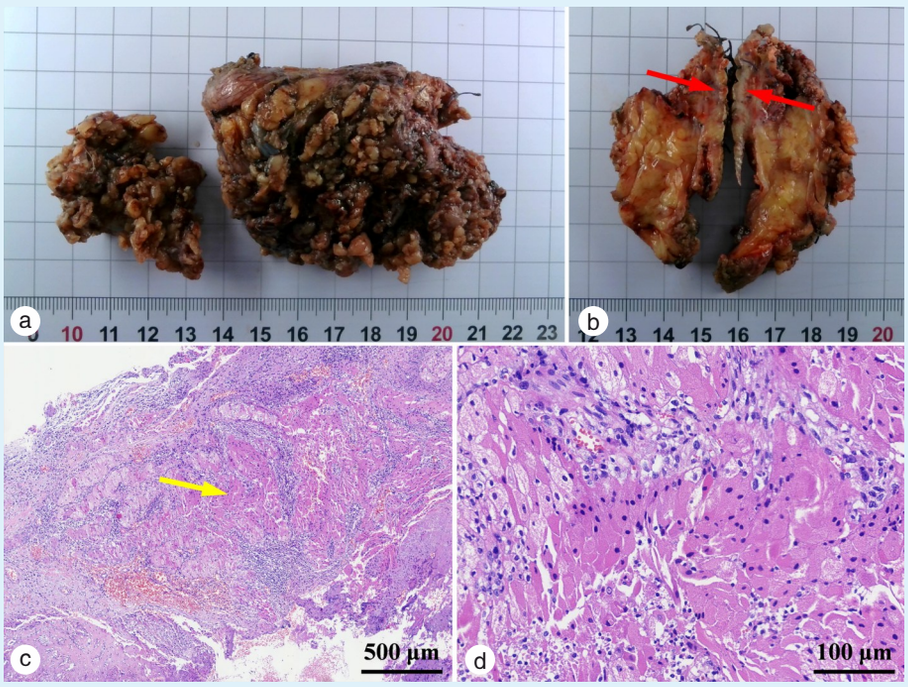

a: two pieces of glandular tissue were submitted. The larger specimen measured approximately 8.5 cm×5.5 cm×3.0 cm, and the smaller specimen measured approximately 4.2 cm×4.2 cm×2.0 cm; b: the cut surface of the larger specimen was solid, red-yellow, and firm (red arrows indicate suspicious lesions); c: a small number of tumor cells were observed in the submitted specimen, showing indistinct boundaries with the adjacent normal glandular tissue (the yellow arrow indicates tumor cells); d: tumor cells were slightly enlarged, with eosinophilic cytoplasm. OMEC: oncocytic mucoepidermoid carcinoma

Figure 5　Pathological diagnostic results of a 61-year-old male patient with a left parotid gland mass (OMEC) who underwent total resection of the left parotid gland during a second surgery

图5　61岁男性左腮腺肿物(OMEC)患者第二次手术行左腮腺全切术后病理诊断结果

研究表明,OMEC无明显性别偏好,男女发病比例大致相当[9-11]。临床上通常表现为生长缓慢的无痛性肿块,发生于腮腺者可出现面部肿胀与不对称[7, 9]。

2.2　OMEC的诊断与鉴别诊断

OMEC主要由嗜酸细胞组成,但目前尚未明确嗜酸细胞的百分比达到多少才能确诊OMEC[2]。当OMEC完全由嗜酸细胞组成或者嗜酸细胞比例高且缺乏黏液表皮样癌特征性的黏液细胞、表皮样细胞和中间细胞时,鉴别诊断具有一定的挑战性。

本文病例2中,肿瘤细胞中嗜酸细胞的占比近100%,但结合肿瘤细胞异型性不明显,未见核分裂象、坏死、神经侵犯及血管淋巴管侵犯、Ki-67增殖指数较低等病理学特点,可将该例诊断为低级别黏液表皮样癌。在大多数唾液腺的良性及恶性肿瘤中都存在嗜酸细胞化生,例如多形性腺瘤、肌上皮瘤、黏液表皮样癌、导管内癌等[12-14]。因此,OMEC需与以下唾液腺肿瘤的嗜酸细胞亚型进行鉴别[2, 7]。①嗜酸性腺瘤:为良性肿瘤,通常具有完整包膜,无浸润性生长行为[15-16];当OMEC缺乏典型细胞成分时,需借助MAML2基因重排检测进行鉴别。②结节性嗜酸细胞增生:嗜酸细胞结节状增生,缺乏黏液成分,无浸润性但通常无包膜[17-18],并可形成类似侵袭性透明细胞肿瘤的小卫星灶[19];与OMEC鉴别时通常也需要检测MAML2基因的重排。③嗜酸细胞型腺泡细胞癌:肿瘤细胞常呈腺泡样,排列成实性、微囊等结构,其内可见微嗜碱性酶原颗粒,PAS染色阳性[20],免疫组化通常DOG1和SOX10阳性[21-22]。④含有嗜酸细胞的转移性肿瘤:唾液腺之外的其他部位来源的转移性肿瘤也可能会表现出以嗜酸细胞为主的特征,如转移性肾透明细胞癌颗粒细胞亚型[23-24]、转移性甲状腺嗜酸细胞癌[25-26]、伴嗜酸细胞改变的转移性肺腺癌[27-28]等,需要病理医师结合病史与可疑原发灶的影像学检查进行鉴别诊断。除此之外,

OMEC通常具有黏液表皮样癌的P63阳性特点，而其他部位转移至唾液腺的肿瘤P63免疫组化通常阴性[29-30]。⑤嗜酸性腺癌：依据最新版WHO对于头颈部肿瘤的分类，已不再将嗜酸性腺癌作为独立的唾液腺恶性肿瘤类型。其主要原因在于，嗜酸性腺癌并非一个具有独特生物学行为、特异性分子改变或稳定临床特征的独立实体，而是多种唾液腺恶性肿瘤的形态学表型或分化方式[31]。既往文献中被归类为嗜酸性腺癌的病例，在重新评估后往往可被重新分类为具有嗜酸细胞化生的其他已知唾液腺恶性肿瘤类型，如黏液表皮样癌、腺泡细胞癌、导管癌或肌上皮癌等[32-33]。

本文两例病例凸显了OMEC的误诊风险。由于肿瘤细胞缺乏明显的异型性和核分裂象，其形态极易误判为良性病变，尤其在以嗜酸细胞为主的OMEC中更为突出。然而，浸润性生长模式（如病例2）是识别其恶性生物学行为的关键线索，但在初步评估中易被忽视。嗜酸细胞化生并非良性肿瘤所特有，多种唾液腺恶性肿瘤均可呈现以嗜酸细胞为主的形态特征。黏液表皮样癌的嗜酸细胞型常表现为黏液细胞稀少，肿瘤可呈实性或腺样排列，在形态上高度类似嗜酸细胞瘤、Warthin瘤等良性病变，在活检组织有限或术中冰冻切片中误诊风险显著增加。

因此，对于以嗜酸细胞为主且具有浸润性生长特征的唾液腺病变，单纯依赖常规形态学评估可能不足，需借助免疫组化和分子检测明确诊断。病例1通过AB染色标记黏液细胞，CK5/6、P63阳性提示嗜酸细胞可能由表皮样细胞与中间细胞化生而来；病例2通过MAML2基因重排检测最终确诊，为指导后续治疗提供了关键依据。病理医师在评估嗜酸细胞性唾液腺肿瘤时，应警惕低异型性并不等同于良性的诊断误区，将形态学特征、免疫表型与分子检测相结合，是避免误诊、指导手术范围及治疗决策的关键。

2.3　OMEC的治疗与预后

OMEC是黏液表皮样癌的一种罕见组织学变异型，目前尚缺乏大样本系统研究，其治疗策略仍不明确。鉴于OMEC在组织发生、分子改变及临床行为上与经典黏液表皮样癌具有高度相似性，现阶段临床治疗多沿用黏液表皮样癌的治疗原则，以根治性手术切除为主，并确保切缘阴性，手术切除范围和是否需要颈淋巴结清扫主要取决于肿瘤分级、大小和淋巴结转移情况[34-35]。其中彻底切除并获得阴性切缘是降低局部复发率、改善预后的关键因素[34-35]。而当存在神经浸润、淋巴结转移、切缘阳性、腺体外扩展等危险因素或为晚期高级别肿瘤时，术后辅助放疗可显著提高局部控制率和无病生存率[36-37]。系统化疗主要用于晚期、复发或转移性病例的姑息治疗，疗效有限[38]。近年来，随着分子生物学研究的深入，基于分子靶点的个体化治疗策略逐渐受到关注，但其临床价值仍有待进一步验证[34, 39]。

黏液表皮样癌的预后总体较好，但存在显著异质性，其临床结局主要取决于组织学分级和临床分期。其中组织学分级是影响预后的最重要独立预测因素。低级别黏液表皮样癌通常生物学行为温和，生长缓慢，侵袭性较低，而高级别黏液表皮样癌表现出明显的侵袭性，易发生局部复发和远处转移，预后不良[40-41]。此外，TNM分期、淋巴结转移、肿瘤大小及切缘状态亦是重要的预后影响因素[42]。

既往报道显示，多数OMEC为低级别肿瘤，根治性手术后预后良好[9]，但亦有少数病例出现局部复发或侵袭性表现[7]。基于此，本文病例1（肿瘤局限于腮腺浅叶）行腮腺扩大切除术，病例2（肿瘤位于深叶但未突破腺体）行腮腺全切除术，以降低复发风险。

【Author contributions】 Zheng F collected the case data and wrote the article. Nie MD, Qiang JB, Jin RH reviewed the article. Wang DD, Shi C conceptualized and reviewed the article. All authors read and approved the final manuscript as submitted.

参考文献

[1] Kim Y, Song JS, Choi SH, et al. Association between the histological subtypes, anatomical locations, and MAML2 rearrangement of head and neck mucoepidermoid carcinoma[J]. Head Neck Pathol, 2025, 19(1): 43. doi: 10.1007/s12105-025-01750-w.

[2] Skálová A, Agaimy A, Stanowska O, et al. Molecular profiling of salivary oncocytic mucoepidermoid carcinomas helps to resolve differential diagnostic dilemma with low-grade oncocytic lesions [J]. Am J Surg Pathol, 2020, 44(12): 1612-1622. doi: 10.1097/PAS.0000000000001590.

[3] Bishop JA, Thompson LDR, Siegele B, et al. Mucoepidermoid carcinoma may be devoid of squamoid cells by immunohistochemistry: expanding the histologic and immunohistochemical spectrum of MAML2- rearranged salivary gland tumours[J]. Histopathology, 2023, 82(2): 305-313. doi: 10.1111/his.14817.

[4] Wolk RA, Cipriani NA. Update of newly-recognized salivary gland neoplasms: molecular and immunohistochemical findings and clinical importance[J]. Histopathology, 2025, 86(2): 183-198. doi: 10.1111/his.15289.

[5] Peraza A, Gómez R, Beltran J, et al. Mucoepidermoid carcinoma. An update and review of the literature[J]. J Stomatol Oral Maxillofac Surg, 2020, 121(6): 713-720. doi: 10.1016/j.jormas.2020.06.003.

[6] 王张嵩, 谢舒乐, 张汉卿, 等. 2 456例唾液腺肿瘤临床病理分析[J]. 口腔疾病防治, 2020, 28(5): 298-302. doi: 10.12016/j.issn.2096-1456.2020.05.005.
Wang ZS, Xie SL, Zhang HQ, et al. Clinical and pathological analysis of 2 456 cases of salivary gland tumor[J]. J Prev Treat Stomatol Dis, 2020, 28(5): 298-302. doi: 10.12016/j.issn.2096-1456.2020.05.005.

[7] Weinreb I, Seethala RR, Perez-Ordoñez B, et al. Oncocytic mucoepidermoid carcinoma: clinicopathologic description in a series of 12 cases[J]. Am J Surg Pathol, 2009, 33(3): 409-416. doi: 10.1097/PAS.0b013e318184b36d.

[8] Jahan-Parwar B, Huberman RM, Donovan DT, et al. Oncocytic mucoepidermoid carcinoma of the salivary glands[J]. Am J Surg Pathol, 1999, 23(5): 523-529. doi: 10.1097/00000478-199905000-00005.

[9] Sarode GS, Sarode SC, Yuwanati M, et al. Predominantly oncocytic mucoepidermoid carcinoma of palate: a case report[J]. J Oral Maxillofac Pathol, 2024, 28(1): 134-137. doi: 10.4103/jomfp.jomfp_332_23.

[10] Argyris PP, Wakely PE Jr. Oncocytic mucoepidermoid carcinoma of the parotid gland[J]. Head Neck Pathol, 2025, 19(1): 30. doi: 10.1007/s12105-025-01768-0.

[11] Alshammari A, Aljufairi E, Alsayed A. Oncocytic mucoepidermoid carcinoma of the parotid gland: case report[J]. J Surg Case Rep, 2022, 2022(2): rjac039. doi: 10.1093/jscr/rjac039.

[12] Skalova A, Skálová A, Bradová M, et al. Oncocytic tumors in the salivary gland: a tri-focal review - integrated cytopathological, pathological, and molecular features[J]. Acta Cytol, 2025, 69(5): 441-452. doi: 10.1159/000544802.

[13] Kohno N, Ishida M, Odaka M, et al. Cytological features of oncocytic pleomorphic adenoma of the salivary gland: using the Milan classification system to report 3 patients[J]. Mol Clin Oncol, 2025, 22(3): 26. doi: 10.3892/mco.2025.2821.

[14] Choi JY, Park H, Moon SH. Pleomorphic adenoma with extensive oncocytic change in the parotid gland: a case report and review[J]. Gland Surg, 2025, 14(9): 1851-1857. doi: 10.21037/gs-2025-232.

[15] Alberto PL, Ashim S, Megan K, et al. Salivary gland oncocytomas. A systematic review[J]. Head Neck Pathol, 2024, 18(1): 126. doi: 10.1007/s12105-024-01730-6.

[16] Rivera RD, Nelson BL. Sine qua non: oncocytoma[J]. Head Neck Pathol, 2022, 16(4): 1167-1171. doi: 10.1007/s12105-022-01462-5.

[17] Cipriani NA, Kakkar A. Top 10 clear cell head and neck lesions to contemplate[J]. Head Neck Pathol, 2023, 17(1): 33-52. doi: 10.1007/s12105-022-01518-6.

[18] Rooper LM, Onenerk M, Siddiqui MT, et al. Nodular oncocytic hyperplasia: can cytomorphology allow for the preoperative diagnosis of a nonneoplastic salivary disease?[J]. Cancer Cytopathol, 2017, 125(8): 627-634. doi: 10.1002/cncy.21865.

[19] Hammami B, Thabet W, Kallel R, et al. Bilateral multifocal nodular oncocytic hyperplasia of the parotid gland: a rare entity[J]. Pathologica, 2021, 113(2): 131-135. doi: 10.32074/1591-951X-140.

[20] Kirschnick LB, Silveira FM, Schuch LF, et al. Clinicopathological analysis of oral and maxillofacial acinic cell carcinoma: a systematic review[J]. J Oral Pathol Med, 2021, 50(8): 741-749. doi: 10.1111/jop.13159.

[21] Fiorentino V, Straccia P, Tralongo P, et al. DOG1 as an immunohistochemical marker of acinic cell carcinoma: a systematic review and meta-analysis[J]. Int J Mol Sci, 2022, 23(17): 9711. doi: 10.3390/ijms23179711.

[22] Schmitt AC, Cohen C, Siddiqui MT. Expression of SOX10 in salivary gland oncocytic neoplasms: a review and a comparative analysis with other immunohistochemical markers[J]. Acta Cytol, 2015, 59(5): 384-390. doi: 10.1159/000441890.

[23] Capodiferro S, Limongelli L, Mastropasqua MG, et al. Metastatic tumors of the oro-facial tissues: clear cell renal cell carcinoma. A clinico-pathological and immunohistochemical study of seven cases[J]. J Clin Med, 2020, 9(4): 1151. doi: 10.3390/jcm9041151.

[24] Yoshida T, Ohe C, Ikeda J, et al. Eosinophilic features in clear cell renal cell carcinoma correlate with outcomes of immune checkpoint and angiogenesis blockade[J]. J Immunother Cancer, 2021, 9(9): e002922. doi: 10.1136/jitc-2021-002922.

[25] Vieira-Sebe N, Almeida-Parra F, Ranz-Colio Á, et al. Metastasis of oncocytic thyroid carcinoma in the mandibular condyle: an exceptional localization[J]. J Clin Exp Dent, 2025, 17(5): e614-e618. doi: 10.4317/jced.62635.

[26] Kure S, Ohashi R. Thyroid Hürthle cell carcinoma: clinical, pathological, and molecular features[J]. Cancers (Basel), 2020, 13(1): 26. doi: 10.3390/cancers13010026.

[27] Nishino M, Klepeis VE, Yeap BY, et al. Histologic and cytomorphologic features of ALK-rearranged lung adenocarcinomas[J]. Mod Pathol, 2012, 25(11): 1462-1472. doi: 10.1038/modpathol.2012.109.

[28] Sibille A, Corhay JL, Louis R, et al. Eosinophils and lung cancer: from bench to bedside[J]. Int J Mol Sci, 2022, 23(9): 5066. doi: 10.3390/ijms23095066.

[29] McHugh JB, Hoschar AP, Dvorakova M, et al. p63 immunohistochemistry differentiates salivary gland oncocytoma and oncocytic carcinoma from metastatic renal cell carcinoma[J]. Head Neck Pathol, 2007, 1(2): 123-131. doi: 10.1007/s12105-007-0031-4.

[30] Mashiana S, Duarte EM. Metastatic mucoepidermoid carcinoma to the pleura: a case report[J]. J Med Case Rep, 2022, 16(1): 69. doi: 10.1186/s13256-022-03285-y.

[31] Skálová A, Hyrcza MD, Leivo I. Update from the 5th edition of the world health organization classification of head and neck tumors: salivary glands[J]. Head Neck Pathol, 2022, 16(1): 40-53. doi: 10.1007/s12105-022-01420-1.

[32] Vial L, Descotes F, Lopez J, et al. Reappraisal of oncocytic adenocarcinoma: unveiling its connection to oncocytic variants of salivary duct carcinoma and mucoepidermoid carcinoma through immunohisto-molecular perspectives[J]. Am J Surg Pathol, 2025,

49(1): 73-82. doi: 10.1097/PAS.0000000000002324.

[33] Skalova A, Hyrcza MD. Proceedings of the North American society of head and neck pathology companion meeting, New Orleans, LA, march 12, 2023: classification of salivary gland tumors: remaining controversial issues?[J]. Head Neck Pathol, 2023, 17(2): 285-291. doi: 10.1007/s12105-023-01541-1.

[34] Sama S, Komiya T, Guddati AK. Advances in the treatment of mucoepidermoid carcinoma[J]. World J Oncol, 2022, 13(1): 1-7. doi: 10.14740/wjon1412.

[35] Chan SA, Van Abel KM, Lewis JE, et al. Mucoepidermoid carcinoma of the parotid gland: twenty-year experience in treatment and outcomes[J]. Head Neck, 2021, 43(9): 2663-2671. doi: 10.1002/hed.26735.

[36] Park G, Lee SW. Postoperative radiotherapy for mucoepidermoid carcinoma of the major salivary glands: long-term results of a single-institution experience[J]. Radiat Oncol J, 2018, 36(4): 317-324. doi: 10.3857/roj.2018.00409.

[37] Shirai K, Koto M, Demizu Y, et al. Multi-institutional retrospective study of mucoepidermoid carcinoma treated with carbon-ion radiotherapy[J]. Cancer Sci, 2017, 108(7): 1447-1451. doi: 10.1111/cas.13270.

[38] Pérez-de-Oliveira ME, Wagner VP, Bingle CD, et al. Disruption of oncogenic pathways in mucoepidermoid carcinoma: CREB inhibitor 666.15 as a potential therapeutic agent[J]. Oral Oncol, 2024, 159: 107029. doi: 10.1016/j.oraloncology.2024.107029.

[39] Bou Zerdan M, Kumar PA, Zaccarini D, et al. Molecular targets in salivary gland cancers: a comprehensive genomic analysis of 118 mucoepidermoid carcinoma tumors[J]. Biomedicines, 2023, 11(2): 519. doi: 10.3390/biomedicines11020519.

[40] Fehr A, Werenicz S, Trocchi P, et al. Mucoepidermoid carcinoma of the salivary glands revisited with special reference to histologic grading and CRTC1/3-MAML2 genotyping[J]. Virchows Arch, 2021, 479(5): 975-985. doi: 10.1007/s00428-021-03146-x.

[41] Liu S, Ow A, Ruan M, et al. Prognostic factors in primary salivary gland mucoepidermoid carcinoma: an analysis of 376 cases in an Eastern Chinese population[J]. Int J Oral Maxillofac Surg, 2014, 43(6): 667-673. doi: 10.1016/j.ijom.2014.01.008.

[42] Sun J, Sun Y, Yang F, et al. Nomogram to predict the prognosis of parotid gland mucoepidermoid carcinoma: a population-based study of 1306 cases[J]. PeerJ, 2019, 7: e7237. doi: 10.7717/peerj.7237.

（编辑　罗燕鸿，刘曙光）

Open Access
This article is licensed under a Creative Commons Attribution 4.0 International License.
Copyright © 2026 by Editorial Department of Journal of Prevention and Treatment for Stomatological Diseases

官网