

apjtm.org

Review Article

Asian Pacific Journal of Tropical Medicine

doi: 10.4103/apjtm.apjtm_323_25

# Human schistosomiasis: A living review of clinical and epidemiological concepts

Rodrigo Siqueira-Batista[1,2], Paulo Sérgio Balbino Miguel[3]✉, Andréia Patrícia Gomes[1], Graziela Almeida Cupertino[2], Teresa Baptista-Fernandes[4], Ademir Nunes Ribeiro Júnior[5], Sávio Silva Santos[6]

[1]*Departamento de Medicina e Enfermagem, Universidade Federal de Viçosa, Viçosa, Minas Gerais, Brazil*

[2]*Escola de Medicina da Faculdade Dinâmica do Vale do Piranga, Viçosa, Minas Gerais, Brazil*

[3]*Instituto Federal de Educação, Ciência e Tecnologia do Paraná, Barracão, Paraná, Brazil*

[4]*Laboratório de Microbiologia, Hospital Egas Moniz, Unidade de Saúde Local de Lisboa Ocidental, Lisboa, Portugal*

[5]*Departamento de Enfermagem, Universidade Evangélica de Goiás, Goiânia, Goiás, Brazil*

[6]*Curso de Medicina, Centro Universitário Serra dos Órgãos, Teresópolis, Rio de Janeiro, Brazil*

## ABSTRACT

Schistosomiasis, as a neglected tropical disease, presents a public health challenge, particularly in impoverished tropical and subtropical areas. This living review focuses on the key aspects of schistosomiasis, including its etiology, epidemiology, pathophysiology, clinical features, diagnosis, prophylaxis, treatment, and control. We also examine the key aspects of schistosomiasis caused by *Schistosoma mekongi*, *Schistosoma bovis*, and *Schistosoma curassoni*. To date, praziquantel is the main drug for treating and reducing the transmission of schistosomiasis. The development of vaccines remains an important scientific goal in the control of this neglected disease.

**KEYWORDS:** Schistosomiasis; *Schistosoma* infection; Katayama fever

## 1. Introduction

Schistosomiasis is a neglected tropical parasitic disease of global significance[1,2]. An estimated 250 million people are affected by this parasitosis to date, which is endemic to Africa, Southeast Asia, and Latin America, totaling around 78 countries, 51 of which have moderate to severe transmission, requiring preventive chemotherapy[3]. In sub-Saharan Africa, *Schistosoma (S.) mansoni* and *S. haematobium*, responsible for intestinal and urogenital schistosomiasis respectively, are the primary species impacting humans. There are significant outbreaks of *S. intercalatum* in East Africa, which is currently the only species found in São Tomé and Príncipe[4]. To date, in Brazil, the disease caused by *S. mansoni* affects approximately six million people[5]. Although eliminated in many regions of the world, schistosomiasis can still be identified in travelers, especially those from endemic areas who bathe in freshwater bodies where the parasite and its intermediate host are present[6,7]. In addition, *S. japonicum* is the etiological agent of intestinal schistosomiasis in Asian countries[8]. *S. guineensis* is endemic to West and Central Africa, and *S. mekongi* is restricted to the southern regions of Cambodia and along the Mekong River in the Lao People's Democratic Republic[9,10].

The World Health Organization has set targets for the control and elimination of this debilitating disease, aiming for "a world without schistosomiasis" by 2030[3]. To achieve these goals, it is essential to have a comprehensive and nuanced understanding of the disease's context and to enhance the understanding of the key aspects surrounding diseases caused by *Schistosoma*[1]. This paper provides an update on the etiology, epidemiology, physiopathology, as well as clinical, therapeutic, and prophylactic findings of this globally significant parasitosis.

✉To whom correspondence may be addressed. E-mail: paulo.miguel@ifpr.edu.br

This is an open access article distributed under the terms of the Creative Commons Attribution-Non-Commercial-No Derivatives License 4.0 (CCBY-NC-ND), where it is permissible to download and share the work provided it is properly cited. The work cannot be changed in any way or used commercially without permission from the journal.

**For reprints contact:** reprints@medknow.com

©2025 *Asian Pacific Journal of Tropical Medicine* Produced by Wolters Kluwer-Medknow.

**How to cite this article:** Siqueira-Batista R, Miguel PSB, Gomes AP, Cupertino GA, Baptista-Fernandes T, Júnior ANR, et al. Human schistosomiasis: A living review of clinical and epidemiological concepts. Asian Pac J Trop Med 2025; 18(12): 528-540.

**Article history:** Received 13 June 2025 Revision 13 December 2025
Accepted 18 December 2025 Available online 24 December 2025

## 2. Mansonic schistosomiasis

### 2.1. Epidemiology

*S. mansoni* life cycle is shown in Figure 1. It is reported in 78 countries, with 51 being endemic with moderate to high transmission. The disease mainly occurs in areas where communities lack access to clean water and sanitation. Among the endemic regions, Africa is particularly notable, especially to the east of the Mediterranean, encompassing the Nile Delta and countries such as Egypt and Sudan, as well as the Americas, primarily in the Caribbean, Venezuela, and Brazil. The highest number of schistosomiasis cases is estimated to be on the African continent[11]. In Brazil, 99% cases are concentrated in the Northeast and Southeast, with focal points in Rio Grande do Sul, Santa Catarina, Paraná, São Paulo, Goiás, the Federal District, Pará, Rio de Janeiro, and Piauí. Out of the country's 27 federative units, 19 have reported cases, the main endemic settings extend from the state of Minas Gerais to Rio Grande do Norte, especially in coastal areas. It is common for schistosomiasis mansoni to exhibit low lethality, with causes of death more closely associated with severe clinical forms of the disease[6].

### 2.2. Pathophysiology

Most symptoms of acute and chronic schistosomiasis result from the retention of pathogen eggs in the host, which cause microperforations in the intestine or bladder and granulomatous reactions around the eggs[12].

In the chronic phase of mansonic schistosomiasis, more severe lesions develop, which can significantly impact the patient's quality of life. In the case of chronic hepatic schistosomiasis, the highest incidence occurs in young adults and middle-aged individuals who are susceptible to this form of the disease. The severity of the condition is directly linked to the intensity of the infection. Fibrotic lesions develop, thickening the portal system and leading to pre-sinusoidal portal hypertension[13].

In the lung, *Schistosoma*-induced lesions show marked perivascular inflammatory infiltrates composed predominantly of CD4+ T cells, mast cells and dendritic cells within a type-2 (Th2-biased) immune milieu, which contributes to pulmonary vascular remodeling and hypertension[14,15]. There are no definitive explanations for the pulmonary vascular alterations. However, the portosystemic shunt is a pathogenic mechanism that is likely relevant to the development of pulmonary arterial hypertension associated with schistosomiasis, as it transports antigens to the lungs, which subsequently leads to granulomatous inflammation[16].

Changes in the muscle layers of the bladder and ureter wall, which trigger bladder motor dysfunction or disrupt the contractile mechanism of the vesical sphincter, have been linked to fibrosed and irregularly calcified schistosomal granulomas. The fibrotic process can result in scar contraction at critical sites, leading to obstructive manifestations and ascending infections. Although the renal system is an uncommon site for ectopic granuloma formation, radiologically visible lesions in the upper urinary system have been noted[13]. Glomerular injuries can occur due to the deposition of immune complexes. Furthermore, these rare cases of bladder infection caused by *S. mansoni* can be mistaken for cancer[17].

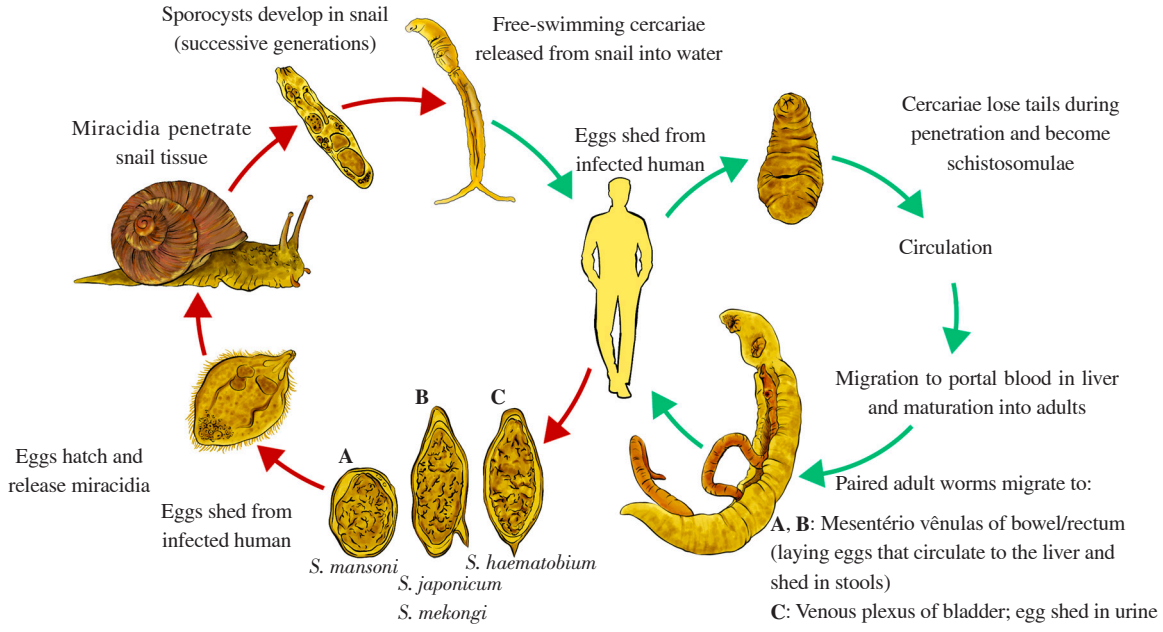


**Figure 1.** Life cycle of *Shistosoma*. Image from Ademir Nunes Ribeiro Júnior with permission. *S.-Shistosoma.*

## 2.3. Clinical aspects

### 2.3.1. Acute schistosomiasis mansoni

The typical presentation of acute/toxemic schistosomiasis is marked by erythematous papules and localized pruritus. These changes are initiated by the urticarial reaction that occurs following the penetration of cercariae. This condition is commonly observed in young adults who travel to endemic areas. In individuals residing in these regions, particularly during childhood, acute schistosomiasis mansoni often presents asymptomatically or with few symptoms. The signs and symptoms of this phase align with the evolutionary cycle of *S. mansoni*, which encompasses the penetration of the cercaria and the migration of the schistosome. Initially, the host's innate immune response is triggered, and over time, the Th1 adaptive immune response becomes predominant. Generally, the infectious presentation is milder; however, a massive infection can result in acute pulmonary or systemic conditions. There are documented cases of one manifestation of acute schistosomiasis, which may be preceded by four other recognized presentations[13].

Cercarial dermatitis ('swimmer's itch') is a transient, pruritic maculopapular rash at the site of cercarial penetration, reflecting a delayed hypersensitivity reaction[13,18,19].

Katayama syndrome manifests as an acute febrile systemic illness with respiratory and gastrointestinal symptoms, eosinophilia and hepatosplenomegaly[20,21]. Laboratory findings typically show eosinophilia and mild hepatic enzyme elevation[21].

Although most patients recover spontaneously within 2 to 10 weeks, some may develop a persistent and severe condition characterized by generalized skin rashes, toxemia, dyspnea, hepatosplenomegaly, diffuse abdominal pain, diarrhea, and weight loss. In some cases, it can abruptly progress to splenomegaly, portal hypertension, and liver fibrosis[13].

### 2.3.2. Chronic schistosomiasis mansoni

Chronic schistosomiasis commences after the acute phase, marked by a regression of symptoms; the majority of patients remain asymptomatic. The noticeable clinical manifestations reemerge as the disease progresses into its chronic stages, with reinfection leading to an increased parasite load[12]. The intestinal form is seldom found in isolation. It is typically associated with hepatic involvement (the most common clinical presentation of chronic schistosomiasis mansoni), which is primarily characterized by the combination of the intestinal form with hepatomegaly. The chronic phase of schistosomiasis results from a granulomatous inflammatory reaction in response to the presence of pathogen eggs, which are deposited in various tissues and organs. The release of antigenic glycoproteins facilitates the passage of eggs through blood vessels, which may remain in the capillaries of the intestinal mucosa or be transported to the liver by mesenteric circulation. The antigens released by the eggs induce the recruitment of host defense cells and the consequent organization of granuloma[22].

#### 2.3.2.1. Hepatosplenic form of schistosomiasis

The study of the hepatosplenic form of schistosomiasis (HSS) is extremely important due to its high prevalence in countries in Asia, Africa, and South America and because it is considered the most significant etiology of cirrhotic portal hypertension[23], also affecting the liver and spleen, may cause variceal bleeding, decompensation of liver disease, ascites. HSS is prevalent in patients with severe infections, especially between those aged 20 and 30 years. Progression to hepatosplenic disease is influenced by parasite burden, host genetics and co-morbidities such as viral hepatitis and malnutrition[6,23]. The initial course of the disease is relatively benign; however, there is a high probability that patients will develop decompensation at the end of the first decade of the disease, with reduced survival[24].

Necropsy records have pointed to a significant prevalence of pulmonary involvement by *S. mansoni*, even in asymptomatic individuals, with around 20% to 30% of cases[8]. This occurrence is believed to be associated with the hepatosplenic form, the explanation for which is based on portal hypertension, in which a portosystemic shunt would allow parasite eggs to enter the pulmonary circulation, resulting in granulomatous formations[15].

#### 2.3.2.2. Ectopic forms of schistosomiasis mansoni

The clinical manifestations of schistosomiasis mansoni mostly occur in the liver and intestine. However, ectopic forms may occasionally occur. This happens when adult *Schistosoma* migrate through the host's body and deposit their eggs in other organs of the host's body, suggesting that the disease may be systemic rather than localized[12]. In individuals in whom *S. mansoni* eggs reach the central nervous system, the inflammatory response triggered can lead to the development of neuroschistosomiasis. Signs and symptoms include increased intracranial pressure, myelopathy and radiculopathy; however, most of these can be asymptomatic. When left untreated, central nervous system lesions can develop into irreversible glial scars. Seizures and focal neurological deficits are the most common manifestations of these complications[25]. Although spinal cord schistosomiasis mansonic is underestimated, especially due to the lack of clinical recognition and difficulty in diagnosis, it has been increasingly recorded in individuals from endemic areas. It is rarely asymptomatic and its prevalence is higher in male patients, young adults, with the intestinal or hepatointestinal form of schistosomiasis mansoni. Spinal cord involvement is classified into three different clinical forms: myeloradiculopathy, cone-caudal and equine spinal syndrome (the most severe of

the three). In the latter, the spinal cord is almost completely compromised and generally has a poor prognosis. Patients present with low back pain, muscle weakness, sensory loss, radicular pain in the limbs and bladder dysfunction[26].

### 2.4. Laboratory diagnosis

The broad picture of schistosomiasis mansoni presents distinct manifestations, sometimes vague signs and symptoms, which is why laboratory tests are essential for diagnostic confirmation[6].

In endemic settings, diagnosis still relies largely on stool microscopy (*e.g.*, Kato-Katz and concentration techniques), despite suboptimal sensitivity in low-intensity infections (Figure 2)[6,27,28].

Rectal mucosal biopsy is reserved for specific cases, when chronic infection results in the formation of rectal lesions and/or granulomas. However, its use has declined in recent years[29].

Immunological methods, which generally show positive results from the 25th day of infection, are used for chronic forms of the disease. In Brazil, the Indirect Immunofluorescence test for IgM and the Enzyme-Linked Immunosorbent Assay (ELISA) are available through the Brazilian National Health System. In general, these tests are more commonly used in areas with a low prevalence of the disease, immunosuppressed patients or in individuals with a low parasite load. They have good sensitivity but are more expensive and not as practical in the clinical routine[6]. They are also useful in specific situations, such as in patients with Katayama syndrome (who do not excrete parasite eggs), regions that have achieved parasitological control (corroborating to determine if there has been a re-emergence or if control has in fact been effective) and travelers[8].

The search for *S. mansoni* antigens could be a promising technique, surpassing existing diagnostic methods. The search for antigens with labeled monoclonal antibodies and/or polyclonal antibodies can be carried out on samples such as sputum, serum and urine from infected patients. To date, some tests have been developed using immunoenzymatic techniques for antigens present in the intestine of adult *S. mansoni*, both male and female. The detection of circulating anodic antigen (CAA) and cathodic antigen (CCA) can be useful for evaluating treatment effectiveness, as their concentrations tend to decrease or disappear after therapeutic success. Serum CAA detection is a promising approach, but it is important to note that urine CCA detection, despite its broad availability, has limitations in reproducibility and specificity. Because of these limitations, urine CCA-based tests are not recommended for individual patient diagnosis or for cure monitoring, unless more robust accuracy studies are available[30]. The UCP-LF (Up-Converting Phosphor-




**Figure 2.** Eggs (A-B) and furocercaria (C) of *Schistosoma mansoni*. Parasitological examination of the feces revealed the structures above, measuring around (114-180) µm × (45-70) µm. Image from Teresa Baptista-Fernandes with permission.

Lateral Flow) platform, which uses up-converting luminescent particle technology, enables the simultaneous detection of CCA and CAA in infections caused by *S. mansoni* and *S. haematobium* with a higher positivity rate. This test is particularly promising in areas endemic for *S. haematobium*, given the limited performance of the Point-of-Care Circulating Cathodic Antigen (POC-CCA) test in urine. It is imperative; however, to conduct studies to determine whether quantitative detection of CAA and CCA can be used to identify the infecting species, evaluate its effectiveness in assessing mixed infections[31], and analyze the costs and potential for commercialization and application in public health programs in endemic areas, where resources are admittedly scarcer.

The polymerase chain reaction (PCR) test, is an assay with good sensitivity and specificity capable of identifying the helminth's nucleic acid in stool and blood samples[28]. However, in order to replace conventional tests, further research is needed into diagnostic accuracy and cost-effectiveness[32].

For cases of neuroschistosomiasis, the diagnostic method commonly used is cerebrospinal fluid analysis, by antibody titer analysis or PCR. Eventually, a biopsy of a brain lesion may be the choice, especially in situations where imaging diagnosis is inconclusive[33]. However, the risks of biopsy and possible complications associated with the central nervous system[34] suggest the search for other complementary methods, such as magnetic resonance spectroscopy[33]. Common findings are pleocytosis with eosinophylorrhea and elevated proteinorrhea[35].

### 2.5. Treatment

Schistosomiasis mansoni therapy is effective, with the use of low-toxicity drugs. For patients with the presence of eggs in the feces or rectal mucosa, the use of praziquantel (PZQ) or oxamniquine is recommended[6]. Preventive chemotherapy with PZQ is recommended in endemic regions where the prevalence of infection is greater than 10%, for individuals over two years of age and pregnant women (after the first trimester).

PZQ is a pyrazinoisoquinoline derivative and is safe and effective against all species of the *Schistosoma* genus. It is administered orally; it is well absorbed; it acts within an hour of ingestion; it is metabolized by the liver and excreted by the kidneys. Its mechanism of action on adult worms is not well understood[36]. Some studies claim that the worms separate from the vascular walls and die as a result of tetanic contractions and tegumentary vacuolization. Furthermore, it is believed that the effectiveness of the drug is determined by the presence of host antibodies[19]. The recommended dose of PZQ in adults is 60 mg/kg, divided into three doses of 20 mg/kg. In Brazil, the recommended dose for *S. mansoni*, *S. haematobium* and *S. intercalatum* is preferably a single dose of 50 mg/kg for adults and 60 mg/kg for children, aged between 4 and 15 years old. To achieve 95% to 100% efficacy, repeat treatment after four to six weeks. A second dose is advisable, especially if there is eosinophilia and a high antibody titer after the first treatment[6]. The most common adverse reactions to the drug are nausea, dizziness and rash. There may be pruritus, but its occurrence is more associated with the death of the parasite. The use of PZQ should be avoided in pregnant women during the first trimester of pregnancy and in children under 4 years of age. Breastfeeding should be discontinued (on the day of treatment and for the next 72 hours, when the drug is secreted by breast milk). Co-infected patients (schistosomiasis mansoni/cysticercosis) can develop irreversible eye damage, seizures and cerebral infarction. Drug resistance is being studied[37,38].

The development of pediatric formulations of PZQ is considered urgent by the WHO, particularly for pre-school children, since around 50 million of them still do not receive treatment through public health programs. In this context, arpraziquantel (levopraziquantel, the biologically active enantiomer of PZQ) has emerged as a promising alternative. It is more palatable and orally dispersible, and has already successfully completed phase Ⅰ, Ⅱ, and Ⅲ clinical trials. The results of the phase Ⅲ study in children aged 3 months to 6 years, infected with *S. mansoni*, are encouraging: cure rates exceeding 90% and egg reduction around 99% were achieved with a dose of 50 mg/kg[39]. In Brazil, the drug is also undergoing a phase Ⅲ clinical trial for children living in endemic areas, reinforcing efforts toward its global adoption[40]. Although arpraziquantel represents an important advance, its large-scale adoption in resource-limited settings requires follow-up approaches to assess its cost-effectiveness and scalability[41]. In order to overcome cost and distribution barriers, the low-cost nanoformulation of PZQ, using the self-nanoemulsified delivery system (SNEDDS-PZQ), has emerged as a strategy with the potential for widespread application. *In vivo* evaluation in animal models has shown promising results, with a single oral dose of 200 or 400 mg/kg resulting in a reduction of more than 95% in the parasite load[42]. Although these findings are encouraging, it is essential that the new formulation be evaluated in humans to confirm its safety and efficacy. Until the pediatric formulation becomes available, a recent study conducted in Uganda—an endemic region—proposes administering two doses of 40 mg/kg of crushed PZQ (one dose every three hours) as safe, well tolerated, and most effective in curing *S. mansoni* infection in children aged between one and four years living in endemic areas[43].

Artemisinin derivatives show activity against juvenile schistosomes and have been evaluated in combination with PZQ, but concerns about antimalarial resistance limit their widespread use[39].

### 2.6. Prophylaxis and control

Schistosomiasis mansoni control is carried out with a view to reducing the morbidity of the disease, reducing the number of severe forms and interrupting the evolutionary cycle of the helminth, thus ending the chain of transmission. This requires measures to limit access to contaminated freshwater sources, basic sanitation programs with drinking water supply and adequate treatment and correct disposal of sewage[44].

Control requires integration of snail control, improved water and sanitation, health education, targeted screening and treatment, and, where feasible, personal protection against cercarial exposure[6,44,45].

Health education interventions embedded in primary care have shown measurable impact on community engagement and preventive behaviors[46].

To date, there is no effective vaccine. Some immunization studies in animals have revealed important information for the development of immunobiologicals for humans. The biggest issue in this endeavor lies in the need for a better understanding of the Th1 and Th2 response patterns that are directly related to schistosomiasis mansoni. Some research with good results has drawn attention to the substances that make up the integument of *S. mansoni*. Others, also promising, are betting on the use of a combination of several antigens. Several studies are underway to integrate the antigens into a single element. The hope is to increase the effectiveness of the vaccine, which so far has been 70% effective. The species being investigated are *S. mansoni* and *S. haematobium*[2].

## 3. Haematobium schistosomiasis

Urogenital schistosomiasis caused by *S. haematobium* typically presents with dysuria and hematuria. In more severe cases, it may lead to renal failure and squamous cell carcinoma of the bladder. The adults of *S. haematobium* migrate through the bladder plexus, and their eggs are mainly excreted in the urine (Figure 3)[12].

### 3.1. Epidemiology

Schistosomiasis haematobium is endemic in 54 countries on the African and Asian continents such as Madagascar, the Middle East, along the Tigris and Euphrates rivers and the southwestern Arabian Peninsula[11], affecting, especially in these regions, around 110 million people worldwide[47].

The transmission of the disease is directly related to environmental and socio-economic aspects, including climate, the presence of intermediate host in the region, absent or inadequate water treatment, lack of basic sanitation, the habit of urinating and/or defecating in or near water collections. Activities that establish contact with water, such as fishing, recreation and domestic activities (washing clothes and dishes), are also the cause of many infections[48].

### 3.2. Pathophysiology

The pathophysiology of the disease involves the interaction of various aspects of the parasite and the host. Factors such as age at first infection, reinfection, acquired immunity and genetic susceptibility of the individual interfere with the course of the disease[49]. Excessive antigen production can lead to the formation of immune complexes. These, when deposited in the tissues together with pro-inflammatory cytokines, are responsible for most of the clinical manifestations, including fever at the onset of infection[49].

During the egg-laying phase, some eggs may lodge in the bladder mucosa or submucosa and may be surrounded by a granulomatous reaction or undergo a calcification process[49]. When the eggs are retained in the bladder wall or even in the ureter, significant damage can occur, including granulomatous inflammation, ulcerations, the development of pseudopolyps, urinary flow obstruction, hydronephrosis, hydroureter, kidney stones, proteinuria, hematuria and pyelonephritis. Some chronic inflammatory processes secondary to schistosomiasis have already been associated with bladder cancer[50].

In general, the inflammatory reaction is initiated by TCD4+



**Figure 3.** Eggs and miracidium of *Schistosoma haematobium* obtained from urina parasitological examination for filtration technique (swinnex-millipore / WHO filters). The red arrow points to the detail of the swinnex-millipore. Image from Teresa Baptista-Fernandes with permission.

lymphocytes and is regulated by the balance between the Th1 and Th2 response types. Helminth eggs secrete substances that induce a Th2-type immune response, responsible for the eosinophilic granulomatous reaction[2]. During their migration through different tissues and organs, the eggs cause an inflammatory reaction and fibrosis[49]. Furthermore, some of them can cause embolic phenomena or become trapped in other tissues. Still in the process of migration, if the eggs reach the brain or spinal cord, granulomas and/or compressive tumors may form, and the patient may suffer from transverse myelitis. In the lungs, perivascular granulomas decrease the flow of microcirculation, causing pre-capillary arteriovenous shunts, reducing blood oxygenation[15,49]. Ectopic lesions in the male genital system have already been recorded in the seminal vesicle, prostate and vas deferens[49].

### 3.3. Clinical aspects

The clinical picture of schistosomiasis haematobium begins with the entry of cercariae into the human host, a situation often characterized by erythema, papular rash and itching in the region of penetration[8]. Fever, headache, malaise, myalgia, anorexia, nausea, vomiting, cough and diarrhea are nonspecific symptoms that usually occur[12].

In some patients, terminal, painless and recurrent hematuria is observed. In more severe cases, hematuria remains throughout urination associated with dysuria, suprapubic pain and polyuria[51]. Some men may develop hemospermia. Chronic infection leads to bladder wall fibrosis, reduced capacity, ulcerations and pseudopolyps, predisposing to urinary tract obstruction and, in the long term, squamous cell carcinoma[8,50].

Possible complications include: stones in the renal calyx, bladder and ureters (manifesting as severe back pain); pyelonephritis; stenosis of the bladder neck with hydronephrosis; and chronic cystitis (due to the continuous action caused by *S. haematobium* eggs, which can be associated with bladder cancer)[8]. It is worth noting that granulomatous inflammation, pseudopolyps and ulcerations on the bladder and ureteral walls can simulate malignancy. In addition, cases of pre-sinusoidal portal hypertension can cause ectopic lung disease, as the formation of collateral circulation can enhance the migration of eggs into the pulmonary circulation[8]. When the eggs are deposited in the arterioles, they usually cause endarteritis obliterans, pulmonary arterial hypertension and cor pulmonale, with the most common signs and symptoms being dyspnea, cough and fever. Computed tomography (CT) can show a hardened and thickened bladder wall in patients with chronic infection[51].

Symptoms of neuroschistosomiasis (acute myelopathy or cerebral schistosomal disease) can also be present in schistosomiasis haematobium. The eggs deposited when they migrate through the bloodstream can reach the central nervous system, triggering a granulomatous inflammatory reaction with local tissue destruction and extensive scarring. Some particularities, considering the female and male reproductive systems, can cause different manifestations[8]. In women, the presence of granulomas in the fallopian tubes and ovaries increases the risk of HIV transmission, ectopic pregnancy and infertility. In men, granulomatous reactions can involve the epididymis, testicles, spermatic cord and prostate, sometimes causing irreversible damage if appropriate treatment is not instituted[51].

### 3.4. Differential diagnosis

Differential diagnosis schistosomiasis haematobium has a florid picture, with sometimes non-specific signs and symptoms, which can give rise to various etiological possibilities for the diagnosis. For this reason, laboratory evaluation is extremely useful for confirming the disease[8]. Because early manifestations (fever, rash, eosinophilia, urinary symptoms) are non-specific, schistosomiasis haematobium should be differentiated from common causes of febrile illness, urinary tract infection and hematuria according to the epidemiological context[8,51,52].

### 3.5. Laboratory diagnosis

Laboratory investigation of schistosomiasis haematobium, in addition to the clinical picture of the disease, must take into account epidemiological, economic, social and work-related aspects of the individual[45]. For non-resident patients who have traveled to endemic areas, the test of choice is serology, as the parasite load tends to be low. For residents of endemic areas, the detection of eggs in urine, mainly, or in feces is the most commonly used method for diagnosing the infection, as serology may not establish whether the infection is active[8].

Microscopy can be used to differentiate the species of the *Schistosoma* genus responsible for the infection, as well as to quantify the parasite load (morphological characterization allows species identification)[8]. Molecular biology techniques are important to increase sensitivity or in research, but to identify species and infection rate, morphological diagnosis after sedimentation technique and filtration technique (swinnex-millipore/WHO filters) are routinely used[51,52].

Tests such as cystoscopy, biopsy and histopathology make it possible to identify granulomatous lesions in the bladder tissue, ulcerations, polyps and tumors. These methods are of great importance in the chronic phase of the disease, when egg elimination is lower. Cystoscopy, in addition to identifying hematuria, can be indicated to assess complications and cure the disease. Cystoscopy with biopsy is not a routine test and is recommended for suspected

patients if no eggs are found in the urine[20]. Biopsy of polyps can identify eggs with granulomatous reaction and eosinophilia[8]. In addition, it can be useful for identifying eggs in the rectal mucosa, as well as obtaining histopathological material for lesions in ectopic sites[29].

With regard to serological tests, various *Schistosoma* antigens (whether in the cercarial, adult or egg form) are used. To date, few tests are species-specific. The Centers for Disease Control and Prevention (CDC) offers three: the screening test, fast-ELISA, based on the enzyme-linked immunosorbent assay, the Falcon assay; and EITB, immunoblotting a confirmation with the enzyme-linked immunoelectrotransfer blot and the analysis of human serum reactivity to adult microsomal antigen of schistosomiasis haematobium.

In order to confirm the diagnosis of schistosomiasis haematobium, a proper medical history and physical examination, together with well-indicated laboratory tests, are essential. Complementary exams; however, help in the assessment of patients. In fact, once the genitourinary system has been recognized, different imaging methods make it possible to verify and quantify tissue damage. Renal and urinary tract ultrasound can show irregularities in the bladder wall secondary to granulomas, as well as identifying hydronephrosis, polyps and tumors[20].

In cases of cerebral neuroschistosomiasis, CT and MRI of the skull are commonly used for evaluation. The possible findings are nonspecific infiltrates that may suggest a tumor. In the spine, MRI can detect intramyelinic lesions, extradural lesions, linear root thickening or nodular appearance and increased volume of the medullary cone. The test of choice for cases of spinal cord involvement is myelography[8].

### *3.6. Treatment*

Treatment of schistosomiasis haematobium varies according to the clinical presentation and stage of the disease (acute or chronic) and is of paramount importance in preventing complications and the development of neuroschistosomiasis. Even if a cure is not achieved by eliminating the helminth, treatment reduces the parasite load and, consequently, oviposition and the morbidity and mortality of the disease. In addition, if therapy is started early, there is the possibility of reversing various lesions[8].

The drug of choice is PZQ, orally, in a single dose (40 mg/kg). Another safe and effective option is to administer PZQ in three monthly doses of 60 mg/kg[40]. Treatment with the drug is generally well tolerated by patients. In order to significantly reduce the number of parasite eggs in the urine, the combination of praziquantel/artemether can be used[8], which is also effective in eliminating the young forms of *S. haematobium* between two and three weeks after the onset of infection[8].

### *3.7. Prophylaxis and control*

Control of schistosomiasis haematobium is based, in particular, on mass treatment of the infected population and the provision of basic sanitation. In addition, educational programs to raise awareness among the population about the importance of adopting preventive measures are fundamental[52].

Mass treatment of residents in endemic regions is carried out annually with the administration of PZQ, in children and adolescents, in order to reduce the prevalence and morbidity of the infection and the chain of transmission[53]. Studies highlight the possibility of developing an effective vaccine for schistosomiasis[2,49]. The most promising is the recombinant 28 kDa glutathione *S*-transferase vaccine from schistosomiasis haematobium (rSh28GST), which is considered to be well tolerated by infected children, but with still insufficient efficacy[54]. However, modification of the trial design and/or the use of alternative adjuvants aimed at a more balanced isotypic response may improve the efficacy of this vaccine[2].

## 4. Japanese schistosomiasis

Japanese schistosomiasis, also known as Katayama disease is caused by *S. japonicum*. The most common manifestation of the disease is intestinal involvement, and more rarely, involvement of the central nervous system. It occurs in China, more precisely in the Yangtze River basin. However, it has also been described in Indonesia and the southern and eastern islands of the Philippines[8]. In Japan, it has been considered eradicated since 1993[49]. This species of *Schistosoma* is zoonotic and infects mammals such as pigs, cattle, buffalo and dogs, which are considered to be reservoirs of the parasite[9].

The immune response is directed at the cercariae, the adults and the eggs. However, the adult worms have mechanisms for escaping the host's humoral and cellular responses. There is evidence of a polarized Th1 and Th2 cellular immune response, depending on the course of infection. Individuals with previous exposure to cercariae, when subjected to new penetration, can trigger a specific response with IgG and IgE antibodies, macrophages and eosinophils, clinically manifested by edema and local inflammatory reaction (dermatitis). The signs and symptoms of the acute phase of the disease appear eight weeks after infection and consist of a febrile illness, due to the immune complexes and pro-inflammatory cytokines circulating in the bloodstream[55]. The severity of the infection is related to the duration and intensity of the inflammatory reaction to the eggs, the possibility of co-infection and genetic susceptibility. Death is especially due to complications of portal hypertension, ascites and hepatosplenomegaly[25].

In the chronic phase, intestinal manifestations occur. This includes anorexia, intermittent abdominal pain and diarrhea. More serious changes can occur, such as chronic ulcerations of the colon (responsible for iron deficiency anemia due to bleeding), polyps (developed by the union of eggs and granulomas in the intestinal wall), stenosis and, in rarer conditions, appendicitis[56].

To establish the diagnosis, it is important that clinical suspicion takes into account the epidemiological aspects and clinical findings of Japanese schistosomiasis. Confirmation can be made through the presence of helminth eggs in stool samples, using the modified Kato-Katz method, repeated three times[8].

Treatment for Katayama fever includes the use of corticosteroids (prednisolone 20 to 40 mg/day for five days) to reduce inflammation, and PZQ (40 to 60 mg/kg, divided into two to three daily doses). In cases of pruritus in cercarial dermatitis, the therapeutic approach is symptomatic[25]. For chronic disease, PZQ is the drug of choice. Treatment is generally well tolerated with mild adverse reactions[57].

In endemic areas, helminthiasis control strategies involve basic sanitation measures and mass treatment. Such actions have been sufficient to eradicate Japanese schistosomiasis in Japan. There are still no vaccines. However, research shows that prolonged exposure to *S. japonicum* can produce immunity against subsequent infection[58]. In non-endemic areas, the disease is rarely reported. However, it is very likely that data from infections in non-endemic regions is underestimated, as the tools for more specific diagnosis are not always available and health professionals show a low level of awareness of the disease. It is important; however, that more attention is paid to travelers to endemic regions, as the adults of the worm can remain viable and persist for decades[59].

## 5. Intercalatum schistosomiasis and other schistosomiases

Schistosomiasis intercalatum, whose etiological agent is *S. intercalatum* is a zoonosis[8], which manifests itself in humans with severe but underreported intestinal symptoms. In addition, more severe cases of the disease can result in myeloradiculitis, which serves as a warning of the neurological involvement associated with schistosomiasis. Other neurological symptoms include acute progression syndrome, characterized by paraplegia of the lower limbs and urinary bladder dysfunction[60]. The pathogen shows tropism for liver and intestinal tissues, especially in the portal and mesenteric systems[8].

Infection with *S. intercalatum* begins with the penetration of cercariae into the dermis of humans and their subsequent transformation into schistosomulum. After reaching maturity, these become adult helminths, which mate. The female migrates against the blood flow towards the mesenteric or vesical venous plexus, where she lays her eggs. After laying, the eggs can be directed to different tissues and organs or eliminated through feces, when they are in the intestinal lumen, or through urine, when in the bladder[8].

The metazoan is concentrated in the territories of South Africa and West Africa, so that the regions considered endemic for schistosomiasis intercalatum are distributed in Lower Guinea and the Congo. São Tomé and Príncipe is exclusively home to schistosomiasis intercalata. Few cases have been reported in Angola, Senegal and Uganda[3]. On the European continent, imported cases from endemic areas have been recorded. This limited area of schistosomiasis intercalata is probably due to interspecific competition between *S. intercalatum*, *S. mansoni* and *S. haematobium*, as well as aspects related to gene mutation[61].

In schistosomiasis intercalata, the immune response is directed at the parasite eggs found in the liver and intestine, and the mechanism basically involved is the formation of granulomas[13].

The diagnosis of schistosomiasis intercalata must take into account clinical suspicion, associated with epidemiological data and the identification of *S. intercalatum* eggs (Figure 4) in feces or urine. The eggs, although similar to those of *S. haematobium*, are larger (around 140 μm × 240 μm), have an equatorial constriction and a larger terminal spicule (Figure 4).

In cases of intestinal schistosomiasis intercalata, when stool tests are systematically negative, superficial rectal biopsy should be performed, which shows greater sensitivity. Liver biopsy is indicated

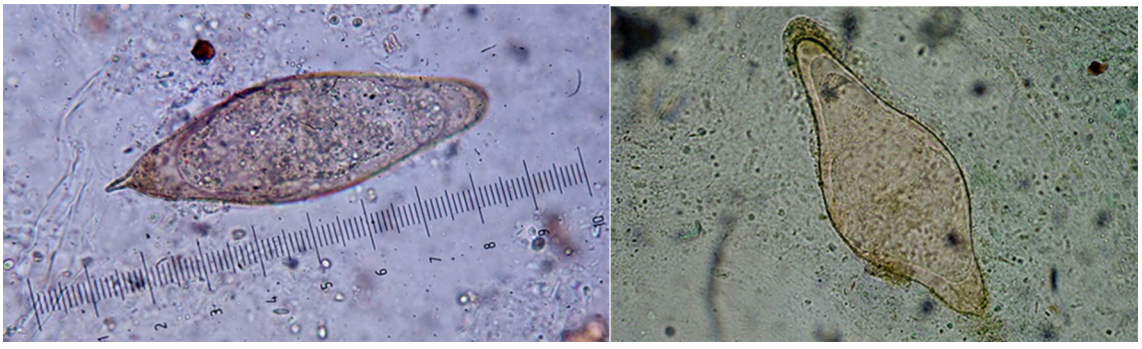

**Figure 4.** Eggs of *Shistosoma intercalatum* obtained from feces parasitological examination. Image from Teresa Baptista-Fernandes with permission.

in selected cases[8]. The most serious cases affecting the spinal cord can be diagnosed by magnetic resonance imaging[60].

The acute schistosomiasis intercalata is treated with PZQ (40 mg/kg), orally, in a single dose, a drug that is generally well tolerated and has mild adverse effects[61]. In endemic regions, annual mass treatment with PZQ, 20 mg/kg in children and adults, is used to control the disease, and emphasis is placed on basic sanitation programs, distribution of drinking water and educational actions to raise public awareness[62]. Furthermore, the aim is to develop an effective vaccine.

*S. mekongi* is a species restricted to the Mekong River basin and tributaries, in Laos and Cambodia[63], countries where infection by the pathogen is a public health concern, with infection rates exceeding 140 000 cases[64]. In recent decades, these countries have made significant progress in controlling the disease, but efforts are still needed to eradicate the parasitosis[65]. In the biological cycle, the intermediate host is the mollusc of the species *Neotricula aperta*[66,67] and the definitive hosts are mammalian dogs, pigs, cattle and rodents, including humans[68]. In humans, the clinical presentation of the disease is similar to that which occurs in patients infected with *S. japonicum*, and may show portal hypertension with a risk of death due to digestive hemorrhage. Diagnosis is obtained by parasitological examination of feces using the modified Kato-Katz method and PZQ is the treatment of choice, in doses of 60 mg/kg, divided into three doses per day[69].

*S. bovis* causes a transient and rare infection in humans, usually with cercarial dermatitis. The parasite's intermediate hosts are *B. molluscs*, such as *B. africanus* and *B. truncatus*, species found in some regions of the Middle East, Africa and the Mediterranean[70]. In places where *S. bovis* and *S. haematobium* coexist, hybridization between the species can occur[71,72], which can be differentiated by molecular tests[70]. Hybrid infection between *S. haematobium* and *S. bovis* has already been recorded in African and European countries[73]. *S. curassoni* is a species described in West Asia, whose intermediate hosts belong to the genus *Bulinus*, and can eventually infect humans. The helminth has already been described in ruminant feces in Nigeria and Senegal[74].

## 6. Final considerations

Schistosomiasis is recognized as a parasitic disease of great relevance worldwide, both in endemic areas and in regions where the helminth is not transmitted, due to the possibility of imported cases[75]. These parasitic diseases are, in fact, morbid conditions capable of producing serious conditions, as well as having an impact on child development, especially in less economically favored countries.

Patients can develop asymptomatic or mild infectious processes, but clinical situations of significant morbidity can arise, especially those related to digestive (portal hypertension), neurological (neuroschistosomiasis) and pulmonary conditions[33]. Diagnosis is usually established by observing helminth eggs, but immunological, molecular and antigen detection techniques can be used[35].

Recent advances in diagnostic technologies are paving the way for more accurate surveillance. The integration of Artificial Intelligence (AI) into automated microscopy systems for Kato-Katz slides offers a potential solution to standardize egg counting and reduce human error. Furthermore, Point-of-Care ultrasound devices assisted by AI algorithms are being investigated to detect early signs of hepatic fibrosis in field settings, representing a significant leap forward from traditional methods[75]. It is also vital to adopt a "One Health" approach, recognizing that human health is connected to the health of animals and the environment. Since species like *S. japonicum* are zoonotic and hybridization events between human and animal schistosomes (*e.g.*, *S. haematobium* hybridized with *S. bovis*) are increasingly reported, control strategies must integrate veterinary interventions and environmental management to be truly effective[1,9,72].

To date, even with attempts to establish new drugs such as ivermectin, schistosomiasis has mainly been treated with PZQ, a drug that is also useful for reducing the transmission of the disease. This prophylactic measure must be combined with improvements in people's living conditions, namely access to drinking water and basic sanitation and health education. Despite the existing control measures, the development of vaccines remains an important scientific frontier, as it could make a decisive contribution to the control of this neglected disease which, in different regions of the world, still imposes severe suffering on people today-in the middle of the 21st century. However, the development of a vaccine against schistosomiasis will play only a limited role in effectively controlling the disease if it is not accompanied by full implementation of basic sanitation, universal access to quality education, and poverty reduction. These socio-economic factors are crucial and must complement any biomedical intervention for a comprehensive fight against the disease. Further studies are needed to fill important gaps that remain regarding resistance to PZQ, the impact of co-infections, the effectiveness of long-term control strategies, and vaccine development, which limits the ability to make more conclusive recommendations on global schistosomiasis control based on the currently available evidence.

## Conflict of interest statement

The authors declare that there are no conflicts of interest.

## Funding

The authors received no extramural funding for the study.

## Authors' contributions

P.S.B.M., R.S.B., and A.P.G. participated in the conception and design of the study, developed the theoretical framework, wrote the first draft of the manuscript, and contributed to the final version. G.A.P. and S.S.S. conducted the literature search and also collaborated on the final version of the text. A.N.R.J. and T.B.F. were responsible for the illustrations and contributed to the final version of the manuscript. All authors participated in the intellectual review of the text, made adjustments to the final draft, and approved the submitted version, assuming responsibility for the content of the article.

## References

[1] Catalano S, Léger E, Fall CB, Borlase A, Diop SD, Berger D, et al. Multihost transmission of *Schistosoma mansoni* in Senegal, 2015-2018. *Emerg Infect Dis* 2020; **26**(6): 1234-1242.

[2] Panzner U. Transmission modelling for human non-zoonotic schistosomiasis incorporating vaccination: Guiding decision-and policymaking. *Parasitology* 2024; **4**(2): 101-128.

[3] World Health Organization. *Ending the neglect to attain the Sustainable Development Goals: A road map for neglected tropical diseases 2021–2030*. Geneva: World Health Organization; 2021.

[4] Deol AK, Fleming FM, Calvo-Urbano B, Walker M, Bucumi V, Gnandou I, et al. Schistosomiasis-assessing progress toward the 2020 and 2025 global goals. *N Engl J Med* 2019; **381**(26): 2519-2528.

[5] Sarr M, Diop M, Bakhoum AJ, Doucoure S, Sow D, Bâ CT, et al. The Senegalese and Brazilian strains of *Schistosoma mansoni* exhibit high compatibility with *Biomphalaria pfeifferi* and *Biomphalaria glabrata*. *Parasit Vectors* 2025; **18**(1): 314. doi: 10.1186/s13071-025-06918-5.

[6] Ministry of Health of Brazil. Health Surveillance Secretariat. *Health surveillance guide: Single volume*. 3rd ed. Brasília: Ministry of Health; 2024.

[7] Kittur N, King CH, Campbell CH, Kinung'hi S, Mwinzi PNM, Karanja DMS, et al. Persistent hotspots in schistosomiasis consortium for operational research and evaluation studies for gaining and sustaining control of schistosomiasis after four years of mass drug administration of praziquantel. *Am J Trop Med Hyg* 2019; **101**(3): 617-627.

[8] Clerinx J, Soentjens P. *Schistosomiasis: Epidemiology, clinical manifestations, and diagnosis*. [Online]. Available from: https://www.uptodate.com/contents/schistosomiasis-epidemiology-clinical-manifestations-and-diagnosis. [Accessed on 6 September 2025].

[9] McManus DP, Dunne DW, Sacko M, Utzinger J, Vennervald BJ, Zhou XN. Schistosomiasis. *Nat Rev Dis Primers* 2018. doi: https://doi.org/10.1038/s41572-018-0013-8.

[10] Sayasone S, Khattignavong P, Keomalaphet S, Prasayasith P, Soundala P, Sannikone S, et al. Low prevalence of *Schistosoma mekongi* infection and high prevalence of other helminth infections among domestic animals in southern Lao People's Democratic Republic. *Trop Med Infect Dis* 2023; **8**(7): 372. doi: 10.3390/tropicalmed8070372.

[11] Centers for Disease Control and Prevention (CDC). *About schistosomiasis*. 2024. [Online]. Available from: https://www.cdc.gov/schistosomiasis/about/index.html. [Accessed on 23 September 2024].

[12] Buonfrate D, Ferrari TCA, Adegnika AA, Stothard JR, Gobbi FG. Human schistosomiasis. *Lancet* 2025; **405**(10479): 658-670.

[13] Barsoum RS, Esmat G, El-Baz T. Human schistosomiasis: Clinical perspective. *J Adv Res* 2013; **4**(5): 433-444.

[14] Houlder EL, Costain AH, Nambuya I, Brown SL, Koopman JPR, Langenberg MCC, et al. Pulmonary inflammation promoted by type-2 dendritic cells is a feature of human and murine schistosomiasis. *Nat Commun* 2023; **14**(1): 1863. doi: 10.1038/s41467-023-37502-z.

[15] Mickael CS, Graham BB. The role of type 2 inflammation in *Schistosoma*-induced pulmonary hypertension. *Front Immunol* 2019; **10**: 27.

[16] Graham BB, Kumar R. Schistosomiasis and the pulmonary vasculature (2013 Grover Conference Series). *Pulm Circ* 2014; **4**(3): 353-362.

[17] Casella ML, Fanni VSS, Verndl DO, Basso MC, Mello LF, Glina S. Schistosomiasis mansoni of the bladder simulating bladder cancer: A case report. *Rev Soc Bras Med Trop* 2009; **42**(5): 581-582.

[18] De Liberato C, Berrilli F, Bossù T, Magliano A, Montalbano Di Filippo M, Di Cave D, et al. Outbreak of swimmer's itch in central Italy: Description, causative agent and preventive measures. *Zoonoses Public Health* 2019; **66**(4): 377-381.

[19] Gray DJ, Ross AG, Li YS, McManus DP. Diagnosis and management of schistosomiasis. *BMJ* 2011; **342**: d2651. doi: 10.1136/bmj.d2651.

[20] Langenberg MCC, Hoogerwerf MA, Janse JJ, van Lieshout L, Corstjens PLAM, Roestenberg M, et al. Katayama syndrome without *Schistosoma mansoni* eggs. *Ann Intern Med* 2019; **170**(10): 732-733.

[21] Centers for Disease Control and Prevention (CDC). *Clinical overview of schistosomiasis*. 2024. [Online]. Available from: https://www.cdc.gov/schistosomiasis/hcp/clinical-overview/index.html#print. [Accessed on 25 November 2024].

[22] Pontes IBS, Duarte Neto AN, Dias CB. Glomerulopathy associated with schistosomiasis mansoni. *Braz J Nephrol* 2026; **48**(1): e20250084. doi: 10.1590/2175-8239-JBN-2025-0084en.

[23] Bernardo TC. Insights on the pathophysiology of the progression to decompensated hepato-splenic schistosomiasis. *Med Res Arch* 2023; **11**(4). doi: 10.18103/mra.v11i4.3774.

[24] Veiga ZST, Fernandes FF, Guimarães L, Piedade J, Pereira GHS. Natural History of Hepatosplenic schistosomiasis (HSS) non-cirrhotic portal hypertension (NCPH): Influence of gastrointestinal bleeding and

decompensation in prognosis. *Trop Med Infect Dis* 2023; **8**(3): 145. doi: 10.3390/tropicalmed8030145.

[25]Ross AG, McManus DP, Farrar J, Hunstman RJ, Gray DJ, Li YS. Neuroschistosomiasis. *J Neurol* 2012; **259**(1): 22-32.

[26]Carvalho OAM. Mansonic neuroschistosomiasis. *Arq Neuro−Psiquiatr* 2013; **71**(9): 714-716.

[27]Kongs A, Marks G, Verle P, Van der Stuyft P. The unreliability of the Kato-Katz technique limits its usefulness for evaluating *Schistosoma mansoni* infections. *Trop Med Int Health* 2001; **6**(3): 163-169.

[28]Soares FA, Benitez AN, Santos BM, Loiola SHN, Rosa SL, Nagata WB, et al. A historical review of the techniques of recovery of parasites for their detection in human stools. *Rev Soc Bras Med Trop* 2020; **53**: e20190535.

[29]Keïta K, Loique Djeugoué S, Daoud Camara B, Alfousséni Doumbia A, OUmar Kamissoko C, Sandji O, et al. A cross-sectional analysis of schistosomiasis case detection by rectal mucosal biopsy among patients attending the digestive endoscopy unit of the internal medicine department. *J Intervent Epidemiol Public Health* 2025; **8**(2): 1-24.

[30]Colley DG, Ramzy RM, Maganga J, Kinung'hi S, Odiere MR, Musuva RM, et al. The POC-CCA assay for detection of *Schistosoma mansoni* infection needs standardization in production and proper quality control to be reliable. *Acta Trop* 2023; **238**: 106795. doi: 10.1016/j.actatropica.2022.106795.

[31]Hoekstra PT, De Dood CJ, Abdoel T, Hilt S, Van Diepen A, Polman K, et al. Detecting two *Schistosoma* circulating antigens-CCA and CAA-in urine and serum to improve diagnosis of human schistosomiasis. *Front Parasitol* 2024; **3**: 1460331.

[32]Vaillant MT, Philippy F, Neven A, Barré J, Bulaev D, Olliaro PL, et al. Diagnostic tests for human *Schistosoma mansoni* and *Schistosoma haematobium* infection: A systematic review and meta-analysis. *Lancet Microbe* 2024; **5**(4): e366-e378.

[33]Bansal A, Albano JE, Jayakumar D. Neuroschistosomiasis presenting as recurrent seizures: A case report. *Surg Neurol Int* 2025; **16**: 51.

[34]Kamal I, Abdallah A, Khalid M, Musa A, Elzouki AN. Diagnosis of neuroschistosomiasis: How to overcome this challenge. *Libyan J Med Sci* 2020; **4**(1): 35-37.

[35]Rissardo JP, Byroju VV, Caprara ALF. *Neuroschistosomiasis: A narrative review of a multifaceted nature of a neglected tropical disease*. 2024. [Online]. Available from: https://doi.org/10.20944/preprints202412.0822.v1.

[36]Thomas CM, Timson DJ. The mechanism of action of praziquantel: Six hypotheses. *Curr Top Med Chem* 2018; **18**(18): 1575-1584.

[37]Abou-El-Naga IF, Amer EI, Boulos LM, El-Faham MH, Abou Seada NM, Younis SS. Biological and proteomic studies of *Schistosoma mansoni* with decreased sensitivity to praziquantel. *Comp Immunol Microbiol Infect Dis* 2019; **66**: 101341. doi: 10.1016/j.cimid.2019.101341.

[38]Sanchez ME, Cupit PM, Bu L, Cunningham CE. Transcriptomic analysis of reduced sensitivity to praziquantel in *Schistosoma mansoni*. *Mol Biochem Parasitol* 2019; **228**: 6-15.

[39]Afshar R, Daelken B, Greco B. PA-325 The pediatric praziquantel consortium: Our development journey to provide treatment to pre-school aged children. *BMJ Glob Health* 2023; **8**(Suppl_10). https://doi.org/10.1136/bmjgh-2023-EDC.162.

[40]Registro Brasileiro de Ensaios Clínicos. *Assessment of praziquantel medication for children living in areas where schistosomiasis is common in Bahia and Sergipe*. 2024. [Online]. Available from: https://ensaiosclinicos.gov.br/rg/RBR-86kcy37. [Accessed on 6 September 2025].

[41]The Pediatric Praziquantel Consortium. [Online]. Available from: https://www.pediatricpraziquantelconsortium.org/. [Accessed on 6 September 2025].

[42]Mengarda AC, Iles B, Rodrigues VC, Lima AL, Machado VP, Reatgui WS, et al. Praziquantel nanoparticle formulation for the treatment of schistosomiasis. *ACS Appl Nano Mater* 2025; **8**(8): 3985-3997.

[43]Bustinduy AL, Edielu A, Ayebazibwe GK, Nakyesige R, Anguajibi V, Mpooya S, et al. Safety and efficacy of praziquantel 40 mg/kg versus 80 mg/kg in preschool-aged children with intestinal schistosomiasis in Uganda: A 2×2 factorial, double-blind, placebo-controlled, phase 2 randomised trial. *Lancet Glob Health* 2025; **13**(6): e1091-e1100.

[44]El-Kassas M, El Sheemy R, Elbadry M. Strategies and achievements in controlling and eliminating schistosomiasis from Egypt. *Egypt Liver J* 2024; **14**(31). doi: org/10.1186/s43066-024-00339-2.

[45]World Health Organization. *WHO guideline on control and elimination of human schistosomiasis*. Geneva: World Health Organization; 2022.

[46]Mendonça AF, Jansen ACS, da Cruz Pinheiro I, de Almeida DTL, do Ano JDA, Bezerra JMT, et al. Impacts of educational interventions on schistosomiasis awareness in a school community. *J Trop Pathol* 2025; **54**(1): 1-13.

[47]Mertelsmann AM, Bowers SF, Wright D, Maganga JK, Mazigo HD, Ndhlovu LC, et al. Effects of *Schistosoma haematobium* infection and treatment on the systemic and mucosal immune phenotype, gene expression and microbiome: A systematic review. *PLoS Negl Trop Dis* 2024; **18**(9): e0012456. doi: 10.1371/journal.pntd.0012456

[48]Pennance T, Ame SM, Amour AK, Suleiman KR, Muhsin MA, Kabole F, et al. Transmission and diversity of *Schistosoma haematobium* and *S. bovis* and their freshwater intermediate snail hosts *Bulinus globosus* and *B. nasutus* in the Zanzibar Archipelago, United Republic of Tanzania. *PLoS Negl Trop Dis* 2022; **16**(7): e0010585.

[49]Gryseels B, Polman K, Clerinx J, Kestens L. Human schistosomiasis. *Lancet* 2006; **368**(9541): 1106-1118.

[50]Silva R, Thiengo R, Conceição MJ, Rey L, Filho EP, Ribeiro PC. Cystoscopy in the diagnosis and follow-up of urinary schistosomiasis in Brazilian soldiers returning from Mozambique, Africa. *Rev Inst Med Trop Sao Paulo* 2006; **48**(1): 39-42.

[51]Lackey EK, Horrall S. *Schistosomiasis*. 2023. [Online]. Available from: https://www.ncbi.nlm.nih.gov/books/NBK554434/. [Accessed on 7 November 2025].

[52]Steinmann P, Keiser J, Bos R, Tanner M, Utzinger J. Schistosomiasis and water resources development: Systematic review, meta-analysis, and

estimates of people at risk. *Lancet Infect Dis* 2006; **6**(7): 411-425.

[53]Cleland CR, Tukahebwa EM, Fenwick A, Blair L. Mass drug administration with praziquantel reduces the prevalence of *Schistosoma mansoni* and improves liver morbidity in untreated preschool children. *Trans R Soc Trop Med Hyg* 2014; **108**(9): 575-581.

[54]Riveau G, Schacht AM, Dompnier JP, Deplanque D, Seck M, Waucquier N, et al. Safety and efficacy of the rSh28GST urinary schistosomiasis vaccine: A phase 3 randomized, controlled trial in Senegalese children. *PLoS Negl Trop Dis* 2018; **12**(12): e0006968.

[55]Tebeje BM, Harvie M, You H, Rivera V, McManus DP. T cell-mediated immunity in CBA mice during *Schistosoma japonicum* infection. *Exp Parasitol* 2019; **204**: 107725.

[56]Stothard JR, Sousa-Figueiredo JC, Betson M, Bustinduy A, Reinhard-Rupp J. Schistosomiasis in African infants and preschool children: Let them now be treated. *Trends Parasitol* 2013; **29**(4): 197-205.

[57]Gordon CA, Kurscheid J, Williams GM, Clements ACA, Li Y, Zhou XN, et al. Asian schistosomiasis: Current status and prospects for control leading to elimination. *Trop Med Infect Dis* 2019; **4**(1): 40.

[58]Wang LD, Chen HG, Guo JG, Zeng XJ, Hong XL, Xiong JJ, et al. A strategy to control transmission of *Schistosoma japonicum* in China. *N Engl J Med* 2009; **360**(2): 121-128.

[59]Vellere I, Mangano VD, Cagno MC, Gobbi F, Ragusa A, Bartoloni A, et al. Imported human *Schistosoma japonicum*: A report on two cases in Filipino migrants present in Italy and a systematic review of literature. *Travel Med Infect Dis* 2020; **36**: 101496.

[60]Baptista-Fernandes T, Pessanha M, Cabral P, Relvas L, Marques T. *Myeloradiculopathy by Schistosoma intercalatum: An underdiagnosed disease. A clinical case.* 2013. [Online]. Available from: https://elibrary.escmid.org/?search%5Border%5D=relevance&search%5Bpage%5D=1&search%5Bquery%5D=%22P.%20Cabral%22. [Accessed on 6 September 2025].

[61]Kołodziej P, Szostakowska B, Lass A, Sulima M, Sikorska K, Kocki J, et al. Chronic intestinal schistosomiasis caused by co-infection with *Schistosoma intercalatum* and *Schistosoma mansoni*. *Lancet Infect Dis* 2024; **24**(3): e196-e205.

[62]Agniwo P, Dembélé L, Koné A, Sidibé B, Konaté A, Garango A, et al. Evaluation of praziquantel efficacy in children after two decades of mass distribution in Bamako, Mali. *J Interv Epidemiol Public Health* 2025; **8**(4): 92.

[63]Khieu V, Sayasone S, Muth S, Kirinoki M, Laymanivong S, Ohmae H, et al. Elimination of schistosomiasis mekongi from endemic areas in Cambodia and the Lao People's Democratic Republic: Current status and plans. *Trop Med Infect Dis* 2019; **4**(1): 30.

[64]Uthailak N, Adisakwattana P, Thiangtrongjit T, Limpanont Y, Chusongsang S, Chusongsang Y, et al. Discovery of *Schistosoma mekongi* circulating proteins and antigens in infected mouse sera. *PLoS One* 2022; **17**(10): e0275992.

[65]Kumagai T, Matsumoto-Takahashi ELA, Ishikawa H, Keomalaphet S, Khattignavong P, Soundala P, et al. Detection of *Schistosoma mekongi* DNA in human stool and intermediate host snail *Neotricula aperta via* loop-mediated isothermal amplification assay in Lao PDR. *Pathogens* 2022; **11**(12): 1413.

[66]Attwood SW, Liu L, Huo GN. Population genetic structure and geographical variation in *Neotricula aperta* (Gastropoda: Pomatiopsidae), the snail intermediate host of *Schistosoma mekongi* (Digenea: Schistosomatidae). *PLoS Negl Trop Dis* 2019; **13**(1): e0007061.

[67]Younis SS, Abou-El-Naga IF, Radwan KH. Molluscicidal effect of green synthesized silver nanoparticles using *Azadirachta indica* on *Biomphalaria alexandrina* snails and *Schistosoma mansoni* cercariae. *Asian Pac J Trop Biomed* 2023; **13**(1): 35-44.

[68]Zhou M, Xu L, Xu D, Chen W, Khan J, Hu Y, et al. Chromosome-scale genome of the human blood fluke *Schistosoma mekongi* and its implications for public health. *Infect Dis Poverty* 2023; **12**(1): 104.

[69]Centers for Disease Control and Prevention (CDC). *Clinical care of schistosomiasis*. [Online]. Available from: https://www.cdc.gov/schistosomiasis/hcp/treatment/index.html. [Accessed on 25 November 2025].

[70]Webster BL, Southgate VR, Littlewood DT. A revision of the interrelationships of *Schistosoma* including the recently described *Schistosoma guineensis*. *Int J Parasitol* 2006; **36**(8): 947-955.

[71]Sene-Wade M, Marchand B, Rollinson D, Webster BL. Urogenital schistosomiasis and hybridization between *Schistosoma haematobium* and *Schistosoma bovis* in adults living in Richard-Toll, Senegal. *Parasitology* 2018; **145**(13): 1723-1726.

[72]Angora EK, Allienne JF, Rey O, Menan H, Touré AO, Coulibaly JT, et al. High prevalence of *Schistosoma haematobium* × *Schistosoma bovis* hybrids in schoolchildren in Côte d'Ivoire. *Parasitology* 2019; **147**(3): 287-294.

[73]Teukeng FFD, Blin M, Bech N, Gomez MR, Zein-Eddine R, Simo AMK, et al. Hybridization increases genetic diversity in *Schistosoma haematobium* populations infecting humans in Cameroon. *Infect Dis Poverty* 2022; **11**(1): 30.

[74]Léger E, Garba A, Hamidou AA, Webster BL, Pennance T, Rollinson D, et al. Introgressed animal schistosomes *Schistosoma curassoni* and *S. bovis* naturally infecting humans. *Emerg Infect Dis* 2016; **22**(12): 2212-2214.

[75]Ekloh W, Asafu-Adjaye A, Tawiah-Mensah CNL, Ayivi-Tosuh SM, Quartey NK, Aiduenu AF, et al. A comprehensive exploration of schistosomiasis: Global impact, molecular characterization, drug discovery, artificial intelligence and future prospects. *Heliyon* 2024; **10**(12): e33070.

## Publisher's note

The Publisher of the *Journal* remains neutral with regard to jurisdictional claims in published maps and institutional affiliations.

Edited by Zhang Q, Lei Y, Pan Y