

Case Report

Asian Pacific Journal of Tropical Medicine

apjtm.org

doi: 10.4103/apjtm.apjtm_644_25

Disseminated *Nocardia farcinica* post haematopoietic stem cell transplantation: A case report

Anik Trivedi[1], Nayana Shah[1]✉, Reetu Jain[1], Sunil Chopade[1], Mala Kaneria[2], Ganapathi Bhat[1], Samir Shah[1], Kapil Rathi[1], Ira Dhamdere[1], Abhishek Mehta[1]

Departments of [1]Medical Oncology and [2]Infectious Disease, Jaslok Hospital and Research Centre, 15, Pedder Rd, IT Colony, Tardeo, Mumbai, Maharashtra 400026, India

ABSTRACT

Rationale: Nocardiosis is an uncommon but serious opportunistic infection in immunocompromised patients, particularly following haematopoietic stem cell transplantation (HSCT). *Nocardia farcinica* is notable for its virulence and tendency to cause disseminated disease.

Patient concerns: A female HSCT recipient presented several months post-transplant with progressive left shoulder pain unresponsive to conservative management.

Diagnosis: Magnetic resonance imaging revealed an abscess involving the acromioclavicular joint and surrounding musculature. Histopathology showed filamentous, branching Gram-positive bacilli, and microbiological identification confirmed *Nocardia farcinica*. Chest imaging demonstrated pulmonary involvement consistent with disseminated nocardiosis.

Interventions: Combination antimicrobial therapy with imipenem, amikacin, and trimethoprim-sulfamethoxazole was initiated, followed by prolonged oral therapy.

Outcomes: The patient achieved complete clinical and radiological resolution with no relapse.

Lessons: Early recognition and timely initiation of appropriate combination antimicrobial therapy are essential for favourable outcomes in disseminated nocardiosis after HSCT.

KEYWORDS: *Nocardia farcinica*; Haematopoietic stem cell transplantation; Disseminated nocardiosis; Musculoskeletal infection; Immunocompromised host; Case report

1. Introduction

Nocardia species are aerobic, filamentous, Gram-positive organisms that cause opportunistic infections predominantly in immunocompromised individuals. Nocardiosis following haematopoietic stem cell transplantation (HSCT) is uncommon, with an estimated incidence of 0.3%-1% and a reported one-year mortality approaching 40%[1]. The infection typically manifests during the late post-transplant period and often presents with non-specific clinical features.

Nocardia (*N.*) *farcinica* is of particular clinical importance owing to its enhanced virulence, intrinsic antimicrobial resistance, and tendency for dissemination[2]. Pulmonary infection is usually the primary manifestation, with subsequent haematogenous spread to extrapulmonary sites, including the central nervous system and musculoskeletal system[3].

2. Case presentation

A middle-aged female with early T-cell precursor acute lymphoblastic leukaemia achieved minimal residual disease-negative remission following induction chemotherapy and subsequently underwent a fully HLA-matched unrelated donor HSCT. Conditioning consisted of total marrow and lymphoid

✉To whom correspondence may be addressed. E-mail: nayanshah1999@gmail.com

This is an open access article distributed under the terms of the Creative Commons Attribution-Non-Commercial-No Derivatives License 4.0 (CCBY-NC-ND), where it is permissible to download and share the work provided it is properly cited. The work cannot be changed in any way or used commercially without permission from the journal.

For reprints contact: reprints@medknow.com

©2026 *Asian Pacific Journal of Tropical Medicine* Produced by Wolters Kluwer-Medknow.

How to cite this article: Trivedi A, Shah N, Jain R, Chopade S, Kaneria M, Bhat G, et al. Disseminated *Nocardia farcinica* post haematopoietic stem cell transplantation: A case report. Asian Pac J Trop Med 2026; 19(3): 138-140.

Article history: Received 15 November 2025 Revision 14 March 2026
Accepted 21 March 2026 Available online 24 March 2026

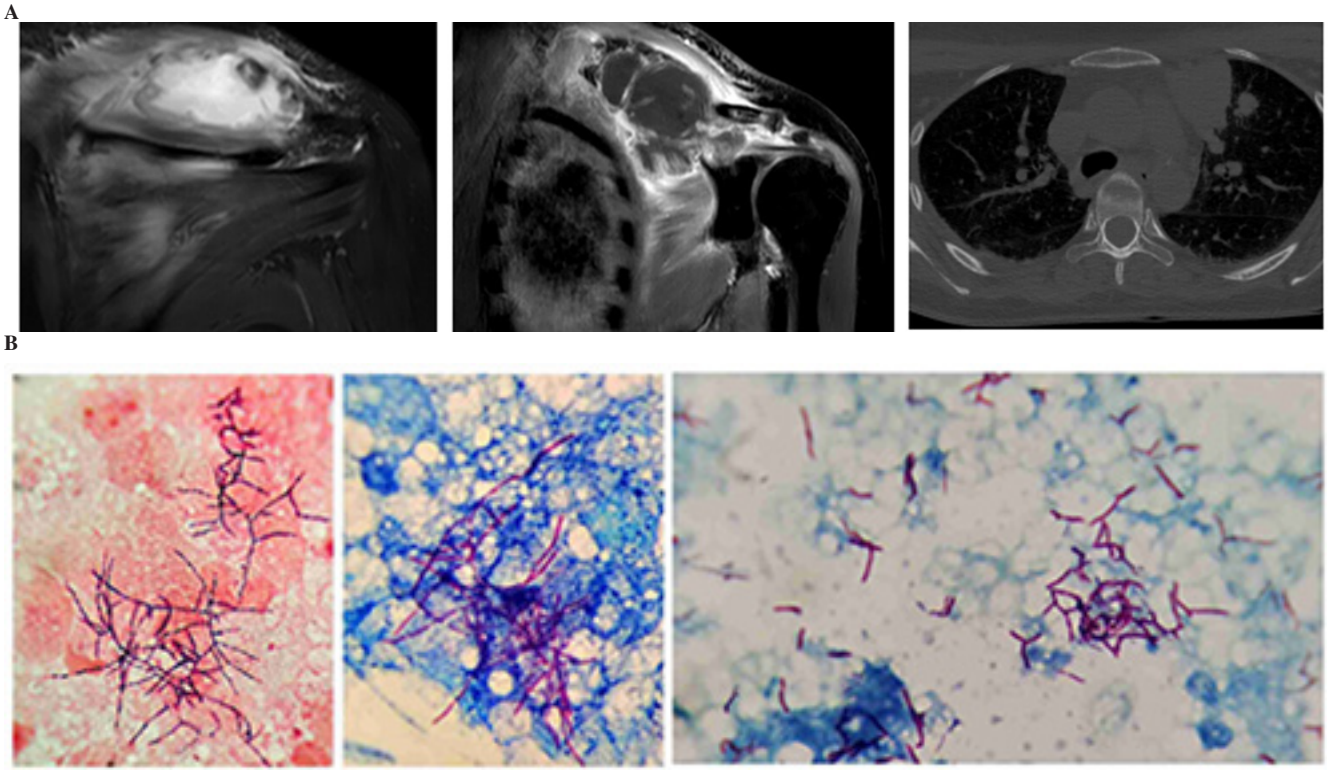

Figure 1. A: Magnetic resonance imaging of the left shoulder in a middle-aged female haematopoietic stem cell transplantation recipient with disseminated nocardiosis. B: Histopathology of abscess tissue. Magnetic resonance imaging demonstrating a peripherally enhancing intermuscular abscess involving the supraspinatus and subscapular is regions with surrounding oedema and minimal joint effusion, without bony involvement. Histopathological examination showing necroinflammatory exudate containing filamentous, branching Gram-positive bacilli consistent with *Nocardia* species. Initial morphological interpretation as fungal infection was corrected following microbiological identification.

irradiation with cyclophosphamide. Graft-*versus*-host disease (GVHD) prophylaxis included antithymocyte globulin, methotrexate, and cyclosporine.

Standard antimicrobial prophylaxis was administered during the early post-transplant period. Trimethoprim-sulfamethoxazole (TMP-SMX; Septran) had been given briefly in the pre-transplant period but was discontinued as per institutional protocol and was not being administered at the time of symptom onset.

Approximately three months post-transplant, the patient developed upper gastrointestinal GVHD requiring a short course of systemic corticosteroids, which was successfully tapered. Several months later, she presented with persistent left shoulder pain without fever, erythema, or systemic symptoms. Initial management for suspected adhesive capsulitis was unsuccessful.

Magnetic resonance imaging of the left shoulder demonstrated a peripherally enhancing abscess involving the acromioclavicular joint and surrounding musculature, including the supraspinatus and subscapularis regions (Figure 1A). Surgical drainage and debridement were performed.

Histopathological examination of the abscess tissue revealed fibroadipose tissue with extensive haemorrhage and necroinflammatory exudate composed of neutrophils, histiocytes, lymphocytes, occasional eosinophils, and foreign body giant cells. Filamentous, branching Gram-positive bacilli were identified (Figure 1B). Although the initial morphological impression suggested a fungal infection, microbiological analysis using MALDI-TOF mass spectrometry confirmed *N. farcinica*.

Systemic evaluation was undertaken to assess for disseminated disease. Chest computed tomography demonstrated an irregular hypoattenuating lesion in the left upper lobe abutting the mediastinum, along with ground-glass nodules in the right upper lobe, consistent with an infective aetiology. Blood cultures were negative. There was no clinical evidence of central nervous system involvement during the course of illness.

Given the evidence of musculoskeletal and pulmonary involvement in an immunocompromised HSCT recipient, combination antimicrobial therapy with imipenem, amikacin, and TMP-SMX was initiated. TMP-SMX was started at the time pulmonary involvement was identified and continued following microbiological confirmation. Amikacin was discontinued after 45 days due to ototoxicity, while imipenem and TMP-SMX were continued, followed by prolonged oral TMP-SMX therapy for a total treatment duration of one year.

The patient demonstrated progressive clinical improvement with complete radiological resolution of lesions, full functional recovery of the shoulder, and sustained donor chimerism on follow-up.

3. Discussion

This case illustrates disseminated *N. farcinica* infection presenting with prominent musculoskeletal involvement in a late post-HSCT patient. Although pulmonary symptoms were absent initially, chest imaging revealed pulmonary lesions, consistent with the established pathogenesis of nocardiosis involving inhalation followed by haematogenous dissemination[3].

Musculoskeletal involvement is a recognised manifestation of disseminated nocardiosis and does not represent an alternative or unusual pathogenesis[4]. Risk factors in this patient included HSCT, prior corticosteroid exposure, and antithymocyte globulin use.

Combination antimicrobial therapy was selected due to disseminated disease, the known virulence and resistance profile of *N. farcinica*, and the immunocompromised status of the patient. Imipenem and amikacin provide rapid bactericidal activity, while TMP-SMX remains the backbone of therapy for nocardiosis[2,5]. Localised disease may be treated with monotherapy; however, disseminated infection warrants combination treatment.

Although routine central nervous system imaging is generally recommended in immunocompromised patients with nocardiosis because of the risk of asymptomatic involvement, no neurological symptoms were present in this patient. Given that prolonged combination antimicrobial therapy was already indicated for disseminated disease and would not have been altered by imaging findings, central nervous system imaging was not performed. This represents a limitation of the present report[3,6].

Histopathological findings in nocardiosis may mimic fungal infections due to the filamentous morphology of the organism. This case underscores the importance of advanced microbiological techniques such as MALDI-TOF mass spectrometry for definitive diagnosis.

Conflict of interest statement

The authors declare that there are no conflicts of interest related to this manuscript. No material from external published sources has been reproduced, and no additional copyright permissions were required. We hereby transfer, assign, or otherwise convey all copyright ownership, including any and all rights incidental thereto, exclusively to the journal, in the event that such work is published by the journal.

Presentation at a meeting

Presented at Tata Memorial Centre, Mumbai, on 3 March 2025.

Ethical considerations and patient's consent

All images included in this manuscript were obtained from the authors' institution during routine clinical care. The treating physicians are among the authors. All images have been anonymised to protect patient identity. A waiver of patient consent for publication was granted by the Institutional Ethics Committee, as the report relates to retrospective clinical care and contains no identifiable patient information.

Funding

This work did not receive any specific grant from funding agencies in the public, commercial, or not-for-profit sectors.

Authors' contributions

AT, NS, and RJ contributed equally to the conception and design of the case report, data collection and interpretation, literature review, and drafting of the manuscript. MK, SC, GB, SS, KR, ID, and AM contributed to patient evaluation and management and provided critical revision of the manuscript for important intellectual content. All authors reviewed and approved the final version of the manuscript and agree to be accountable for all aspects of the work.

References

[1] Wilson JW. Nocardiosis: Updates and clinical overview. *Mayo Clin Proc* 2012; **87**(4): 403-407.

[2] Brown-Elliott BA, Brown JM, Conville PS, Wallace RJ. Clinical and laboratory features of the *Nocardia* spp. based on current molecular taxonomy. *Clin Microbiol Rev* 2006; **19**(2): 259-282.

[3] Peleg AY, Husain S, Qureshi ZA, Silveira FP, Sarumi M, Shutt KA, et al. Risk factors, clinical characteristics, and outcome of nocardiosis in organ transplant recipients. *Clin Infect Dis* 2007; **44**(10): 1307-1314.

[4] Ambrosioni J, Lew D, Garbino J. Nocardiosis: Updated clinical review and experience at a tertiary centre. *Infection* 2010; **38**(2): 89-97.

[5] Lerner PI. Nocardiosis. *Clin Infect Dis* 1996; **22**(6): 891-905.

[6] Beaman BL, Beaman L. *Nocardia* species: Host-parasite relationships. *Clin Microbiol Rev* 1994; **7**(2): 213-264.

Publisher's note

The Publisher of the *Journal* remains neutral with regard to jurisdictional claims in published maps and institutional affiliations.

Edited by Pan Y, Lei Y, Zhang Q