*Burns & Trauma*, 2022, 10, tkac045
https://doi.org/10.1093/burnst/tkac045
Research Article

OXFORD

Research Article

# Efficacy and safety of external tissue expansion technique in the treatment of soft tissue defects: a systematic review and meta-analysis of outcomes and complication rates

**Xirui Tong[1,2,†], Jianyu Lu[1,2,†], Wei Zhang[1,2,†], Siqiao Wang[3], Runzhi Huang[1,2], Xianliang Zhang[4], Jie Huang[1,2], Yushu Zhu[1,2], Shichu Xiao[1,2,*], Shizhao Ji[1,2,*] and Zhaofan Xia[1,2,*]**

[1]Department of Burn Surgery, the First Affiliated Hospital of Naval Medical University, 168 Changhai Road, Yangpu District, Shanghai, 200433, China, [2]Research Unit of key techniques for treatment of burns and combined burns and trauma injury, Chinese Academy of Medical Sciences, 168 Changhai Road, Yangpu District, Shanghai, 200433, China, [3]Tongji University School of Medicine, Tongji University, Shanghai, 200092, China and [4]Hospital of the 92426 Troops of the Chinese People's Liberation Army, Tsingtao, 266400, China

*Correspondence. Shichu Xiao, Email: huangzhuoxiao4@Hotmail.com; Shizhao Ji, shizhaoji@aliyun.com; Zhaofan Xia, xiazhaofan_smmu@163.com

[†]Joint first authors.

Received 1 May 2022; Revised 26 June 2022; Accepted 7 September 2022

## Abstract

**Background:** Currently, various external tissue expansion devices are becoming widely used. Considering the scarcity of relevant application standards, this systematic review was performed to explore the effectiveness and safety of external tissue expansion techniques for the reconstruction of soft tissue defects.

**Method:** A systematic review and meta-analysis on the efficacy and safety of external tissue expansion technique was conducted. A comprehensive search was performed in the following electronic databases: PubMed/Medline, Embase, Cochrane Library (Wiley Online Library), and Web of Science. Studies reporting patients with soft tissue defects under the treatment of external tissue expansion technique were included.

**Results:** A total of 66 studies with 22 different types of external tissue expansion devices met the inclusion criteria. We performed a descriptive analysis of different kinds of devices. A single-arm meta-analysis was performed to evaluate the efficacy and safety of the external tissue expansion technique for different aetiologies. The pooled mean wound healing time among patients with defects after fasciotomy was 10.548 days [95% confidence interval (CI) = 5.796–15.299]. The pooled median wound healing times of patients with defects after excisional surgery, trauma, chronic ulcers and abdominal defects were 11.218 days (95% CI = 6.183-16.253), 11.561 days (95% CI = 7.062-16.060), 15.956 days (95% CI = 11.916-19.996) and 12.853 days (95% CI=9.444-16.227), respectively. The pooled wound healing rates of patients with defects after fasciotomy, excisional surgery, trauma, chronic ulcers and abdominal defects were 93.8% (95% CI=87.1-98.2%), 97.2% (95%CI=92.2-99.7%), 97.0% (95%CI=91.2-99.8%), 99.5% (95%CI=97.6-100%), and 96.8% (95%CI=79.2-100%), respectively. We performed a subgroup analysis in patients with diabetic ulcers and open abdominal wounds. The pooled median wound healing time of patients with diabetic ulcers was 11.730 days (95% CI = 10.334-13.125). The pooled median wound healing time of patients with open

© The Author(s) 2022. Published by Oxford University Press.
This is an Open Access article distributed under the terms of the Creative Commons Attribution Non-Commercial License (https://creativecommons.org/licenses/by-nc/4.0/), which permits non-commercial re-use, distribution, and reproduction in any medium, provided the original work is properly cited. For commercial re-use, please contact journals.permissions@oup.com



Downloaded from academic.oup.com/burnstrauma/article/doi/10.1093/burnst/tkac045/6887310 by guest on 14 October 2026

abdomen defects was 48.810 days (95% CI = 35.557–62.063) and the pooled successful healing rate was 68.8% (95% CI = 45.9-88.1%). A total of 1686 patients were included, 265 (15.7%) of whom experienced complications. The most common complication was dehiscence ($n = 53$, 3.14%).
**Conclusions:** Our systematic review is the first to demonstrate the efficacy and safety of external tissue expansion in the management of soft tissue defects. However, we must interpret the meta-analysis results with caution considering the limitations of this review. Large-scale randomized controlled trials and long-term follow-up studies are still needed to confirm the effectiveness and evaluate the quality of healing.

**Key words:** External tissue expansion, Systematic review, Meta-analysis, Skin stretching, Soft tissue defects, Wound healing

## Highlights

- This systematic review is the first to comprehensively show the efficacy and safety of external tissue expansion techniques in the management of soft tissue defects.
- A single-arm meta-analysis was performed for different aetiologies of soft tissue defects and the results showed that the pooled wound healing rates of external tissue expansion technique were all over 93% (except in the management of open abdominal defects).
- Among the 55 studies reporting complications, a total of 1686 patients were included, 265 (15.7%) of whom experienced complications. The most common complication was dehiscence (n=53, 3.14%).

## Background

Soft tissue defects following trauma, burns, complications of chronic diseases or surgeries that cannot be primarily closed often cause substantial morbidity and mortality [1]. According to the reconstructive ladder, traditional reconstructive techniques, such as the use of various types of skin grafts, with increasing complexity, are positioned higher up the ladder, which calls for a longer learning period [2]. Moreover, the traditional methods are limited due to their associated blood loss, low cost-effectiveness, functional and aesthetic complications, and the creation of additional wounds (donor sites) [3]. Therefore, surgeons have long been searching for a practical, simple and effective method to achieve wound closure while maintaining aesthetics. The external tissue expansion technique may be a new choice for the reconstruction of skin soft tissue defects with the benefits of simplicity and minimal invasiveness [4].

In 1956, Neuman first incorporated the concept of 'tissue expansion' into practice when he reconstructed auricular defects after 2 months of subcutaneous expansion [5]. Gibson *et al*. described the viscoelastic properties of skin in 1967 [6]. He defined immediate tissue expansion as mechanical creep. With mechanical creep, the collagen fibres are straightened in the direction of the stretching force and displace fluid bound to the extracellular matrix [6]. Continuous mechanical creep will result in biological creep, which describes a physiological process where new tissues are created [6]. Gibson described the phenomenon where the force required to keep skin stretched gradually decreases with stress relaxation. Stress relaxation is a result of creep and occurs when the skin is stretched for a constant distance over time [7]. The exact mechanism by which stretch induces proliferation of new tissue has been further revealed in recent years. At the histological level, researchers found a significant increase in epidermal thickness with dermal thinning during tissue expansion [8,9]. However, several months later, dermal thickness will return to baseline due to the synthesis of fibroblasts after stretching [10]. Histological staining suggests expanded tissue with increased blood vessel density, growth factors and cell proliferation [11,12]. At the cellular level, after tissue expansion, transmembrane mechanosensory signal-activated ion channels, integrins, growth factor receptors and G-protein-coupled receptors translate extracellular signals into intracellular signals in pathways involving calcium, nitric oxide, mitogen-associated protein kinases, Rho GTPases and phosphoinositol-3 kinase [13]. All these signaling pathways converge to activate transcription factors that ultimately upregulate fibroblast mitosis and the synthesis of extracellular matrix proteins. In 2020, Aragona *et al*. first described the mechanisms of stretching-mediated skin expansion at single-cell resolution. Researchers revealed that mechanical strain is communicated by a subpopulation of stem cells that proliferate and promote mechanical resistance and generate extra skin by stretching the skin of mice [14,15].

Based on the mechanisms mentioned above, various external tissue expansion devices have emerged. Unlike internal expansion, external tissue expansion devices are located outside the body and can achieve tissue expansion in two modes: immediate tissue expansion and continuous tissue expansion (Figure 1). During immediate expansion, the forces should be loaded for 4 min, followed by 1 or 2 min of relaxation. Approximately 4–5 cycles of stretching (cycle loading) are subsequently loaded to achieve immediate intraoperative tissue expansion. Hirshowitz *et al*. introduced cyclic loading and demonstrated that it was faster and more effective than continuous stretching for tissue expansion [16]. In 1986, Cohn first described the use of vessel loops in the closure of limb fasciotomy wounds [17]. Several years later, Hirshowitz

Downloaded from academic.oup.com/burnstrauma/article/doi/10.1093/burnst/tkac045/6887310 by guest on 14 October 2026

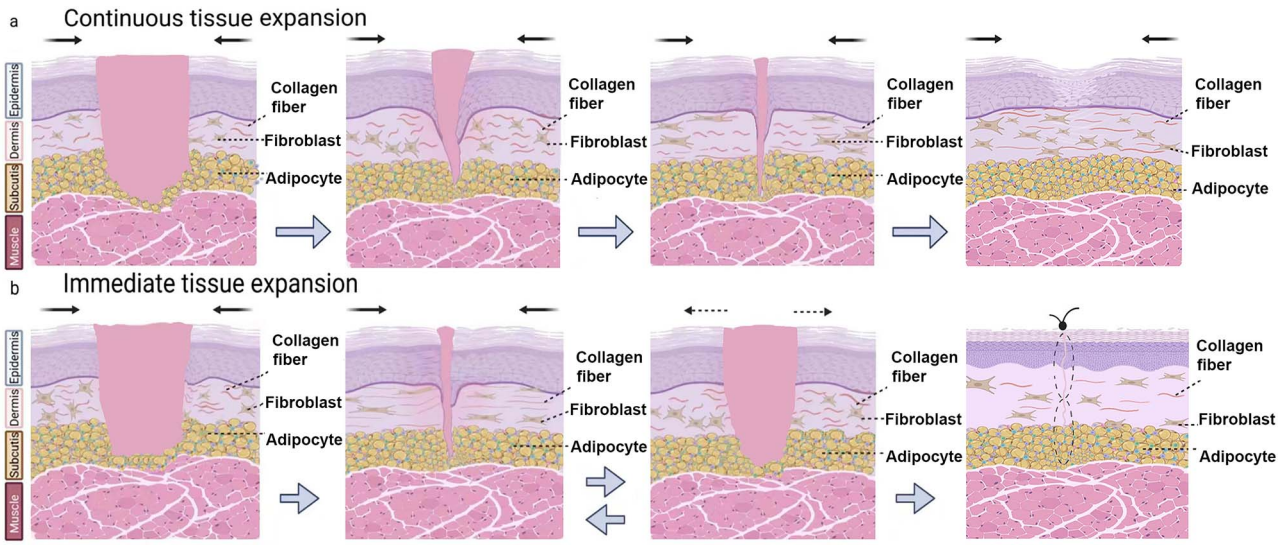


**Figure 1.** Schematic diagram of external tissue expansion technique in two modes. The stretching force is shown with a solid black arrow. During the continuous tissue expansion (**a**), the consistent stretching force induces the straightening and elongation of disorganized collagen fibres which results in reduction of the defect area. Then cellular proliferation leads to wound closure through generation of new tissue. During the immediate tissue expansion (**b**), the stretching force induces reduction of the defect area by straightening and elongation of disorganized collagen fibres. The forces should be loaded for 4 min followed by 1 or 2 min of relaxation (shown with dotted arrow) intraoperatively. After 4-5 cycles of stretching (cycle loading), the collagen fibres are straightened and elongated to the maximum. Combined with a suture technique, soft tissue defects achieve intraoperative closure

*et al*. published the clinical results of 28 patients with a skin-stretching device (SSD) named SureClosure for the first time [18]. Because of its easy application, military doctors used a homemade skin stretching device, which consists of skin clips and rubber bands of assorted sizes, to achieve delayed primary closure of wounds in the Persian Gulf War [19]. More simple and convenient SSDs have emerged and have been commercialized in recent years. However, few large-scale prospective randomized controlled trials (RCTs) can convincingly evaluate the efficiency and safety of external tissue expansion in the treatment of various types of soft tissue defects. Thus, the objective of this paper is to perform a systematic review and meta-analysis of outcomes and complication rates to evaluate the efficacy and safety of external tissue expansion techniques.

## Methods

The methodology and reporting of this systematic review followed the guidelines for Preferred Reporting Items for Systematic Reviews and Meta-Analyses (PRISMA) [20] and was based on the protocol that we set, which defined the search strategy, study selection, data extraction and analysis methods. The protocol was registered with the international prospective register of systematic reviews (CRD42022340736).

### Search strategy

A comprehensive search was performed in the following electronic databases: PubMed, Embase, Cochrane Library (Wiley Online Library) and Web of Science. Free text words were combined with Boolean operators ('OR' and 'NOT') to improve the sensitivity of our search. All relevant studies in English and Chinese were reviewed, with no publication date or publication status restrictions incorporated into the searches. The reference lists of all included studies were also reviewed for other potentially relevant studies and authors' personal collections (grey literature). Duplicate citations were removed in Endnote X9 (Clarivate Analytics, Philadelphia, Pa.). The electronic retrieval strategy is shown in electronic retrieval strategy.

### Study selection

Studies were selected by two reviewers independently, with any discrepancies discussed among the search group. We applied the following inclusion criteria: (1) published or unpublished retrospective and prospective series with or without full texts; (2) studies including patients with soft tissue defects; and (3) studies with external tissue expansion as a main therapy for the closure of soft tissue defects without restricting the type of devices. The exclusion criteria were as follows: (1) repeated studies; (2) non-original studies (reviews, editorials, letters, protocols); (3) case reports or case series with fewer than three patients; (4) studies without sufficient information on primary outcomes; and (5) animal experiments and cell experiments.

### Data extraction

Three independent reviewers evaluated the titles and abstracts and resolved conflicts through discussion and consensus. Full texts were screened to extract all of the data from each eligible

Downloaded from academic.oup.com/burnstrauma/article/doi/10.1093/burnst/tkac045/6887310 by guest on 14 October 2026

study. For all the clinical studies, the following data were extracted: (1) first author; (2) year; (3) research location; (4) study type; (5) the number of cases and defects included; (6) male/female ratio; (7) patient ages; (8) types of external tissue expansion devices; (9) defect aetiologies; (10) defect locations; (11) mode of expansion (immediate or consistent expansion); (12) wound healing time; (13) the number of successful closure wounds; (14) follow-up period; and (15) complications.

### Methodological quality

Although case reports and case series have uncontrolled study designs known to have an increased risk of bias, notably inferences from such reports can be used for decision-making [21]. Since few RCTs were available, we incorporated case reports/series in this systematic review. To better evaluate the methodological quality of case reports/series, the 'Tool for evaluating the methodological quality of case reports and case series' was used [21]. We removed two items related to cases of adverse drug events from the scale. We considered the quality of a record good (high methodological quality) when all 6 criteria were fulfilled, moderate when 4 or 5 were fulfilled, and poor (low methodological quality) when $\leq 3$ were fulfilled. We applied the Cochrane risk-of-bias tool to assess the methodological quality of the included RCTs [22]. For nonrandomized studies, we used the 'Methodological index for nonrandomized studies' (MINORS) tool [23]. No disagreements occurred between the reviewers. All the tools were used in previous publications.

### Outcome definitions

Here, successful wound closure was defined as primary closure or delayed primary closure of a defect without the need for a second intervention. The main outcomes extracted from each clinical study were wound healing time, the total number of patients and the number of patients who achieved successful wound closure. The wound healing time was defined as the time to successful wound closure after device application. Kaplan–Meier survival analysis was used to compute the median healing time if the healing time of each patient was available. The wound healing rate was defined as the percentage of successfully closed wounds in each study population. For the meta-analyses, the means, standard deviations, rates and $p$ values from each study were extracted.

### Statistical analysis

Statistical analysis of the pooled median wound healing time, the mean wound healing time and the healing rate of patients with soft tissue defects treated with external tissue expansion was performed using R package "meta" of Rstudio (A language and environment for statistical computing. R Foundation for Statistical Computing, Vienna, Austria). Any complications reported by the included studies were extracted, and a pooled analysis of complications was performed. The wound healing time was also extracted. Kaplan–Meier survival analysis was used to compute the median healing time by SPSS Statistics 26.0 (IBM, Armonk). Continuous data with a normal distribution are presented as the means and SD. For original data not conforming to a normal distribution, double arcsine transformation was performed to stabilize the variance of the original ratio. Data with a skewed distribution are presented as the medians and ranges. Heterogeneity was assessed by Cochrane's Q chi-square test and the $I^2$ value. The results of the analyses are demonstrated with forest plots. $P < 0.1$ indicated a statistically significant difference. The overall effects of all studies were computed with a random-effects model. $I^2$ values of <40%, 60%, 90% and 100% were considered indicative of minimal, moderate, substantial and considerable heterogeneity, respectively. We investigated potential sources of heterogeneity by subgroup.

## Results

### Search results

We retrieved 4023 references in total, 3992 of which were identified by electronic search and 31 by manual search. Then, 598 duplicates were excluded. After preliminary screening of titles and abstracts, 3425 records were excluded. All the authors assessed the eligibility of 180 full-text papers. A total of 66 studies eventually met the inclusion criteria, including 7 RCTs, 8 non-RCTs and 51 case series. A flow diagram of study selection is shown in Figure 2.

### Study quality

The risk of bias graphs of the included RCTs, non-RCTs and case series are shown in supplementary Figs. 1, 2 and 3, respectively (see online supplementary material). Due to the difficulty of blinding in surgical trials, all included RCTs had a high risk of performance bias (supplementary Figure 1). The quality of the non-RCTs included was generally high, but some articles did not provide sufficient information to assess overall quality (supplementary Figure 2). In terms of case series, 7 records (13.7%) were considered to be of high methodological quality with 6 items of the scale fulfilled, 30 records (58.8%) were considered to be of moderate quality, and 14 records (27.5%) were considered to be of low quality with <3 items fulfilled (supplementary Figure 3, supplementary Table 2, see online supplementary material).

### Characteristics of the included studies and external tissue expansion devices

For a better understanding of the clinical application analysis, a total of 22 kinds of external tissue expansion devices were described in the included studies in detail (Table 1). We classified external tissue expansion devices by attachment method as invasive SSDs and non-invasive SSDs (NSSDs). As mentioned previously, the devices can also be divided into continuous external tissue expanders (CETEs) and instant external tissue expanders according to the expansion mode. The features of the devices and related information are listed

Downloaded from academic.oup.com/burnstrauma/article/doi/10.1093/burnst/tkac045/6887310 by guest on 14 October 2026

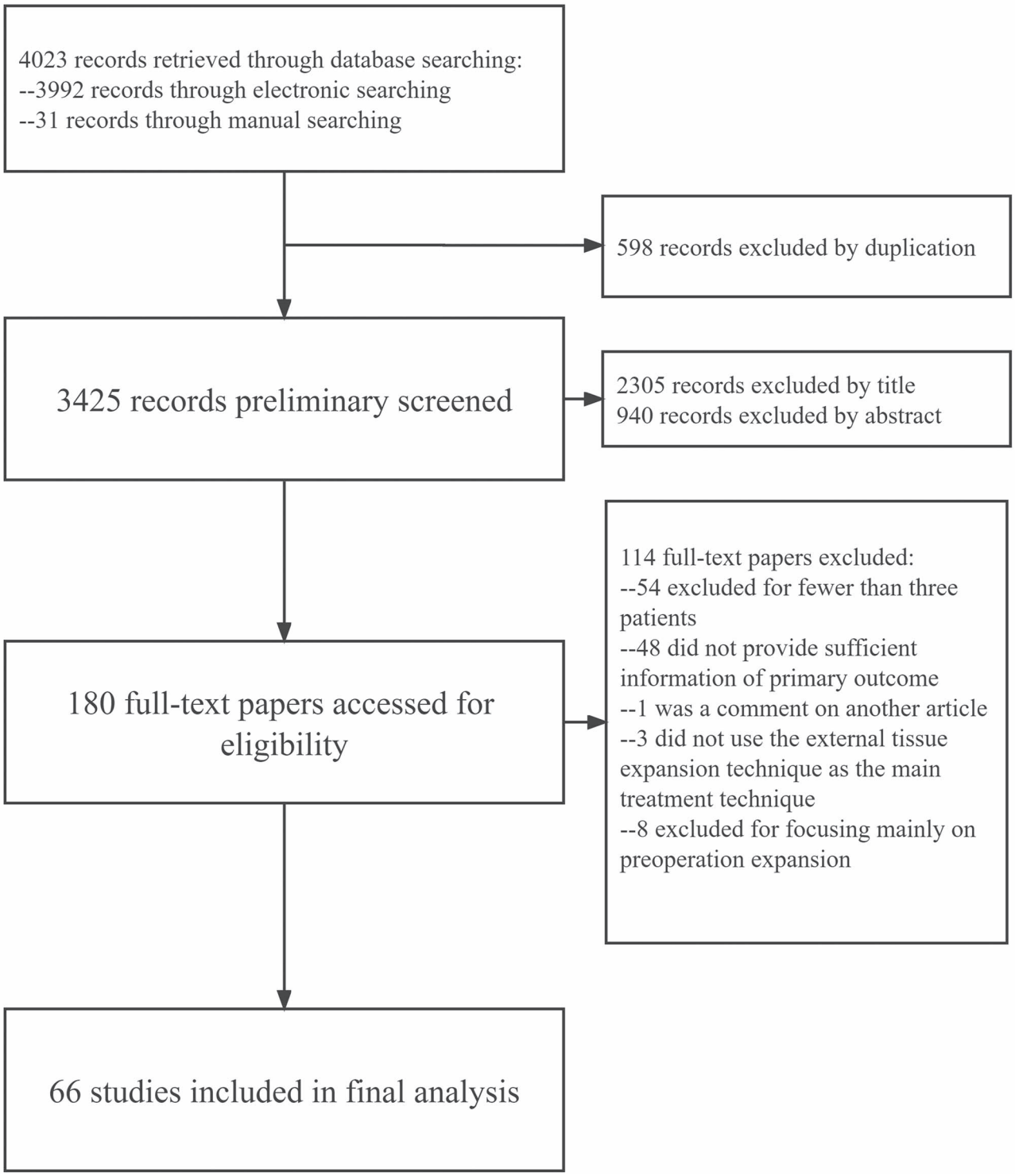


**Figure 2.** Flow diagram of the systematic literature search

in Table 1. The characteristics of all the included clinical trials are listed in supplementary Table 1, see online supplementary material.

Invasive SSDs are more common in medical practice. In all, 57 studies reported 21 different kinds of SSDs most of which were commercial devices that were widely applied in the management of various soft tissue defects. The suture tension adjustment reel device (S.T.A.R., Miami STAR; George Tiemann, Plainview NY, patent pending) was first reported in 1992 but has rarely been reported in the last 10 years. A similar situation was noted for the SureClosure skin-stretching system (Life Medical Science, Princeton, NJ, USA), Ty-raps (Thomas & Betts, Memphis, TN, USA), The Silver Bullet Wound Closure Device (SBWCD, Boehringer

Downloaded from academic.oup.com/burnstrauma/article/doi/10.1093/burnst/tkac045/6887310 by guest on 14 October 2026

**Table 1.** Charascteristics of external tissue expansion devices

| Device | Year/country[a] | Under-mined (Y/N) | Method | Expansion mode (immediate/ continuous)[b] | SSD/ NSSD | Commonly used nowadays (Y/N)[c] | Advantages | Disadvantages |
|---|---|---|---|---|---|---|---|---|
| S.T.A.R. | 1992 America [24] | Y&N | This device consists of an active member (the winder), an inactive member (the stabilizing wrench) and a releasing pin. Active member (with winder) positioned on one side of the wound. Suture should be passed through tissue and device and tied loosely across the holes in the winder. Suture is tightened by rotating the winder by hand. | I & C | SSD | N | An alternative to conventional sutured closures. | Required an estimation of the application force. Needs repeated manual tightening. |
| Vessel loop | 1997 Australia [25] | N | Staples are located along the wound edge parallel to the line of incision at intervals of ~1.5–2 cm. Two elastic vessel loops are stapled at one end of the wound and threaded in shoelace fashion through the staples. | C | SSD | Y | Provides a continuous pull on the skin edges resulting in gradual apposition of wound edges. | Limited expansion for subcutaneous tissue. Requires an estimation of the application force. |
| Sure Closure® | 1995 America [26] | Y&N | Two straight intradermal needles threaded through wound edges. Two U-shaped arms hook onto the needles. | I & C | SSD | N | Has a tension indicator safety mechanism which is used to avoid over-stretching. Simplicity. Undermining is not nessasary. | Needs repeated tightening. |
| Ty-raps | 2010 The Netherland [27] | N | The Ty-Raps are secured to the skin by four surgical staples and tightened every 24–48 h once the swelling has subsided. | C | SSD | N | Cost-effectiveness. | Relatively complex to apply. Needs repeated tightening. |
| SBWCD | 2008 America [28] | N | A 9.5 cm stainless steel instrument that resembles a silver bullet. The SBWCDs are sutured into the wounds with 0 polypropylene sutures in an interrupted fashion and contracts both sides of wound edges by its rotation. | C | SSD | N | Reduces the reconstruction time. | Needs repeated tightening every day. Located in the middle of defects which may increase the risk of infection and metal allergy. |
| Exetnal Tissue Extender | 1996 Norvay [29] | N | Straps inserted through the skin and attached to silicone bars. Straps have a stopper on one side and a one-way locking device on the other. | C | SSD | Y | Maintains the exact tension <3.5 N. | The interjacent skin should be excised before closing. |
| Proxiderm® | 1997 America [30] | N | The device consists of two hooks with a spring mechanism between them attaching to viable tissue near the wound edges. Four models available conforming to the contour of the body part at the wound site. | I & C | SSD | N | Maintains a constant tension <460 g. The four models differ in radians and sizes: the slightly curved one for relatively flat surfaces, the 90° one for right-angled structures such as the heel, a 180° model for the foot and a slightly curved model for large wounds. | Relatively complex to apply. Generally applied for periods of <2 days at a time. |

(*Continued*)

Downloaded from academic.oup.com/burnstrauma/article/doi/10.1093/burnstt/tkac045/6887310 by guest on 14 October 2026

**Table 1.** Continued

| Device | Year/country[a] | Undermined (Y/N) | Method | Expansion mode (immediate/ continuous)[b] | SSD/ NSSD | Commonly used nowadays (Y/N)[c] | Advantages | Disadvantages |
|---|---|---|---|---|---|---|---|---|
| Wisebands® | 2004 Israel [31] | N | The surgical needle and its band are inserted through the wound edges going down to the severed soft tissue. The tension feedback control device holds the band and controls the tension under 1 kg/cm$^2$. | I & C | SSD | N | Whenever the tension exceeds the standard, the feedback control mechanism will relax and remain at the last position.<br>Simplicity. Stretch skin and subcutaneous tissue at the same time. | Increase the risk of infection and pain. |
| DermaClose® | 2012 America [32] | Y | One controller and skin anchors should be placed per 10 cm wound length and secured with staples after wound edges undermined. The tension controller is then turned clockwise. | C | SSD | Y | Simplicity and easy to apply.<br>Maintains the constant tension <11.7 N.<br>With advantages in treating longstanding open defects. | Undermining is necessary.<br>Less cost-effectiveness. |
| TopClosure® | 2012 Israel [33] | N | Two flexible polymer attachment plates (AP) are attached to skin and a long, flexible approximation strap (AS) runs through the APs. | I & C | SSD/NSSD | Y | Non-invasive and invasive manner are both available. | Limited capacity for subcutaneous tissue. Needs repeated tightening. |
| ABRA | 2003 Canada [34] | Y | Bands are embedded through the skin and secured with skin anchors on either side of the defect. | C | SSD | Y | Moves dynamically applying a constant and cyclic expansion.<br>Bands are marked to estimate the force. | Relatively complex to apply.<br>Undermining is necessary.<br>Needs repeated tightening. |
| EASApprox® | 2020 China [35] | N | Consists of special hooked needles and a tension indicator. The tension indicator has three markers which represent the stretching tension of 5, 15 and 30 N, respectively. | I & C | SSD | N | With advantages in treating relatively large defects. | Damage to wound edges cannot be ignored. |
| Zip® | 2002 Norway [36] | N | Two polyurethane strips and a hydrocolloid pressure-sensitive skin adhesive. | C | NSSD | Y | Simplicity.<br>An effective alternative to intracutaneous suture and skin staple. | Limited expansion capacity. |
| Medical tape | 2018 China [37] | N | The Medical tapes (Henan Huibo Medical Co., China) are applied across the wound to apply continuous tension. The average horizontal tension provided by the medical tape needs to be ≥1 N per 1 cm of width. | C | NSSD | N | Non-invasive and cost-effectiveness.<br>Simplicity. | Limited expansion capacity.<br>Medical tapes must be regularly changed to maintain continuous traction. |
| Nice knots | 2020 China [2] | N | The No. 1 MERSILK nonabsorbable sutures (ETHICON, Johnson & Johnson, USA) were folded into double strands. The skin margin was interruptedly sutured with an edge distance of 1–2 cm and a needle distance of 1–1.5 cm. The suture was passed around the tissues to be fixed and tightened with the nice knot. | I & C | SSD | N | Simplicity.<br>Cost-effectiveness.<br>With advantages in treating small- or medium-sized defects. | Limited expansion capacity. |

(*Continued*)

Downloaded from academic.oup.com/burnstrauma/article/doi/10.1093/burnstt/tkac045/6887310 by guest on 14 October 2026

**Table 1.** Continued

| Device | Year/country[a] | Undermined (Y/N) | Method | Expansion mode (immediate/ continuous)[b] | SSD/ NSSD | Commonly used nowadays (Y/N)[c] | Advantages | Disadvantages |
|---|---|---|---|---|---|---|---|---|
| Rubber bands/elastic bands | 2017 China [38] | Y&N | RBs (DeRoyal Industries Inc, Powell, TN, USA) are applied to the skin edges of the wound apex using staples placed perpendicularly to the wound. The bands are progressively advanced and secured with staples at 3–4 mm intervals by twisting back-and-forth to create a criss-cross pattern. | C | SSD | N | Simplicity<br>Cost-effectiveness. | Limited expansion for subcutaneous tissue. |
| Transfusers+ Nylon ligature stripes | 2018 China [39] | N | Transfusers are attached to the skin edges. Nylon ligature strips are inserted into the tube through skin and subcutaneous tissue from the opposite site. | C | SSD | N | Simplicity<br>Cost-effectiveness. | Damage to wound edges cannot be ignored. |
| Loop suture | 2004 Korea [40] | Y | A 0 –1 nylon suture is threaded through the deep dermis across the defect and both ends of the suture are tied to form a loop, which is secured on two holes at one end of the plastic strip. The plastic strip is pulled through the hollow plastic cylinder gradually to approximate the wound margin. | I & C | SSD | N | Cost-effectiveness. | Adequate undermining is needed. Requires an estimation of the application force. |
| KWs + Wires | 2018 China [41] | N | KWs are inserted intradermally 1 cm from the skin edge, parallel to the side of the wound. A wire is attached to KWs and tightened to approximate the wound edges. | C | SSD | N | Cost-effectiveness. | Damage to wound edges.<br>Requires an estimation of the application force. |
| KWs + BHS® | 2020 China [42] | N | KWs are inserted into the skin and subcutaneous tissue ~1 cm away from wound margins. Two hook-holder modules are placed on the KWs bridges (or the skin and subcutaneous tissue directly) by using hooks. | C | SSD | N | With advantages in treating relatively large defects. | Relatively complex to apply.<br>Damage to wound edges.<br>Patients need to approximate the wound edges one to two times per day by themselves.<br>Requires an estimation of the application force. |
| KWs + KeKe® | 2021 China [43] | N | KWs are inserted parallel to the side of the wound. A modified skin-stretching device (two hooks locked by a stabilizing wrench) is placed on the KWs. | C | SSD | N | With advantages in treating relatively large defects. | Relatively complex to apply.<br>Damage to wound edges.<br>Required an estimation of the application force. |
| KWs + External fixators | 1998 England [44] | N | A Kirschner wire is inserted, 1.8 mm in diameter, intradermally 1 cm from the skin edge, parallel to the side of the wound. A wire is attached to hook wires which are gripped by the slotted threaded rods incorporated into the Ilizarov circular frame. | C | SSD | N | With advantages in treating skin defects combined with fractures. | Relatively complex to apply.<br>Damage to wound edges.<br>Patients need to apply traction to the wires by advancing hexagonal nuts with spanners. Requires an estimation of the application force. |

*NSSD* non-invasive skin stretching device, *SSD* skin stretching device

[a]Publication year and country of the first study which was included in this review [b]Expansion mode: I, immediate tissue expansion; C, continuous tissue expansion [c]Commonly used nowadays: Y, yes, i.e. there were ≥ 3 studies in the last 10 years. N, no, i.e. there were <3 studies in the last 10 years

Downloaded from academic.oup.com/burnstrauma/article/doi/10.1093/burnstt/tkac045/6887310 by guest on 14 October 2026

Laboratories, Norristown, PA, USA), Proxiderm® (Proxiderm Model TN460, Progressive Surgical Products, Westbury, NY) and Wisebands®. In contrast, more studies have reported on DermaClose® RC (Wound Care Technologies, Inc. Chanhassen, MN, USA), the ABRA® Dynamic Wound Closure System (Canica Design Inc, Almonte, Canada) and TopClosure (TopClosure® Tension Relief System, IVT Medical Ltd Ra'anana, Israel), among others, in recent years. Some homemade SSDs have also been reported in addition to commercial external devices. For example, combinations of nice knots and Kirschner wires (KWs) or elastic dressings have been successfully used in the closure of small- and medium-sized soft tissue defects [2,45]. The combinations of KWs and silk thread or wires were also reported in the management of various types of soft tissue defects [41,46]. We grouped the devices that were combined with KWs for a better description in this review. The combination of rubber bands and skin staples could also be used as a SSD [38,47]. The elastic bands from #7 surgical gloves may also be good choices [48]. Chen and Su reported a combination of a transfuser and nylon ligatures with a similar composition to ETEs [39]. Lee designed a wound closure device consisting of a hollow soft transparent plastic cylinder, a flat rigid plastic strip and a plastic cushion [40]. In combination with loop sutures, the homemade device achieved encouraging results in the management of soft tissue defects [40].

Non-invasive tissue expansion devices, also called 'traction-assisted dermatogenesis' devices, have advantages in their simple application, cost efficacy and non-invasiveness [49]. As we focused on the patients with soft tissue defects, the application of Zip® and TopClosure® will be discussed in detail in the following section. Notably, TopClosure® could be applied in both invasive mode and non-invasive mode [33]. Nine studies reporting the application of non-invasive tissue expansion devices were included in this systematic review.

## Clinical application

**Fasciotomy** Among all the studies included, 20 reported using the external tissue expansion technique in 209 patients undergoing fasciotomies. The application devices included a vessel loop [50–53], SureClosure® [54], Ty-raps [27], SBWCD [28], ETEs [29,55], Wisebands® [56], DermaClose® [57], TopClosure® [33,58], ABRA® [34,59], EASApprox® [60] and homemade devices [40,41,47,48].

Only three studies including 53 patients met the inclusion criteria for the meta-analysis [28,51,52]. Two of these studies were RCTs and the other was a case series. The pooled mean wound healing time following fasciotomy combined with the external expansion technique was 10.548 days [95% confidence interval (CI) = 5.796-15.299], with considerably high inter-study heterogeneity ($I^2$ = 98%, $p$ <0.01) (Figure 3a). Considering the diversity of the control groups, we conducted a crude comparison of the mean wound closure times with split skin grafting previously reported in fasciotomy-related literature. According to a previous study, the mean closure time of split-thickness skin graft (STSG) in the management of upper-extremity fasciotomy was 15.6 days [28]. The external tissue expansion technique reduces the wound closure time of fasciotomies and may be an alternative to skin grafts and skin flaps.

A total of 15 studies were included in the meta-analysis of the successful wound closure rate [27,28,33,34,40,47,50–53,55–59]. The pooled wound closure rate among patients undergoing fasciotomy was 93.8% (87.1-98.2%, $I^2$=54%, $p$<0.01) (Figure 3b).

**Post-excisional soft tissue defects** Resection of enlarging masses, keloid scars, giant naevi or burn scabs and large free-flap donor sites will result in soft tissue defects that cannot be closed primarily and thus require skin grafts. A total of 28 studies reported the utility of the external tissue expansion technique among 270 patients with post-excisional soft tissue defects. The S.T.A.R. device [24], SureClosure® [26,54,61–66], ETEs [67], Proxiderm® [68,69], Wisebands® [31], DermaClose® [32,57,70], TopClosure® [33,58,60,71], BHS® (bidirectional regulation hook skin closure system) [42] and some homemade devices [2,38–40,72–75] were applied. In all, 5 studies reported intraoperative primary closure of 41 defects with the SureClosure® [26,61–63] and Proxiderm® [68] devices. All the defects were closed after cyclic stretching during surgery. Our meta-analysis mainly focused on delayed primary closure.

Only 3 retrospective studies with 28 patients met the inclusion criteria for the meta-analysis [2,32,38]. Kaplan–Meier survival analysis was used to analyse the median healing time. The pooled median wound healing time was 11.218 days (95% CI = 6.183-16.253, $I^2$=86.0%, $p$<0.01) (Figure 4a). The heterogeneity was substantial.

A total of 15 studies were included in the meta-analysis of the successful wound closure rate [24,26,32,33,38,57,58,61–63,65,67–70]. The pooled wound closure rate among patients with post-excisional defects was 97.2% (95% CI = 92.2-99.7%, $I^2$=36%, $p$=0.08) (Figure 4b).

**Trauma** High-energy injuries often result in severe soft tissue defects usually combined with bone injuries [76]. A total of 22 retrospective studies included 215 patients with soft tissue defects after trauma. The wounds were mainly located in the extremities and trunks. The devices used for reconstruction of the posttraumatic defects included the vessel loop [25], SureClosure® [26,54], ETEs [55], Proxiderm® [30,69], Wisebands® [31], DermaClose® [57,77], TopClosure® [33,58,76], EASApprox® [60], KeKe® [43,75] and some homemade devices, such as nice knots [2], rubber bands [48] and KWs [[41,46],[72–74]].

Seven retrospective studies met the inclusion criteria for the meta-analysis of the median healing time of posttraumatic defects [2,25,30,57,69,72,76]. Kaplan–Meier survival analysis was used to analyse the median healing time. The pooled median wound closure time was 11.561 days (95%

Downloaded from academic.oup.com/burnstrauma/article/doi/10.1093/burnst/tkac045/6887310 by guest on 14 October 2026

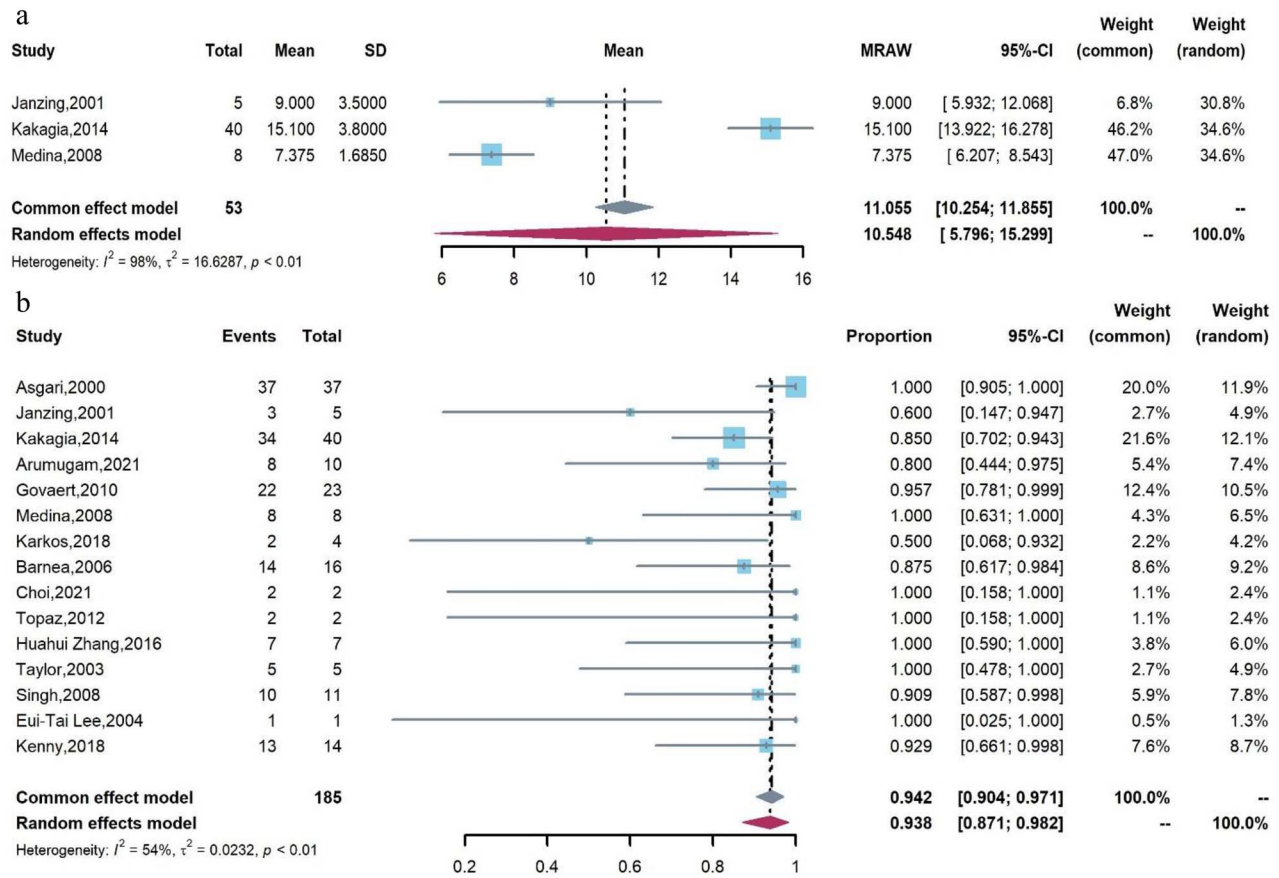


**Figure 3.** Forest plot of single-arm meta-analysis showing pooled mean wound healing time (**a**) and wound healing rate (**b**) in the patients undergoing fasciotomies. MRAW (Mean RAW) identifies a summary measure which is used for pooling of studies in R studio. DL represents the random effects model (D+L). IV represents the fixed effects model (I-V). Weights are from random effects analysis here. *ES* effect size, *CI* confidence interval, *SD* standard deviation

CI = 7.062-16.060), with a substantial level of interstudy heterogeneity ($I^2$ = 88%, $p$ <0.01). (Figure 5a).

Sixteen retrospective studies met the inclusion criteria for the meta-analysis of successful wound closure rate [2,25,26,30,31,33,39,46,54,55,57,69,72,74–76]. The pooled wound closure rate among patients with posttraumatic defects was 97.0% (95% CI = 91.2-99.8%, $I^2$ = 31%, $p$ = 0.12). (Figure 5b).

**Chronic ulcers** Some soft tissue defects can occur secondary to infection or chronic diseases, such as diabetes, vascular diseases or collagen diseases. The pathologies in the enrolled studies included diabetes, vascular diseases, collagen diseases, pressure sores and chronic nonhealing postoperative defects. Twenty studies with 325 patients with chronic ulcers were enrolled in the final analysis. The application devices included SureClosure® [26,78], Proxiderm® [30,69,79], Wisebands® [31], DermaClose® [57], TopClosure® [33,58], ABRA® [80], EASApprox® [35], NSSDs [37,81], loop suture [40] and homemade devices [38,39,47,48,72].

Nine studies met the inclusion criteria for the meta-analysis of the median healing time of chronic defects [30,37,38,40,57,69,72,80,81]. The nine studies consisted of seven retrospective studies and two cohort studies. Kaplan–Meier survival analysis was used to calculate the median healing time. The pooled median wound closure time was 15.956 days (95% CI = 11.916–19.996), with a high level of interstudy heterogeneity ($I^2$ = 95%, $p$ <0.01) (Figure 6a). We performed a subgroup meta-analysis of patients with diabetic foot ulcers. Two cohort studies and one retrospective study were included [30,38,72]. The pooled median wound closure time was 11.73 days (95% CI = 10.334-13.125), with lower interstudy heterogeneity ($I^2$ = 0%, $p$ = 0.54) (Figure 6c). We determined that defect aetiologies contributed to the wide variability in outcomes.

Fourteen studies met the inclusion criteria for the meta-analysis of the successful wound closure rate [26,30,33,35,38–40,47,48,57,58,72,79,80]. The pooled successful wound closure rate was 99.5% (95% CI = 97.6–100%, $I^2$ = 11%, $p$ = 0.34) (Figure 6b).

**Abdominal defects** Considering the particularity of abdominal defects, we analysed the effectiveness of external tissue expansion in the management of abdominal defects separately. The defects were divided into abdominal wall defects and open abdominal wounds. Abdominal wall defects

Downloaded from academic.oup.com/burnstrauma/article/doi/10.1093/burnst/tkac045/6887310 by guest on 14 October 2026

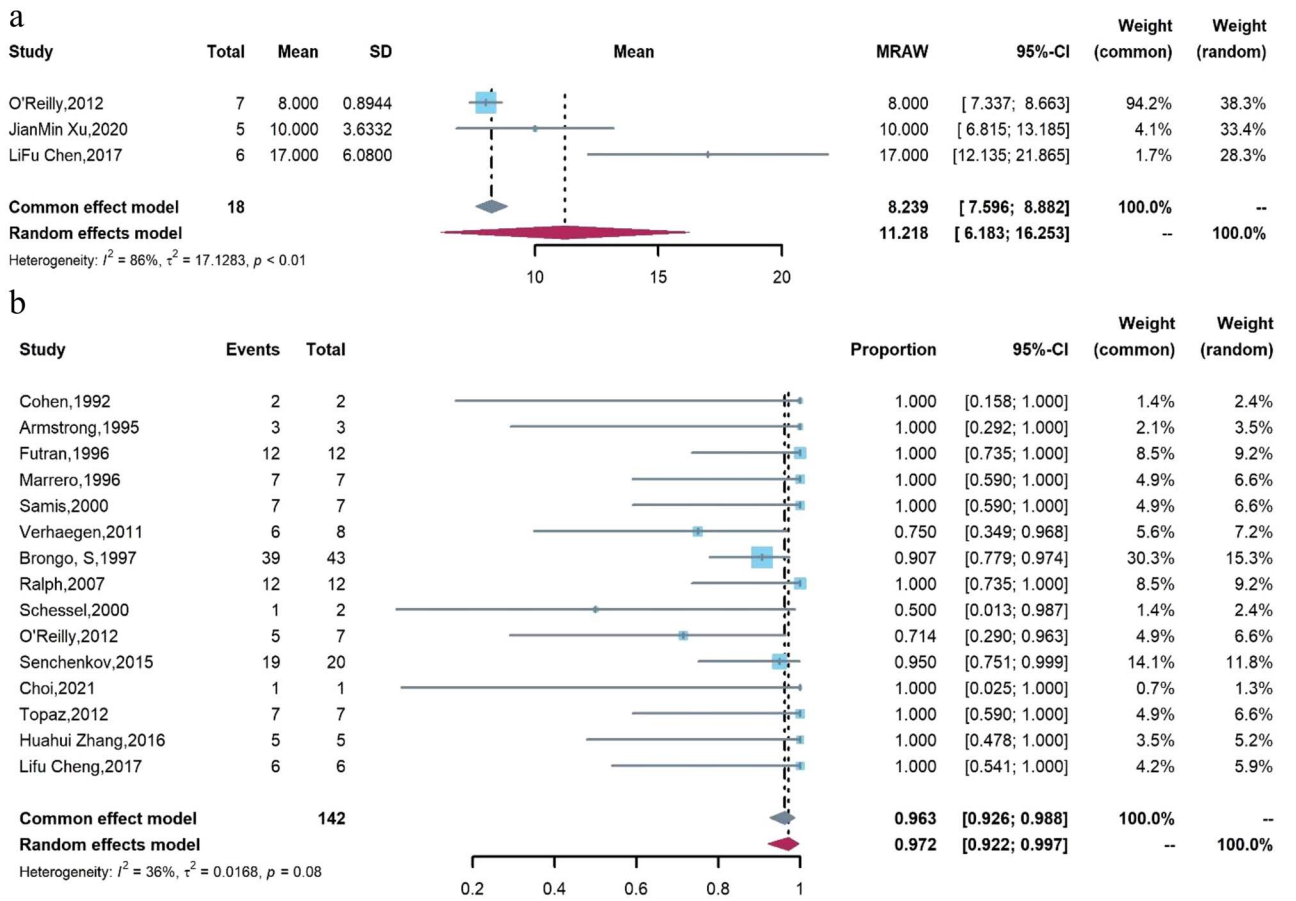


**Figure 4.** Forest plot of single-arm meta-analysis showing pooled median wound healing time (**a**) and wound healing rate (**b**) in the patients with post-excisional defects. DL represents the random effects model (D+L). IV represents the fixed effects model (I-V). Weights are from random effects analysis here. *CI* confidence interval, *SD* standard deviation

are often caused by infection or dehiscence of post-operative incisions without involving the full-thickness abdominal wall. Five retrospective studies reported the application of TopClosure® [82], KeKe® [75], Proxiderm® [30] and homemade devices, such as rubber bands [38] and nice knots [2], in 24 patients. Four retrospective studies met the inclusion criteria for the meta-analysis of the mean healing time of abdominal wall defects [30,38,75,82]. The pooled median wound closure time was 12.853 days (95% CI = 9.444-16.227, $I^2$ = 72%, $p$ = 0.01) (Figure 7a). All five retrospective studies met the inclusion criteria for the meta-analysis of the mean healing time of abdominal wall defects. The pooled successful healing rate was 96.8% (95% CI = 79.2–100%, $I^2$ = 33%, $p$ = 0.20) (Figure 7b).

Open abdominal wounds often occur secondary to damage control laparotomy, which increases the number of surviving patients [83]. The ABRA® Dynamic Wound Closure System (Canica Design Inc, Almonte, Canada) is an adhesive elastic device indicated for controlling, reducing or closing retracted soft tissue wounds. Two retrospective studies with 30 patients treated with ABRA® devices met the inclusion criteria for the meta-analysis of the median healing time of open abdominal wounds [83,84]. Kaplan–Meier survival analysis was used to calculate the median healing time. The pooled median wound closure time was 48.81 days (95% CI = 35.557–62.063, $I^2$ = 73%, $p$ = 0.05) (Figure 8a). The pooled successful healing rate was 68.8% (95% CI = 45.9-88.1%, $I^2$=22%, $p$=0.26); (Figure 8b). Compared with the healing rate shown above, the successful healing rate of open abdominal wounds was relatively low. The external tissue expansion technique was substituted for sutures, staples, skin grafts or skin flaps in the above studies. However, we applied the dynamic wound closure device as closure therapy to achieve delayed closure of the open abdomen. If closure of the open abdomen cannot be achieved, some complications, such as sequela-like large abdominal wall defects, enterocutaneous fistulas and ventral hernias, are common [85]. Considering the complexity of open abdominal defects, the reason for the lower healing rate can be easily understood.

**Other indications** NSSDs have been demonstrated to be an effective and safe alternative to intracutaneous sutures and skin staples [36,86,87]. The Zip® Surgical Skin Closure device (ZipLine Medical, Inc., Campbell, CA, USA) is commonly used for the final layer in skin closure [88]. The

Downloaded from academic.oup.com/burnstrauma/article/doi/10.1093/burnst/tkac045/6887310 by guest on 14 October 2026

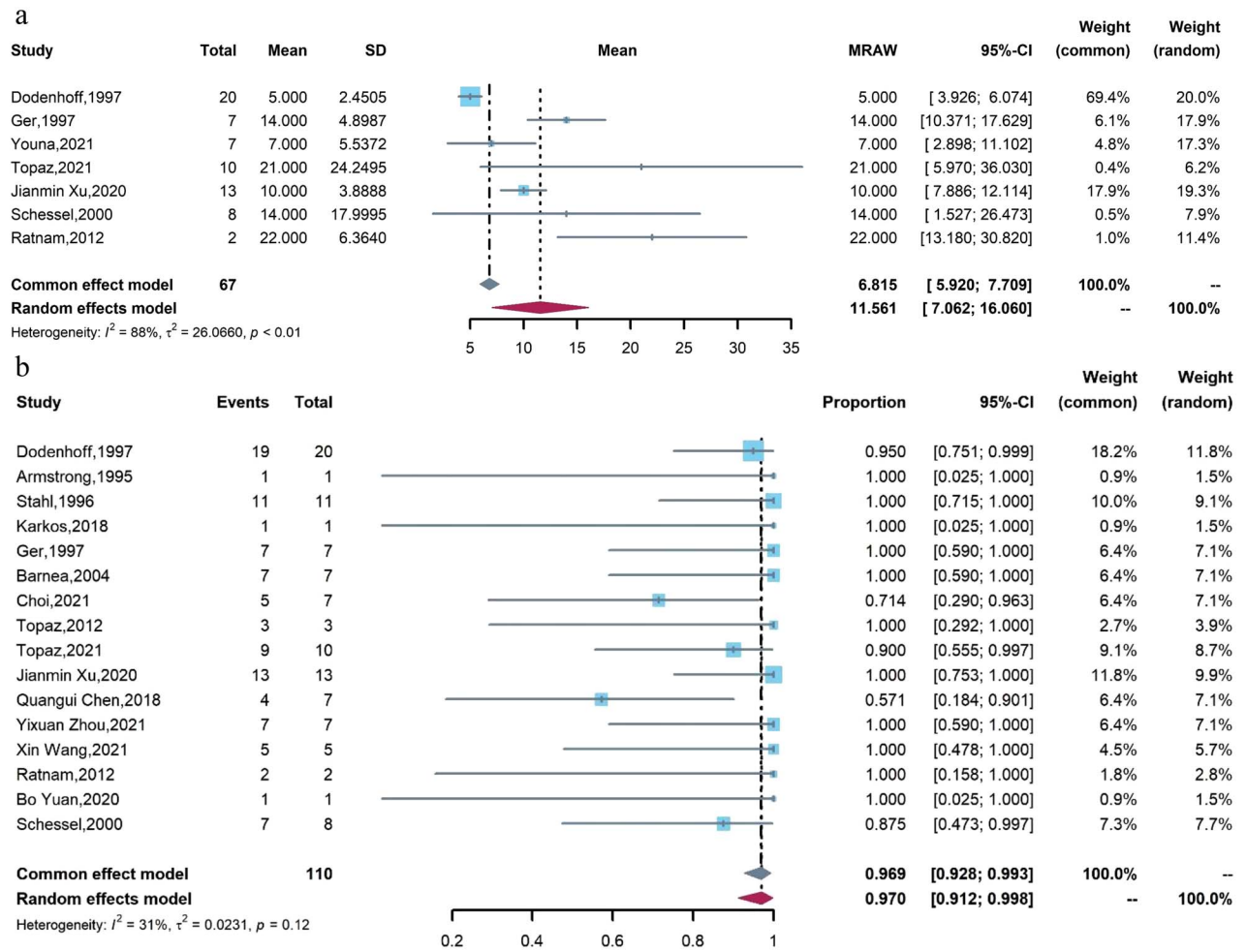


**Figure 5.** Forest plot of single-arm meta-analysis showing pooled median wound healing time (**a**) and wound healing rate (**b**) in the patients with post-traumatic defects. DL represents the random effects model (D+L). IV represents the fixed effects model (I-V). Weights are from random effects analysis here. *CI* confidence interval, *SD* standard deviation

zipper closure device was demonstrated to be a safe choice with a lower infection rate, better cosmetic results and a shorter wound closure time compared with intracutaneous suture [36,86,87]. Carli *et al*. demonstrated that the zipper closure device could prevent the need for home care and result in fewer complications than staples [89]. Menkowitz *et al*. demonstrated that the zipper closure device achieved better patient satisfaction and cosmetic outcomes than staples [90]. Eight studies conducted descriptive analyses, including five high-quality RCTs. Zip surgical skin closure is widely used as the final step in coronary artery bypass grafting, orthopaedic surgery, total knee arthroplasty and cardiac implantable electronic device pocket closure [36,86,87,89–93]. An inexpensive and nontraumatic elastic adhesive tape (DynaClose®; Canica Design Inc. Almonte, Ontario, Canada) is another kind of dynamic wound closure technique similar to the ABRA® series. DynaClose was also reported as an alternative to punch biopsy site closure [94]. Doumit *et al*. [92] reported a case where DynaClose was used as an alternative to sutures to close a biopsy site. The outcome showed that DynaClose may be a cost-effective and simple alternative to sutures. Some studies reported the application of NSSDs for preoperative expansion [49,95,96]. The results were encouraging and they demonstrated that the technique was simple and cost-effective and could also simultaneously improve cosmetic outcomes. Since we focused on the management of soft tissue defects, we will not extend the description of preoperative tissue expansion.

**Complications** Among the included studies, 8 studies reported no complications, 11 studies did not discuss complications and 47 studies reported complications following the external tissue expansion technique (supplementary Table 1). Among the 55 studies reporting complications (complications or no complications), a total of 1686 patients were included, 265 of whom (15.7%) experienced complications. The most commonly reported complication was dehiscence ($n = 53$) and the complication rate was 3.14% (Table 2). Other important complications included hypertrophic scars ($n = 51$, 3.02%), infection ($n = 37$, 2.19%), intense pain ($n = 26$, 1.54%)

Downloaded from academic.oup.com/burnstrauma/article/doi/10.1093/burnst/tkac045/6887310 by guest on 14 October 2026

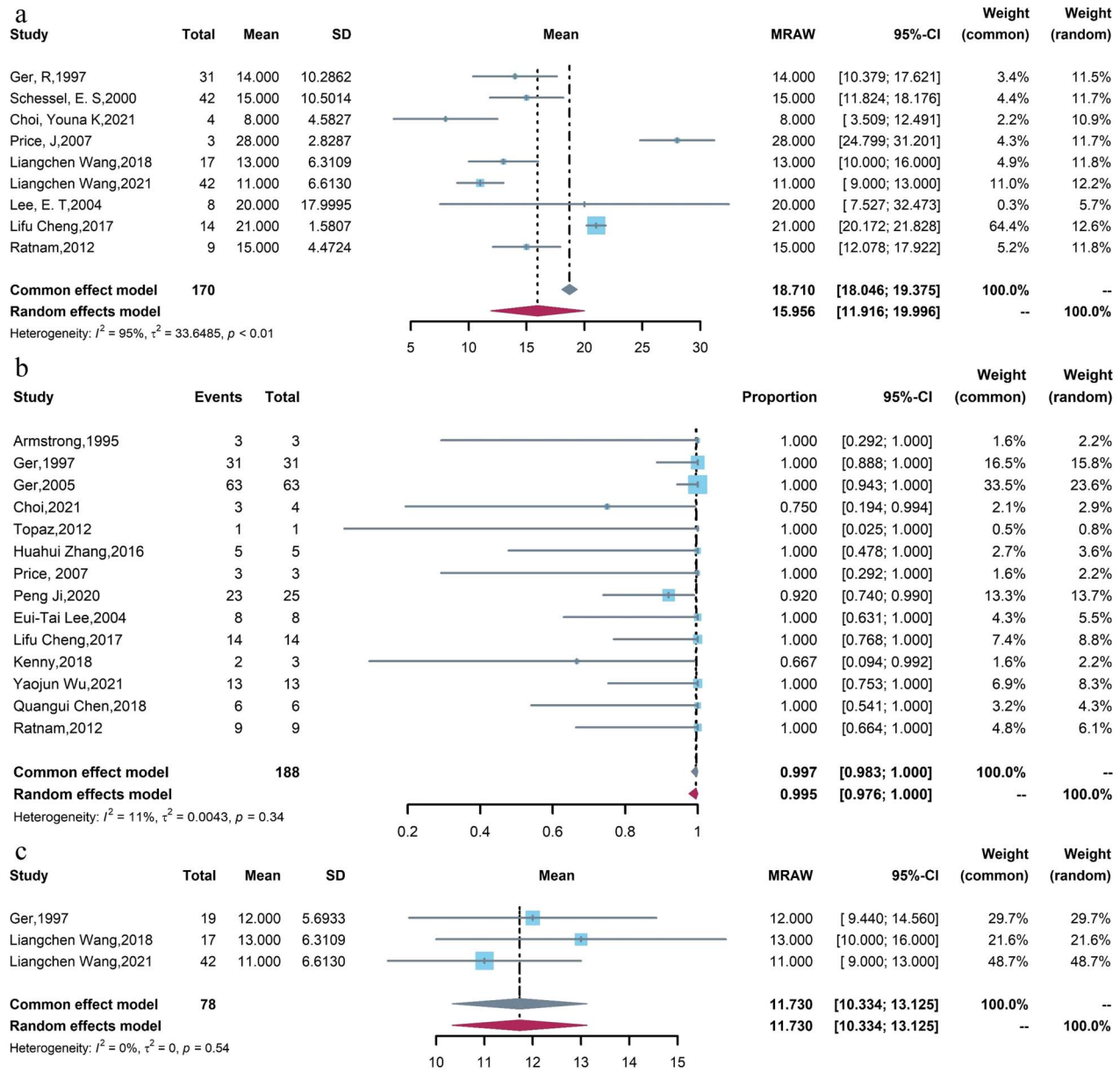


**Figure 6.** Forest plot of single-arm meta-analysis showing pooled median wound healing time (**a**) and wound healing rate (**b**) in the patients with chronic ulcers. Forest plot of pooled median wound healing time (**c**) in the patients with diabetes foot ulcers. DL represents the random effects model (D+L). IV represents the fixed effects model (I-V). Weights are from random effects analysis here. *CI* confidence interval, *SD* standard deviation

and skin necrosis ($n = 21$, 1.25%). Several complications were reported, including skin hypersensitivity, bullae or blisters, hernia, device exfoliation, protruding sutures, skin numbness, skin cutting, maceration, patient noncompliance, enterocutaneous fistulization, allergy, ischaemia, haematoma, skin discolouration, epidermolysis and erythema. Notably, some complications are disease specific. For example, hernia is a complication that specifically occurs in open abdominal wounds and the complication rate among patients with open abdominal wounds was 26.7%. Skin cutting occurred specifically in patients treated with the devices compromised of surgical sutures.

## Discussion

We conducted a systematic review to describe the clinical application of the external tissue expansion technique. The results are in line with those of previous studies showing that the external tissue expansion technique is an effective and safe method for the management of soft tissue defects. Our systematic review is the first to demonstrate the efficacy and safety of external tissue expansion in the management of soft tissue defects.

Most of the included trials were retrospective studies. A total of 23 external tissue expansion devices were included in the review. Various soft tissue defects caused by fasciotomy,

Downloaded from academic.oup.com/burnstrauma/article/doi/10.1093/burnst/tkac045/6887310 by guest on 14 October 2026

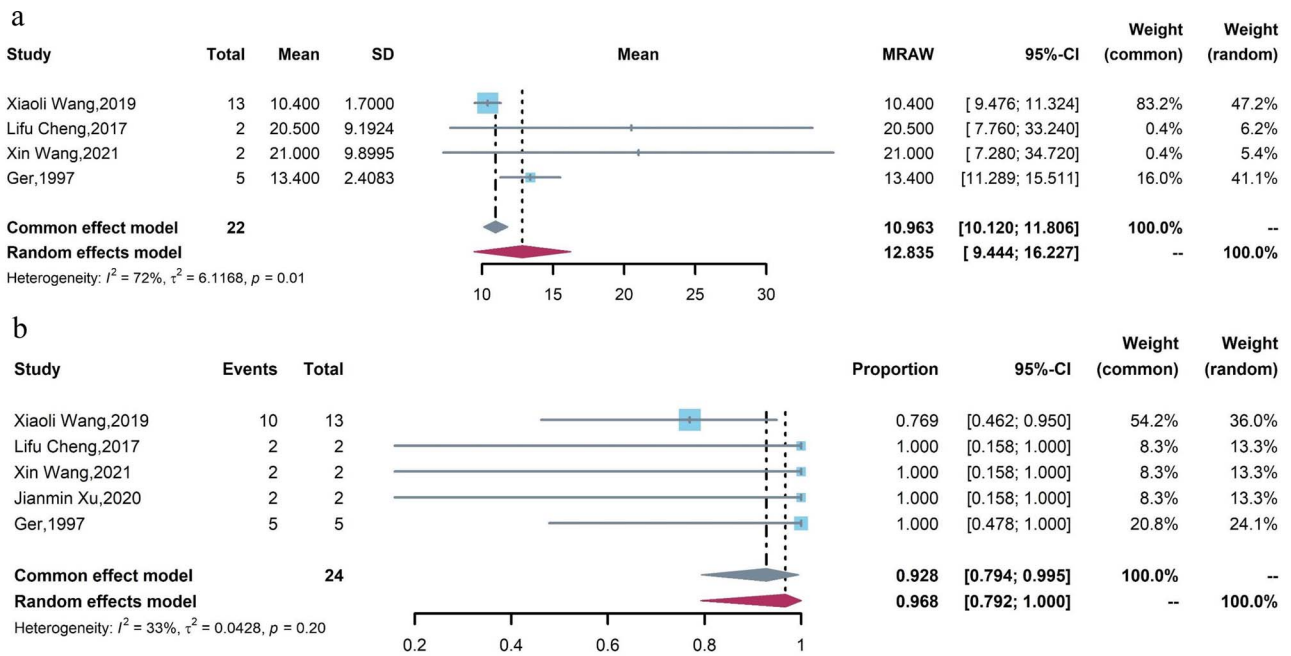


**Figure 7.** Forest plot of single-arm meta-analysis showing pooled median wound healing time (**a**) and wound healing rate (**b**) in the patients with abdominal wall defects. DL represents the random effects model (D+L). IV represents the fixed effects model (I-V). Weights are from random effects analysis here. *CI* confidence interval, *SD* standard deviation

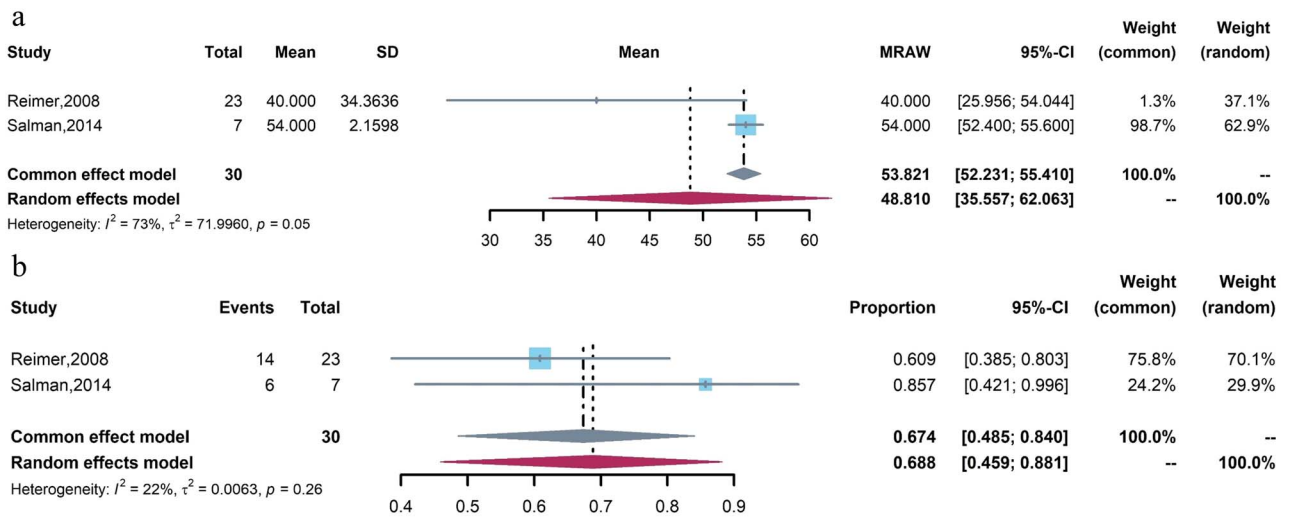


**Figure 8.** Forest plot of single-arm meta-analysis showing pooled median wound healing time (**a**) and wound healing rate (**b**) in the patients with open abdominal wounds. DL represents the random effects model (D+L). IV represents the fixed effects model (I-V). Weights are from random effects analysis here. *CI* confidence interval, *SD* standard deviation

mass resection, scar resection with large flap donor sites, trauma, chronic ulcers, abdominal defects and surgery achieved primary closure with the external tissue expansion technique.

Although both our qualitative systematic review and qualitative meta-analysis showed the efficacy and safety of external tissue expansion devices, wide variability was noted in the results. Many related factors resulted in heterogeneity. The first factor likely contributing to this wide variability in outcomes is the diversity among different devices. All the devices are based on the same principle, but their compositions and operation differ. Some devices may be more effective than others. Moreover, the external tissue expansion technique corresponds to a rapidly evolving field, and different organizations and surgeons may perform the technique with different variations, which may contribute to this wide variability in outcomes. Additionally, the viscoelastic property of skin varies in different body locations. For example, in patients undergoing fasciotomy, the wound healing time differed between the upper extremities and lower extremities. However, defects in the same locations or with the same inducing factor are difficult for us to group. Furthermore, concomitant diseases

Downloaded from academic.oup.com/burnstrauma/article/doi/10.1093/burnst/tkac045/6887310 by guest on 14 October 2026

**Table 2.** Overall complications associated with external tissue expansion technique

| Complications | No. of studies | No. of participants with complications | Complication rate |
|---|---|---|---|
| Dehiscence | 18 | 53 | 0.0314 |
| Scar | 11 | 51 | 0.0302 |
| Infection | 13 | 37 | 0.0219 |
| Pain | 6 | 26 | 0.0154 |
| Necrosis | 6 | 21 | 0.0125 |
| Hypersensitive | 2 | 18 | 0.0107 |
| Bullae or blister | 6 | 13 | 0.0077 |
| Hernia | 2 | 8 | 0.0047 |
| Device exfoliation | 3 | 7 | 0.0042 |
| Sutures protrude | 1 | 6 | 0.0036 |
| Numbness | 2 | 5 | 0.0030 |
| Skin cutting | 2 | 4 | 0.0024 |
| Maceration | 1 | 3 | 0.0018 |
| Noncompliance | 3 | 3 | 0.0018 |
| Enterocutaneous fistulation | 1 | 2 | 0.0012 |
| Allergy | 2 | 2 | 0.0012 |
| Ischaemia | 1 | 2 | 0.0012 |
| Haematoma | 1 | 1 | 0.0006 |
| Skin discolouration | 1 | 1 | 0.0006 |
| Epidermolysis | 1 | 1 | 0.0006 |
| Erythema | 1 | 1 | 0.0006 |

and aetiologies also differed. For example, most of the articles did not analyse patients with diabetes separately, which is recognized as an important factor in wound healing. The starting time of expansion was another important factor. Kakagia reported that fasciotomies performed more than 8 h after injury were related to longer wound closure times than fasciotomies performed earlier [52]. Moreover, heterogeneity associated solely with methodological diversity would indicate that the studies suffer from different degrees of bias. As most of the studies meeting the inclusion criteria were case series, the level of evidence was lower, and most of the studies tended to report positive results, which may explain the extremely high healing rate. Because the intervention is a kind of operation, the reason for the lack of blinding can be easily understood.

Some concerns remain regarding the safety of the technique in the treatment of soft tissue defects. Although many individual studies have reported complications, no systematic review has reported a pooled analysis of the complication rate. Our systematic review is the first to collect all published complication rates and perform a pooled analysis to show the safety profile of the external tissue expansion technique. Among 1686 patients, almost one-sixth experienced some kind of complication. We grouped bullae, blisters, skin cutting and ischaemia as injuries to wound edges, which occurred in 1.13% of cases. Most of these complications were relatively minor and could be resolved by dressing changes. Long-term complications, such as scar formation and paraesthesia of regenerating skin, are the greatest concerns for doctors and patients. The rate of scar formation was 3.02%, which was second only to the rate of dehiscence. However, most scars were mild with no need for correction. We cannot ignore the fact that stretching plays an important role in scar formation. Moreover, some devices can permanently destroy wound margins, which results in scar formation in the wound margins. Paraesthesia of new regenerating skin included hypersensitivity and numbness, which accounted for 1.37% of complications. The damage to the wound edges caused by some devices, such as the devices combined with KWs, may be the most likely cause.

This review has several limitations. The first limitation is that we included a relatively low level of evidence in our review. Although we admit that this introduces a limitation to our analysis, because of the novelty of the field and the lack of high-quality trials, we believe that the benefit of including all the studies outweighs the limitation introduced due to the lower level of evidence. As described in supplementary Table 1, some included studies had the same senior author and organizations; thus, the same patient may have been referenced more than once. Therefore, we must interpret the meta-analysis results with caution considering that the actual number of patients may be overestimated. However, we believe that the meta-analysis provides higher-level evidence that is meaningful for surgeries and patients to base their clinical decisions on.

Here, we compared the external tissue expansion technique with other reconstructive methods to identify the indications and contraindications for external soft tissue defects. Finally, we will discuss the differences between

Downloaded from academic.oup.com/burnstrauma/article/doi/10.1093/burnst/tkac045/6887310 by guest on 14 October 2026

various devices and provide recommendations for clinical application.

All the clinical studies mentioned above provide evidence to support the use of the external tissue expansion technique in the management of various soft tissue defects. According to the traditional reconstruction ladder, options for the closure of complex wounds include dressings, primary closure, delayed closure, skin grafts and internal tissue expansion, which involves a staged procedure using skin grafts [97]. The application of external tissue expansion devices may be an alternative to tension sutures, skin grafts or even reoperations. Unlike skin grafts, external tissue expansion facilitates delayed primary closure or primary closure with ideal colour and skin texture matching by expanding the healthy skin of the wound margin and without the creation of donor sites. As a result, the method spares the need for a second operation with general anaesthesia. External tissue expansion has been reported to decrease the wound closure time, hospital stay time and total wound care cost [95,98]. Notably, external tissue expansion may reduce the time to rehabilitation initiation following surgery [28], which may be a considerable advantage for battlefield applications compared with skin grafts and artificial dermis [76]. However, the effect of external tissue expansion has not exactly been confirmed by high-grade RCTs. Skin grafts are still the ultimate surgical technique for the closure of complex soft tissue defects, especially for failed closure under external tissue expansion. Complications of the external tissue expansion technique include infection, skin necrosis, skin dehiscence, skin lesions, hernia formation (abdominal defects), enterocutaneous fistulization (abdominal defects), haematoma, pain and scar widening. However, there are significant inter-device and inter-patient differences in complications. All baseline characteristics, including defect area, defect type, defect location and underlying diseases, will influence the effect of the external tissue technique. Compared with that of internal expansion devices, the incidence of postoperative infection with external tissue expansion devices is lower. Infections would be identified and controlled easily since the device is located outside the body. Contraindications to the external tissue expansion technique include ischaemia of wound margins, active inflammation, excessively fragile tissue, localized radiation or chemotherapy and insufficient soft tissue coverage [26,30]. Patients with compromised immune systems or conditions affecting tissue quality should be treated with caution [4]. However, all the contraindications are relative, not absolute.

Selecting an external tissue expansion device warrants certain considerations due to the differences between them. The first consideration is the basic characteristics of wounds. For example, considering the defect location, devices with lower profiles may have fewer limitations, such as DermaClose®, TopClosure®, Ty-raps, nice knots and noninvasive devices. Additionally, devices with larger sizes, such as BHS® and some homemade devices, will not be a good choice to close defects in the backside or head and neck [44]. Devices with lower profiles would result in less noncompliance [1]. The defect area is one of the determining factors for the final choice of device. To treat some deep defects, we need a device that can expand skin and subcutaneous tissue at the same time, such as Wisebands® or the ABRA® abdominal system. Larger devices may be a better choice for large defects with high tension. Moreover, aetiologies and underlying diseases should be considered. For instance, in patients with diabetes, vascular injury or wounds caused by blasts, devices requiring undermining will increase the risk of inflammation and necrosis of wound edges, such as the DermaClose® and S.T.A.R. devices. Other factors, such as costs, technical difficulty, self-tightening capacities and the surgeon's proficiency, also need to be considered.

Notably, the external tissue expansion technique has been applied in the battlefield. Topaz *et al*. described the utility of TopClosure® in the treatment of combat-related soft tissue injuries [76]. Singh *et al*. reported the use of the ABRA® dynamic wound closure system during Operation Iraqi Freedom in the treatment of compartment syndrome [59]. Santiago *et al*. suggested that appropriate application of DermaClose could help decrease the need for skin grafts for war-related injuries [77]. Both retrospective studies demonstrated that external tissue expansion is a novel method for early and simplified closure of combat-related wounds to promote early mobilization and rehabilitation of soldiers, which is important for the combat effectiveness of troops [76].

## Conclusions

External tissue expansion techniques are becoming more widely used for the management of various soft tissue defects. In the studies mentioned above, the external tissue expansion technique was demonstrated to be an effective and safe method for the reconstruction of soft tissue defects. However, large-scale RCTs and long-term follow-up studies are still required to confirm the effectiveness and evaluate the quality of healing. Relevant consensus recommendations are also needed to standardize clinical practices.

## Supplementary data

Supplementary data is available at *BURNST Journal* online.

## Authors' contributions

XT, JL and WZ conducted the study and screened the included papers. XT, JL and WZ wrote the manuscript. SW and RH drew the diagrams. XZ, JH, and YZ collected and extracted data from the included studies. XT performed the data analysis. SX, SJ and ZX designed the study and provided guidance for preparation of the manuscript.

## Conflict of interest

None declared.

Downloaded from academic.oup.com/burnstrauma/article/doi/10.1093/burnst/tkac045/6887310 by guest on 14 October 2026

## Acknowledgements

This work was funded by the National Natural Science Foundation of China (81930057, 81772076, 81971836), the CAMS Innovation Fund for Medical Sciences (2019-I2M-5-076), the Deep Blue Talent Project of Naval Medical University, the 234 Academic Climbing Programme of Changhai Hospital and the Achievements Supportive Fund (2018-CGPZ-B03).

## References

1. Arain AR, Cole K, Sullivan C, Banerjee S, Kazley J, Uhl RL. Tissue expanders with a focus on extremity reconstruction. *Expert Rev Med Devices*. 2018;15:145–55.
2. Xu J, Chang R, Zhang W, Zhang C, Zhu D, Liu F, *et al*. Skin stretch suturing with nice knots in the treatment of small- or medium-sized wounds. *J Orthop Surg Res*. 2020;15:488.
3. Kang MJ, Chung CH, Chang YJ, Kim KH. Reconstruction of the lower extremity using free flaps. *Arch Plast Surg*. 2013; 40:575–83.
4. MacKay BJ, Dardano AN, Klapper AM, Parekh SG, Soliman MQ, Valerio IL. Multidisciplinary application of an external tissue expander device to improve patient outcomes: a critical review. *Adv Wound Care (New Rochelle)*. 2020;9:525–38.
5. Neumann CG. The expansion of an area of skin by progressive distention of a subcutaneous balloon; use of the method for securing skin for subtotal reconstruction of the ear. *Plast Reconstr Surg (1946)*. 1957;19:124–30.
6. Gibson T, Kenedi RM. Biomechanical properties of skin. *Surg Clin North Am*. 1967;47:279–94.
7. Hussain SH, Limthongkul B, Humphreys TR. The biomechanical properties of the skin. *Dermatol Surg*. 2013;39:193–203.
8. Squier CA. The stretching of mouse skin in vivo: effect on epidermal proliferation and thickness. *J Invest Dermatol*. 1980; 74:68–71.
9. Lew D, Fuseler JW. The effect of stepwise expansion on the mitotic activity and vascularity of subdermal tissue and induced capsule in the rat. *J Oral Maxillofac Surg*. 1991;49: 848–53.
10. Pasyk KA, Argenta LC, Hassett C. Quantitative analysis of the thickness of human skin and subcutaneous tissue following controlled expansion with a silicone implant. *Plast Reconstr Surg*. 1988;81:516–23.
11. Kao HK, Hsu HH, Chuang WY, Chen SC, Chen B, Wu SC, *et al*. External volume expansion modulates vascular growth and functional maturation in a swine model. *Sci Rep*. 2016;6:25865.
12. Hsiao HY, Liu JW, Brey EM, Cheng MH. The effects of negative pressure by external tissue expansion device on epithelial cell proliferation, neo-vascularization and hair growth in a porcine model. *PLoS One*. 2016;11:e0154328.
13. Zoellner AM, Holland MA, Honda KS, Gosain AK, Kuhl E. Growth on demand: reviewing the mechanobiology of stretched skin. *J Mech Behav Biomed Mater*. 2013;28:495–509.
14. Aragona M, Sifrim A, Malfait M, Song Y, Van Herck J, Dekoninck S, *et al*. Mechanisms of stretch-mediated skin expansion at single-cell resolution. *Nature*. 2020;584:268–73.
15. Rübsam M, Niessen CM. Stretch exercises for stem cells expand the skin. *Nature*. 2020;584:196–8.
16. Hirshowitz B, Kaufman T, Ullman J. Reconstruction of the tip of the nose and ala by load cycling of the nasal skin and harnessing of extra skin. *Plast Reconstr Surg*. 1986;77:316–9.
17. Cohn BT, Shall J, Berkowitz M. Forearm fasciotomy for acute compartment syndrome: a new technique for delayed primary closure. *Orthopedics* 1986, 9(9):1243–6.
18. Hirshowitz B, Lindenbaum E, Har-Shai Y. A skin-stretching device for the harnessing of the viscoelastic properties of skin. *Plast Reconstr Surg*. 1993;92:260–70.
19. Escalera GA, Swan KG. Progressive wound closure with constant tension traction: combat theater application. *Mil Med*. 1993;158:60–3.
20. Moher D, Liberati A, Tetzlaff J, Altman DG. Preferred reporting items for systematic reviews and meta-analyses: the PRISMA statement. *PLoS Med*. 2009;6:e1000097.
21. Murad MH, Sultan S, Haffar S, Bazerbachi F. Methodological quality and synthesis of case series and case reports. *BMJ Evid Based Med*. 2018;23:60–3.
22. Higgins JPT, Thomas J, Chandler J, Cumpston M, Li T, Page MJ, Welch VA (editors). *Cochrane Handbook for Systematic Reviews of Interventions*. 2nd Edition. Chichester (UK): John Wiley & Sons, 2019.
23. Slim K, Nini E, Forestier D, Kwiatkowski F, Panis Y, Chipponi J. Methodological index for non-randomized studies (minors): development and validation of a new instrument. *ANZ J Surg*. 2003;73:712–6.
24. Cohen BH, Cosmetto AJ. The suture tension adjustment reel. A new device for the management of skin closure. *J Dermatol Surg Oncol*. 1992;18:112–23.
25. Dodenhoff RM, Howell GE. The shoelace technique for wound closure in open fractures: report of early experience. *Injury*. 1997;28:593–5.
26. Armstrong DG, Sorensen JC, Bushman TR. Exploiting the viscoelastic properties of pedal skin with the sure closure skin stretching device. *J Foot Ankle Surg*. 1995;34:247–53.
27. Govaert GA, van Helden S. Ty-raps in trauma: a novel closing technique of extremity fasciotomy wounds. *J Trauma*. 2010; 69:972–5.
28. Medina C, Spears J, Mitra A. The use of an innovative device for wound closure after upper extremity fasciotomy. *Hand (N Y)*. 2008;3:146–51.
29. Bjarnesen JP, Wester JU, Siemssen SS, Blomqvist G, Jensen NK. External tissue stretching for closing skin defects in 22 patients. *Acta Orthop Scand*. 1996;67:182–4.
30. Ger R. The use of external tissue expansion in the management of wounds and ulcers. *Ann Plast Surg*. 1997;38: 352–7.
31. Barnea Y, Gur E, Amir A, Leshem D, Zaretski A, Shafir R, *et al*. Our experience with wisebands: a new skin and soft-tissue stretch device. *Plast Reconstr Surg*. 2004;113:862–9.
32. O'Reilly AG, Schmitt WR, Roenigk RK, Moore EJ, Price DL. Closure of scalp and forehead defects using external tissue expander. *Arch Facial Plast Surg*. 2012;14:419–22.
33. Topaz M, Carmel NN, Silberman A, Li MS, Li YZ. The TopClosure® 3S system, for skin stretching and a secure wound closure. *Eur J Plast Surg*. 2012;35:533–43.
34. Taylor RC, Reitsma BJ, Sarazin S, Bell MG. Early results using a dynamic method for delayed primary closure of fasciotomy wounds. *J Am Coll Surg*. 2003;197:872–8.
35. Ji P, Zhang Y, Hu DH, Zhang Z, Li XQ, Tong L, *et al*. Clinical effects of combined application of skin-stretching device and vacuum sealing drainage in repairing the diabetic foot wounds. *Zhonghua Shao Shang Za Zhi*. 2020;36:1035–9.

Downloaded from academic.oup.com/burnstrauma/article/doi/10.1093/burnst/tkac045/6887310 by guest on 14 October 2026

36. Risnes I, Abdelnoor M, Lundblad R, Baksaas ST, Svennevig JL. Leg wound closure after saphenous vein harvesting in patients undergoing coronary artery bypass grafting: a prospective randomized study comparing intracutaneous, transcutaneous and zipper techniques. *Scand Cardiovasc J*. 2002;36:378–82.
37. Wang L, Wang C, Chen H, Zhang D, Chen Y, Li J, *et al*. Application of noninvasive skin-stretching device in wound healing of diabetic foot. *Chinese Journal of Diabetes Mellitus*. 2018;10:729–34.
38. Cheng LF, Lee JT, Hsu H, Wu MS. Simple skin-stretching device in assisted tension-free wound closure. *Ann Plast Surg*. 2017;78:S52–s57.
39. Chen Q, Su W. Treatment of 16 cases of skin defect by stretch regeneration according to law of tension stress. *Chinese Journal of Orthopaedic Trauma*. 2018;20:537–40.
40. Lee ET. A new wound closure achieving and maintaining device using serial tightening of loop suture and its clinical applications in 15 consecutive patients for up to 102 days. *Ann Plast Surg*. 2004;53:436–41.
41. Ren G, Zhang M, Cui Z, Wang G, Yu B. Skin stretching device combined with collagen sponge for wound repair. *Chinese Journal of Orthopaedic Trauma*. 2018;20:689–95.
42. Wu Q, Shao Z, Li Y, Rai S, Cui M, Yang Y, *et al*. A novel skin-stretching device for closing large skin-soft tissue defects after soft tissue sarcoma resection. *World J Surg Oncol*. 2020;18:247.
43. Dong Q, Gu G, Wang L, Fu K, Xie S, Zhang S, *et al*. Application of modified adjustable skin stretching and secure wound-closure system in repairing of skin and soft tissue defect. *Zhongguo Xiu Fu Chong Jian Wai Ke Za Zhi*. 2017;31:1481–4.
44. Kocialkowski A, Marsh DR, Shackley DC. Closure of the skin defect overlying infected non-union by skin traction. *Br J Plast Surg*. 1998;51:307–10.
45. Chen T, Ma X, Ma J, Yu R. Treatment of skin and soft tissue defect with nice combination with elastic dressing and stretch. *Chinese Journal of Orthopedics*. 2020;40:154–9.
46. Zhou Y, Xue D, Geng K, Yu X, Song H. Modified continuous skin stretch technique to treat large area skin defects. *Orthopedic Journal of China*. 2021;29:2082–5.
47. Kenny EM, Egro FM, Russavage JM, Spiess AM, Acartürk TO. Primary closure of wide fasciotomy and surgical wounds using rubber band-assisted external tissue expansion: a simple, safe, and cost-effective technique. *Ann Plast Surg*. 2018;81:344–52.
48. Wu Y, Chen L, Mao X, Ru Z, Yu L, Chen M, *et al*. Closure of complex wounds by a simple skin stretching system associated with vacuum sealing drainage—clinical outcome of 34 patients. *Int J Low Extrem Wounds*. 2021;0:153473462110320. https://doi.org/10.1177/15347346211032046.
49. Daya M, Nair V. Traction-assisted dermatogenesis by serial intermittent skin tape application. *Plast Reconstr Surg*. 2008;122:1047–54.
50. Asgari MM, Spinelli HM. The vessel loop shoelace technique for closure of fasciotomy wounds. *Ann Plast Surg*. 2000;44:225–9.
51. Janzing HM, Broos PL. Dermatotraction: an effective technique for the closure of fasciotomy wounds: a preliminary report of fifteen patients. *J Orthop Trauma*. 2001;15:438–41.
52. Kakagia D, Karadimas EJ, Drosos G, Ververidis A, Trypsiannis G, Verettas D. Wound closure of leg fasciotomy: comparison of vacuum-assisted closure versus shoelace technique. A randomised study. *Injury*. 2014;45:890–3.
53. Arumugam PK, Muthukumar V, Bamal R. Utility of shoelace technique in closure of fasciotomy wounds in electric burns. *J Burn Care Res*. 2021;42:538–44.
54. Stahl S, Har-Shai Y, Hirshowitz B. Closure of wounds in the upper extremity using a skin stretching device. *J Hand Surg Br*. 1996;21:534–7.
55. Karkos CD, Papoutsis I, Giagtzidis IT, Pliatsios I, Mitka M-A, Papazoglou KO, *et al*. Management of Postfasciotomy Wounds and Skin Defects Following Complex Vascular Trauma to the extremities using the external tissue extender system. *Int J Low Extrem Wounds*. 2018;17:113–9.
56. Barnea Y, Gur E, Amir A, Leshem D, Zaretski A, Miller E, *et al*. Delayed primary closure of fasciotomy wounds with Wisebands®, a skin- and soft tissue-stretch device. *Injury*. 2006;37:561–6.
57. Choi YK, Mehta ST, Luo J, Siddiqi F, Gociman B. Management of Large Pediatric Wound Defects Using a continuous external tissue expander. *Plast Reconstr Surg Glob Open*. 2021;9:e3723.
58. Huahui Z, Dan X, Hongfei J, Hang H, Chunmao H, Haitao R, *et al*. Evaluation of a new tension relief system for securing wound closure: a single-Centre, Chinese cohort study. *Plast Surg (Oakv)*. 2016;24:177–82.
59. Singh N, Bluman E, Starnes B, Andersen C. Dynamic wound closure for decompressive leg fasciotomy wounds. *Am Surg*. 2008;74:217–20.
60. Han Y, Chen Y, Liu D, Guo Q, Du S, Zhou S, *et al*. A novel draw-bar skin stretcher for repair of full-thickness skin defects. *Chinese Journal of Orthopaedic Trauma*. 2021;23:627–31.
61. Futran ND. Closure of the fibula free flap donor site with the sure-closure skin-stretching device. *Laryngoscope*. 1996;106:1487–90.
62. Marrero GM, Dufresne RG. An intraoperative skin-stretching device to close wounds in Mohs defects. *Dermatol Surg*. 1996;22:546–50.
63. Samis AJW, Davidson JSD. Skin-stretching device for intraoperative primary closure of radial forearm flap donor site. *Plast Reconstr Surg*. 2000;105:698–702.
64. Melis P, Van Noorden CJF, Van Der Horst CMAM. Long-term results of wounds closed under a significant amount of tension. *Plast Reconstr Surg*. 2006;117:259–65.
65. Verhaegen PD, van Trier AJ, Jongen SJ, Vlig M, Nieuwenhuis MK, Middelkoop E, *et al*. Efficacy of skin stretching for burn scar excision: a multicenter randomized controlled trial. *Plast Reconstr Surg*. 2011;127:1958–66.
66. Verhaegen PDHM, van der Wal MBA, Bloemen MCT, Dokter J, Melis P, Middelkoop E, *et al*. Sustainable effect of skin stretching for burn scar excision: long-term results of a multicenter randomized controlled trial. *Burns*. 2011;37:1222–8.
67. Brongo S, Pilegaard J, Blomqvist G. Clinical experiences with the external tissue extender. *Scand J Plast Reconstr Surg Hand Surg*. 1997;31:57–63.
68. Ger R, Schessel ES. Technique for use of external tissue expansion for reconstruction of head and face defects. *Dermatol Surg*. 2007;33:864–71.
69. Schessel ES, Lombardi CM, Dennis LN. External constant tension expansion of soft tissue for the treatment of ulceration of the foot and ankle. *J Foot Ankle Surg*. 2000;39:321–8.
70. Senchenkov A, Agag RL, Lee J, Patel A, Valerio IL. Management of anterolateral thigh free flap donor site defects with a continuous external tissue expander. *Microsurgery*. 2015;35:290–4.

Downloaded from academic.oup.com/burnstrauma/article/doi/10.1093/burnst/tkac045/6887310 by guest on 14 October 2026

71. Topaz M, Carmel NN, Topaz G, Li M, Li YZ. Stress-relaxation and tension relief system for immediate primary closure of large and huge soft tissue defects: an old-new concept new concept for direct closure of large defects. *Medicine (Baltimore)*. 2014;93:e234.
72. Ratnam BV. External tissue expansion using an external fixator for direct closure of problem wounds. *Eur J Plast Surg*. 2012;35:285–91.
73. Wang G, Zhang X, Zhang Z, Wei Z. Clinical study on a skin stretching technique with adjustable external fixators to treat skin defects. *Medicine (Baltimore)*. 2020;99:e22144.
74. Yuan B, Liang HD, Tong ZH, Song WJ, Ju SL. Application effect of sustainable skin-stretching device in scalp and soft tissue defect. *Zhonghua Shao Shang Za Zhi*. 2020;36:1204–7.
75. Wang X, Zhang Y, Ng SK-H, Zhang Z, Pu Z, Yang H, *et al*. Using modified skin-stretching technique as an alternative solution for the closure of moderate and extensive skin defects. *Rejuvenation Res*. 2021;24:407–16.
76. Topaz M, Ashkenazi I, Barzel O, Biswas S, Atar D, Shadmi N, *et al*. Minimizing treatment complexity of combat-related soft tissue injuries using a dedicated tension relief system and negative pressure therapy augmented by high-dose in situ antibiotic therapy and oxygen delivery: a retrospective study. *Burns Trauma*. 2021;9:tkab007.
77. Santiago GF, Bograd B, Basile PL, Howard RT, Fleming M, Valerio IL. Soft tissue injury management with a continuous external tissue expander. *Ann Plast Surg*. 2012;69:418–21.
78. Armstrong DG, Lavery LA. Mechanically assisted, delayed primary closure of diabetic foot wounds. *J Am Podiatr Med Assoc*. 1998;88:483–8.
79. Ger R, Schessel ES. Prevention of major amputations in nonischemic lower limb lesions. *J Am Coll Surg*. 2005;201:898–905.
80. Price J, Rubens F, Bell M. Elastic device facilitating delayed primary closure of sternal wound infection. *Ann Thorac Surg*. 2007;83:1162–5.
81. Wang L, Wang C, Chen H, Chen Y, Li J, Xiao L, *et al*. The combined use of a non-invasive skin-stretching device and the negative-pressure wound therapy technique in the treatment of postoperative diabetic foot. *Diabetes Metabolic Syndrome And Obesity-Targets And Therapy*. 2021;Volume 14:3523–32.
82. Wang X, Zhu Z, Zhao Y, Yu M, Topaz M. The effect of TopClosure® TRS in the treatment of large abdominal wall defect. *Eur J Plast Surg*. 2019;42:603–10.
83. Reimer MW, Yelle JD, Reitsma B, Doumit G, Allen MA, Bell MS. Management of open abdominal wounds with a dynamic fascial closure system. *Can J Surg*. 2008;51:209–14.
84. Salman AE, Yetişir F, Aksoy M, Tokaç M, Yildirim MB, Kiliç M. Use of dynamic wound closure system in conjunction with vacuum-assisted closure therapy in delayed closure of open abdomen. *Hernia*. 2014;18:99–104.
85. Regner JL, Kobayashi L, Coimbra R. Surgical strategies for management of the open abdomen. *World J Surg*. 2012;36: 497–510.
86. Roolker W, Kraaneveld E, Been HD, Marti RK. Results of a prospective randomised study comparing a non-invasive surgical zipper versus intracutaneous sutures for wound closure. *Arch Orthop Trauma Surg*. 2002;122:2–4.
87. Tanaka Y, Miyamoto T, Naito Y, Yoshitake S, Sasahara A, Miyaji K. Randomized study of a new noninvasive skin closure device for use after congenital heart operations. *Ann Thorac Surg*. 2016;102:1368–74.
88. Gorsulowsky DC, Talmor G. A novel noninvasive wound closure device as the final layer in skin closure. *Dermatol Surg*. 2015;41:987–9.
89. Carli AV, Spiro S, Barlow BT, Haas SB. Using a non-invasive secure skin closure following total knee arthroplasty leads to fewer wound complications and no patient home care visits compared to surgical staples. *Knee*. 2017;24:1221–6.
90. Menkowitz B, Olivieri G, Belson O. Patient satisfaction and cosmetic outcome in a randomized, prospective study of Total knee arthroplasty skin closure comparing zip surgical skin closure with Staples. *Cureus*. 2020;12:e6705.
91. Koerber SM, Loethen T, Turagam M, Payne J, Weachter R, Flaker G, *et al*. Noninvasive tissue adhesive for cardiac implantable electronic device pocket closure: the TAPE pilot study. *J Interv Card Electrophysiol*. 2019;54:171–6.
92. Lee H, Yeom SY, Kim HJ, Yoo JS, Kim DJ, Cho KR. Comparison between noninvasive and conventional skin closure methods in off-pump coronary artery bypass grafting using bilateral internal thoracic artery. *J Thorac Dis*. 2019;11:3920–8.
93. Benner RW, Behrens JP. A novel skin closure device for Total knee arthroplasty: randomized controlled trial versus Staples. *J Knee Surg*. 2020;33:1116–20.
94. Doumit J, Vale R, Kanigsberg N. Dynaclose tape: a practical alternative to punch biopsy site closure. *J Cutan Med Surg*. 2013;17:62–5.
95. Bonaparte JP, Corsten MJ, Allen M. Cosmetic and functional outcomes after preoperative tissue expansion of radial forearm free flap donor sites: a cohort study. *J Otolaryngol Head Neck Surg*. 2011;40:427–35.
96. Bonaparte JP, Corsten M, Allen M. Cost-effectiveness of a topically applied pre-operative tissue expansion device for radial forearm free flaps: a cohort study. *Clin Otolaryngol*. 2011;36:345–51.
97. Janis JE, Kwon RK, Attinger CE. The new reconstructive ladder: modifications to the traditional model. *Plast Reconstr Surg*. 2011;127:205s–12.
98. Park KU, Moquin K. Novel use of external tissue expander for Management of Sternal Wound Dehiscence. *Ann Thorac Surg*. 2015;100:e81–3.

Downloaded from academic.oup.com/burnstrauma/article/doi/10.1093/burnst/tkac045/6887310 by guest on 14 October 2026