

Case Report

Asian Pacific Journal of Tropical Medicine

apjtm.org

doi: 10.4103/apjtm.apjtm_942_23

Symptomatic bradycardia in tuberculosis-related giant bullae (vanishing lung syndrome): A case report

Reynard Laysandro[1]✉, Jessie Julian Mila Meha[2], Resley Ongga Mulia[1], Mikha[3], Nazamta Yusfiatuzzahra[3]

[1]*School of Medicine and Health Science Atma Jaya Catholic University of Indonesia, Jakarta, Indonesia*

[2]*Faculty of Medicine and Veterinary Medicine University of Nusa Cendana, East Nusa Tenggara, Indonesia*

[3]*Faculty of Medicine Trisakti University, Jakarta, Indonesia*

ABSTRACT

Rationale: Vanishing lung syndrome is rare and can be associated with a history of smoking and marijuana use. The occurrence of giant bullae can also be linked to infections, particularly tuberculosis in tropical countries.

Patient concerns: A 26-year-old male complained of weakness, severe vomiting, and reduced breathlessness when lying on the left side. He had a history of pulmonary tuberculosis two years ago.

Diagnosis: Symptomatic bradycardia in tuberculosis-related giant bullae.

Interventions: The patient was recommended to undergo an elective bullectomy, but he decided not to proceed with the procedure. Atropine sulfate was administered to alleviate symptoms of bradycardia, while a standardized anti-tuberculosis regimen were started for the next six months.

Outcomes: Following 7 days of intensive care treatment involving antituberculosis medications and atropine sulfate, the patient achieved hemodynamic stability, opting against bullectomy despite residual symptoms of dyspnea. Subsequent six months of antituberculosis therapy notably alleviated symptoms without requiring bullectomy.

Lessons: Increasing intrathoracic pressure can also be caused mechanically by giant bullae. Cardiac symptoms in vanishing lung syndrome are reversible and can be alleviated once the underlying cause is addressed. In this case, symptomatic bradycardia was reduced only with tuberculosis treatment without bullectomy intervention.

KEYWORDS: Bradycardia; Infected giant bullae; Tuberculosis; Vanishing lung syndrome

1. Introduction

The lung bullae is an air space in the parenchyma. Bullae are usually larger than 1 cm and take up at least one-third of the hemithorax[1,2]. Giant bulla is a rare form of emphysematous lung disease, often known as vanishing lung syndrome (VLS) of idiopathic origin[3]. Giant bullae resulting from tuberculosis infection are considered quite rare. To date, there have been only a few reported cases discussing the co-occurrence of tuberculosis infection with emphysematous lung disease in the form of giant bulla[1]. In this case, we presented a 26-year-old male with a history of tuberculosis (TB) infection who complained of weakness, with a radiological examination revealing a giant bulla in the left hemithorax.

✉To whom correspondence may be addressed. E-mail: reynardlaysandro@gmail.com

This is an open access journal, and articles are distributed under the terms of the Creative Commons Attribution-Non Commercial-ShareAlike 4.0 License, which allows others to remix, tweak, and build upon the work non-commercially, as long as appropriate credit is given and the new creations are licensed under the identical terms.

For reprints contact: reprints@medknow.com

©2024 *Asian Pacific Journal of Tropical Medicine* Produced by Wolters Kluwer-Medknow.

How to cite this article: Laysandro R, Meha JJM, Mulia RO, Mikha, Yusfiatuzzahra N. Symptomatic bradycardia in tuberculosis-related giant bullae (vanishing lung syndrome): A case report. Asian Pac J Trop Med 2024; 17(9): 425-428.

Article history: Received 20 December 2023 Revision 16 September 2024
Accepted 21 September 2024 Available online 27 September 2024

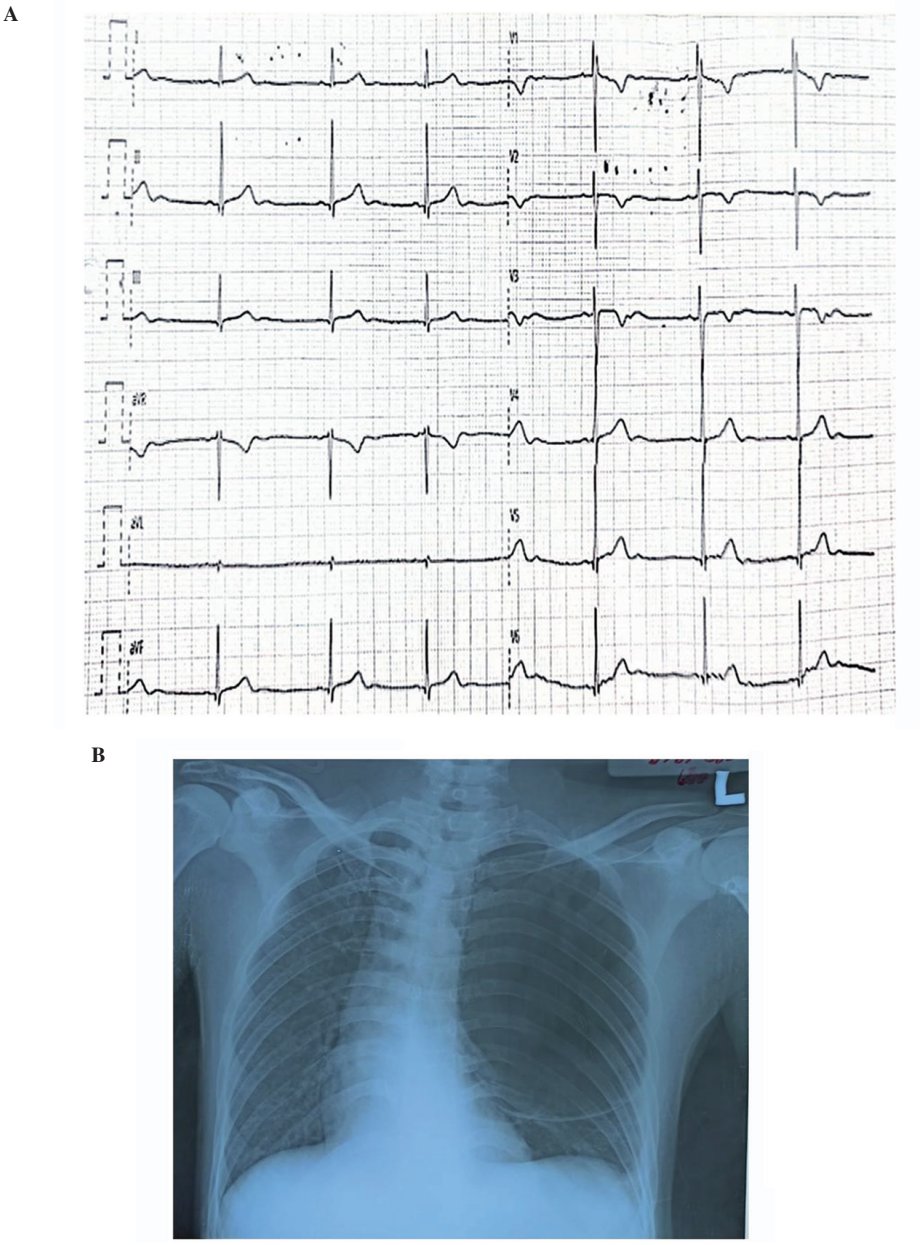

Figure 1. A: Electrocardiograph of a 26-year-old male with symptomatic bradycardia in tuberculosis-related giant bullae, showing bradycardia rhythm with a right bundle branch block pattern. B: Conventional chest radiography with an anterior-posterior projection reveals an increased lucency occupying more than three-quarters of the left lung field without evidence of vascularity, accompanied by a curvilinear fibrotic tissue in the lower region resembling giant bullae. A small portion of compressed viable lung tissue is seen on the lower left hemithorax. Additionally, there is an observed mediastinal shift to the right, suspected to be causing a mass effect.

2. Case presentation

A 26-year-old male patient presented to the emergency department with weakness, severe vomiting, and shortness of breath persisting for the past day, with improvement when the patient laid on his left side. Over the past two days, there has been an onset of cold sweats and increased quietness. The patient denied any history of trauma, fever, prolonged cough, or significant weight loss. He was diagnosed with pulmonary TB two years ago but refused initial treatment.

The patient was lethargic, and examination revealed normal blood pressure, a heart rate of 48 beats per minute, strong radial pulses, and reduced oxygen saturation of 90% free air. Physical examination of the lungs revealed decreased tactile fremitus and vesicular breath sounds on the left side. Complete blood count and metabolic profile showed no abnormalities. However, an electrocardiograph revealed sinus bradycardia and a right bundle branch block (RBBB) pattern (Figure 1A).

Rapid molecular testing confirmed that the patient had active

tuberculosis. A chest X-ray revealed giant bullae in the upper left lung lobe, which displaced the mediastinum to the right side (Figure 1B). Initial treatment in the emergency department included atropine sulfate, omeprazole, and ondansetron, with close monitoring in the ICU. Atropine sulfate temporarily increased the heart rate to 110 beats per minute, but bradycardia recurred within 4 hours. The patient also started a standard anti-TB drug regimen (1st category). After 7 days of ICU treatment, the patient stabilized and was scheduled for elective bullectomy, but the procedure was declined by the family.

3. Discussion

Several studies linked VLS to lung tissue degradation, resulting in large bullae in the upper lobes. These giant bullae can cause serious issues, such as tension pneumothorax, where increased pressure in the chest pushing away the mediastinum structures, compressing the heart and reducing venous return and cardiac output[1–4]. Patients with severe symptoms from this mass effect often need bullectomy. In the case discussed, the patient with active TB was treated with a standard anti-TB regimen (1st category) and showed improvement after one week in the ICU.

RBBB can be found in certain conditions, particularly in cases causing increased intrathoracic and left mediastinal pressure, such as in left pneumothorax[5]. Increasing intrathoracic pressure and pulmonary artery resistance, extending the right ventricle and affecting its conduction pathway[6,7]. Therefore, decompression or reducing the effect of pressure can eliminate the reversible RBBB in this case[7]. In RBBB, sinus bradycardia can occur. Most common is bradycardia-dependent bundle branch block[7].

Giant bullae caused mixed restrictive lung disease, characterized by normal or slightly reduced FEV1 and a decrease in FVC. Another parameter in lung function test is lung diffusion test (DLCO test), which is supposedly to decrease because chronic inflammatory diseases, especially giant bullae caused lung tissues remodeling and thickened alveolar wall that impaired the ability of gas exchange. However, in our case, we don't have a spirometry examination to confirm the result as we are in a rural area with a lack of facilities[8].

Following stabilization, the patient was recommended for a bullectomy to decompress and preserve viable left lung tissue. Indications of bullectomy for this patient include a bulla occupying more than one-third of hemithorax with prolonged dyspnea despite maximal medical therapy. Preoperative evaluation of bullectomy includes chest radiography, CT scan to determine exact location, size and number of bullae and its effect on adjacent mediastinal structures, full pulmonary function testing, and for some patients ventilation perfusion scanning[9]. We planned to refer the patient to a better equipped hospital for an elective bullectomy. Our patient most likely would benefit from the surgery, as it would alleviate the remaining symptoms, and decrease the risk for a spontaneous pneumothorax[10].

Though the patient's family declined owing to financial restrictions, it was advised that routine TB outpatient clinic follow-ups should be maintained. After TB therapy and 6 months of monitoring, the patient's dyspnea and bradycardia symptoms improved. The patient can live normally with a permanent bulla.

This case report highlights the importance of identifying the cause of giant bullae to ensure effective treatment and improve patient outcomes. To the best of our knowledge, it is the first to document the spontaneous resolution of tuberculosis-related giant bullae without surgical intervention, even though the patient was a candidate for surgery. This discovery suggests that, in resource-limited settings, less invasive treatments might be preferable. It also points to a potential update in Clinical Practice Guidelines to include conservative management strategies, which could reduce the need for elective surgery and enhance patient care. However, due to our hospital's limited resources, we couldn't perform comprehensive tests like pulmonary function tests and thoracic CT scans, which affected our evaluation. Future research is needed to assess the feasibility and effectiveness of this conservative approach, including its potential for recurrence.

TB-related giant bullae resembling VLS has a low incidence rate. Bradycardia and right bundle branch block can occur from cardiac conduction abnormalities. This condition can be reversed by treating the cause. Giant bullae from *Mycobacterium tuberculosis* infection necessitate algorithm-based anti-TB treatment. Future in-depth research is necessary to determine whether the conservative treatment approach used in case of tuberculosis-related giant bullae, which avoided surgical intervention, can effectively enhance patient outcomes. In conclusion, treating the patient with only symptomatic and anti-TB medication, without performing a bullectomy, effectively alleviated the bradycardia symptoms. Therefore, patients in similar situations can experience improvement without requiring bullectomy, particularly in low-resource settings.

Conflict of interest statement

The authors declare that they have no conflict of interest.

Ethical approval and consent to participate

The study procedures followed were in accordance with the ethical standards of the Institute Human Ethics Committee and with the Helsinki Declaration of 1975, as revised in 2000. The written informed consent was also obtained before the drafting of manuscript.

Acknowledgements

We thank the editors or referees, effusive comments or dedications.

Funding

The authors received no extramural funding for the study.

Authors' contributions

RL: Conceptualization, data curation, investigation, methodology, resources, software, validation, visualization, writing-original draft preparation; J, Res, M, N: Conceptualization, formal analysis, investigation, resources, supervision, writing-review & editing. All authors read and approved the submitted manuscript.

References

[1] Heo J, Bak SH, Ryu SM, Hong Y. Tuberculosis-infected giant bulla treated by percutaneous drainage followed by obliteration of the pulmonary cavity using talc. *Korean J Thorac Cardiovasc Surg* 2021; **54**(5): 408-411.

[2] Yousaf MN, Chan NN, Janvier A. Vanishing lung syndrome: An idiopathic bullous emphysema mimicking pneumothorax. *Cureus* 2020; **12**(8): e9596..

[3] Chen MT, Tang SE. Tuberculosis-related giant bullae mimicking tension pneumothorax. *Intern Emerg Med* 2017; **12**(7): 1069-1070.

[4] Soltani P, Malozzi CM, Abi Saleh B, Omar B. Electrocardiogram manifestation of spontaneous pneumothorax. *Am J Emerg Med* 2009; **27**(6): 750.e1-750.e5.

[5] Price JW. Novel electrocardiographic changes associated with iatrogenic pneumothorax. *Am J Crit Care* 2006; **15**(4): 415-419.

[6] Yamamoto H, Satomi K, Aizawa Y. Electrocardiographic manifestations in a large right-sided pneumothorax. *BMC Pulm Med* 2021; **21**(1): 101.

[7] Kinoshita S, Katoh T, Tsujimura Y, Sasaki Y. Apparent bradycardia-dependent right bundle branch block associated with atypical atrioventricular wenckebach periodicity as a possible mechanism. *J Electrocardiol* 2003; **36**(4): 355-361.

[8] Siddiqui NA, Mansour MK, Nookala V. Bullous emphysema. In: *StatPearls*. Treasure Island (FL): StatPearls Publishing; 2024.

[9] Greenberg JA, Singhal S, Kaiser LR. Giant bullous lung disease: Evaluation, selection, techniques, and outcomes. *Chest Surg Clin* 2003; **13**(4): 631-649.

[10]Brophy S, Brennan K, French D. Recurrence of primary spontaneous pneumothorax following bullectomy with pleurodesis or pleurectomy: A retrospective analysis. *J Thorac Dis* 2021; **13**(3): 1603-1611.

Publisher's note

The Publisher of the *Journal* remains neutral with regard to jurisdictional claims in published maps and institutional affiliations.

Edited by Pan Y, Lei Y, Zhang Q