

Case Report

Asian Pacific Journal of Tropical Medicine

apjtm.org

doi: 10.4103/apjtm.apjtm_376_24

Dengue hemorhagic fever associated hemophagocytc lymphohistiocytosis in primigravida: A case report

Pyrus Bhellum✉, Rakesh Kumar, Rishabh Bora, Bharat Kumar

Department of Internal Medicine, All India Institute of Medical Sciences, Jodhpur, India

ABSTRACT

Rationale: Hemophagocytic lymphohistiocytosis (HLH) is a rare but severe complication of dengue virus infection, associated with high mortality. We report a case of a 9-week primigravida presenting with high grade fever spikes and a positive Dengue NS1 antigen. The patient exhibited worsening clinical parameters, including cytopenias.

Patient concerns: A primigravida at 9th week of gestation and this condition has limited diagnostic modalities and treatment options for HLH.

Diagnoses: HLH secondary to dengue hemorrhagic fever.

Outcomes: Intravenous steroids were initiated with monitoring of laboratory and clinical parameters. The patient recovered successfully after initiation of intravenous steroids. Oral steroids were subsequently tapered over an next eight-week period, leading to a successful recovery.

Lessons: This case is unique due to the interplay between dengue virus infection, HLH, and early pregnancy, characterized by overlapping clinical symptoms and limited treatment options. Prompt initiation of intravenous steroid therapy resulted in significant clinical improvement. This case highlights the critical importance of early identification and treatment of dengue associated HLH to reduce mortality. Furthermore, it underscores the urgent need for focused research on HLH in pregnant patients, particularly in low and middle income countries.

KEYWORDS: Dengue haemorrhagic fever; Hemophagocytic lymphohistiocytosis; HLH; Pregnant female; Dexamethasone

1. Introduction

Hemophagocytc lymphohistiocytosis (HLH) is a systemic hyperimmunoinflammatory condition which is characterised by uninhibited stimulation and proliferation of cytotoxic T lymphocytes and histiocytes. This results in the release of inflammatory cytokines, which contribute to cell injury and subsequently lead to multiorgan dysfunction[1]. HLH can be primary (inherited) or secondary to severe infections, malignancies or rheumatological conditions. Primary HLH is more commonly seen than secondary HLH (especially in paediatric population). Inheritance pattern is usually autosomal recessive with mutations commonly in *PRF1*, *UNC13D*, *STX11* and *STXBP2* genes[2]. Secondary HLH is usually acquired by viral infections, immunodeficiency states, autoimmune disorders and malignancies. Ebstein barr virus (EBV) is the most common agent to cause secondary HLH. Typically, patients are found to have fever, hepatomegaly or splenomegaly, hyperferritinemia, hypertriglyceridemia, hypofibrinogenemia and marrow findings suggestive of hemophagocytes.

Dengue is an emerging illness in India, where it is endemic in some areas and also causes yearly epidemics. Dengue outbreaks

✉To whom correspondence may be addressed. E-mail: dr.pyrusbhellum@gmail.com

This is an open access journal, and articles are distributed under the terms of the Creative Commons Attribution-Non Commercial-ShareAlike 4.0 License, which allows others to remix, tweak, and build upon the work non-commercially, as long as appropriate credit is given and the new creations are licensed under the identical terms.

For reprints contact: reprints@medknow.com

©2024 *Asian Pacific Journal of Tropical Medicine* Produced by Wolters Kluwer-Medknow.

How to cite this article: Bhellum P, Bora R, Kumar B, Kumar R. Dengue hemorhagic fever associated hemophagocytc lymphohistiocytosis in primigravida: A case report. Asian Pac J Trop Med 2024; 17(12): 563-567.

Article history: Received 8 June 2024 Revision 23 December 2024
Accepted 25 December 2024 Available online 30 December 2024

are associated with high mortality and morbidity and a significant socioeconomic impact. In 2022, India reported 233 251 dengue cases with 303 deaths, according to National Centre for Vector Borne Diseases Control[3]. Dengue virus infection triggering HLH was uncommon but is now being increasingly reported and is associated with poor outcomes. HLH is associated with significant mortality ranging from 14.6% in systematic review and metanalysis to 43% in ICU setting[4]. The clinical features and laboratory investigations of both dengue and HLH are overlapping, thus making diagnosis of HLH in present case even more challenging. As pregnancy would limit the use of radiological imaging and therapeutic drugs. Here, we present a case of HLH secondary to dengue haemorrhagic fever in a primigravida female at 9th week of gestation, which was successfully treated and the patient was recovered. The present case underscores the need for more research on HLH in pregnant patients, especially in low and middle income countries.

2. Case report

A 20-year-old Indian primigravida (period of gestation-9th week +3 days) with no known co-morbidities presented to a tertiary care centre in Western India with complaints of high grade fever spikes since 7 days, periumbilical abdominal pain and two episodes of non-bilious vomiting since 1 day. At presentation to our centre, pulse rate was 122 times/min, blood pressure was 86/40 mmHg, respiratory rate was 24 times/min, oxygen saturation was 100% at room air and axillary temperature was 39.8 ℃. On examination, pallor was present, decreased air entry in bilateral infrascapular and infra-axillary areas and diffuse tenderness over abdomen with shifting dullness. Complete hemogram revealed pancytopenia (Hb-9.5 g/dL, TLC-2 450/mL, PLT-49 000/mL), liver function showed transaminitis (AST-138.4 IU/L, ALT-27.9 IU/L) and albumin globulin reversal. Kidney function test and serum electrolytes were normal. Electrocardiogram showed sinus tachycardia. Dengue non structural protein 1 (NS1) antigen and dengue IgM antibody came out to be positive. Malaria, leptospira IgM & IgG, typhoid IgM & IgG and scrub typhus IgM were negative. Blood and urine cultures were sterile. Ultrasound whole abdomen and thorax revealed bilateral pleural effusion of around 1.4 cm pleural separation, diffuse B lines, mild-moderate ascites and splenomegaly ~14.5 cm. Supportive management was started in lines of dengue fever with guarded intravenous fluids. Complete hemogram trend was followed which revealed worsening of pancytopenia with platelet count decreasing to 18 000/mcL and absolute neutrophil count to 350 cells/μL. Dengue typically presents with a febrile phase lasting 3-7 days, but in this case, the patient continued to have high-grade fever spikes beyond the expected febrile phase despite adequate supportive care. The persistence of fever even after 9th day of illness is unusual in dengue and there was worsening of pancytopenia, transaminitis and clinical condition of patient which prompted to consider for secondary complications of dengue which also included secondary HLH. Ferritin was sent and it came out to be elevated (5 417 ng/mL). She had two episodes of epistaxis and one episode of hematemesis (~100 mL) on Day 2 after which total of 8 units of random donor platelets were transfused. In view of suspected hemophagocytic lymphocytic histiocytosis (HLH), other relevant investigations were sent which revealed hypertriglyceridemia (283 mg/dL), hypofibrinogenemia (186 mg/dL). HScore was calculated for HLH which came out to be 233, which was 98%-99% predictive of HLH. Repeat HLH profile was sent which revealed increasing ferritin levels (16 020 ng/mL). Bone marrow aspiration and biopsy was done on Day 3 of hospital admission which revealed evidence of hemophagocytes. She was fulfilling six out of eight criterias according to HLH 2004. Patient developed increasing oxygen requirement to 5 L/min on Day 3, repeat ultrasound thorax revealed increased pleural separation, bilateral worsening B profile and left lower lobe shredding suggestive of active infection consolidation. Severe acute respiratory syndrome coronavirus 2 and swine influenza PCR were negative. Two-dimensional echo was normal with no RWMA and normal systolic ejection fraction. In view of suspected left lower lobe pneumonia, she was started on broad spectrum antibiotics with meropenem and vancomycin. She was started on dexamethasone 14 mg (10 mg/m^2) according to HLH protocol 2004 on Day 4. Etoposide was not added to treatment protocol as it belonged to category C drug in pregnancy. Intravenous immunoglobulin was kept as backup, to be added if patient didn't improve with Dexamethasone only. Serial complete hemograms showed improvement of pancytopenia with resolution of other parameters like ferritin, fibrinogen and LDH (Supplementary Table 1). Fever spikes resolved on day 5 of admission with tapering of oxygen requirement by Day 7 of admission (Figure 1). She gradually symptomatically improved and was discharged on Day 10 of hospitalisation. Repeat ultrasound for fetal wellbeing was done on day 10 which showed single live intrauterine foetus with CRL corresponding to 10 weeks 5 days. On follow up after 2 months,

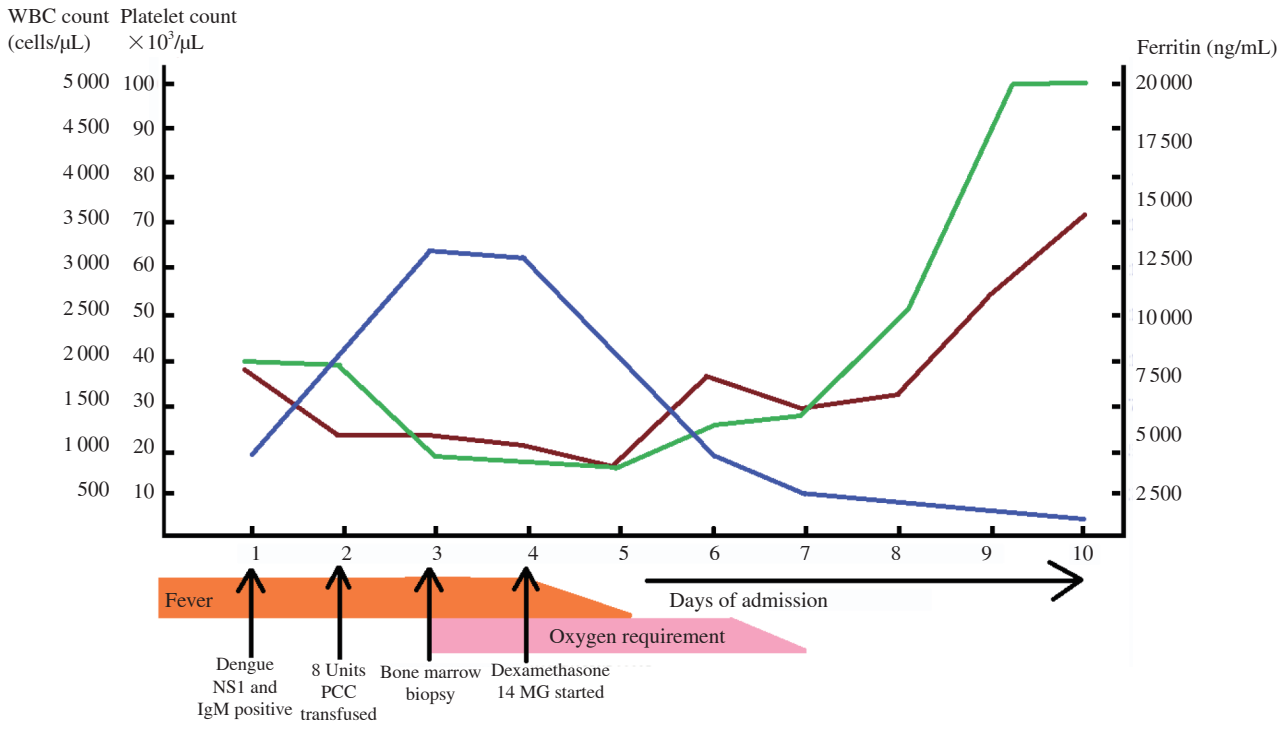

Figure 1. Clinical course of a 20-year-old primigravida at 9th week of gestation with hemophagocytic lymphohistiocytosis secondary to dengue hemorrhagic fever. The red line shows the course of platelet count, the green line shows the course of WBC count, and the blue line shows the course of ferritin levels. WBC: white blood cells; PCC: platelet concentrates; NS1: non-structural proteins 1.

mother and fetus were healthy with completely normal serial ultrasound reports. Dexamethsasone was tapered according to HLH-2004 protocol with 14 mg (10 mg/m^2) for 2 weeks, 7 mg (5 mg/m^2) for next 2 weeks, 3.5 mg (2.5 mg/m^2) for next 2 weeks and 1.75 mg (1.25 mg/m^2) for 1 week.

3. Discussion

HLH is an uncommon systemic hyperimmunoinflammatory condition which is characterized by activation of macrophages leading to cytokine release. HLH is diagnosed when five out eight diagnostic criteria are fulfilled[2], which in our patient were (1) fever, (2) cytopenia on peripheral film examination, (3) hypertriglyceridemia or hypofibrinogenemia, (4) hyperferritinemia, (5) splenomegaly and (6) demonstration of histiocytes on bone marrow (Supplementary Table 1). Hyperferritinemia is strongly associated with HLH, and a cutoff value of greater than 10 000 μg/L is 90% sensitive and 96% specific for its diagnosis. In our patient, there was a rapid increase in ferritin levels, indicating underlying hyperimmune response. HScore is another criterion used for the diagnosis of HLH[5] and a cutoff of 168 points reveals a sensitivity of 100% and a specificity of 94.1%. Our patient had a HScore of 233 which was 98%-99% predictive of HLH. A retrospective study of 162 patients of reactive HLH revealed mortality of 42%[6].

Dengue virus belongs to the genus *Flavivirus* within the Flaviviridae family and has four serotypes DENV1-4. This virus can be detected in the circulation system within the first 4 to 5 days by checking for NS1 antigen. IgM antibodies are detectable in 50% of patients by three to 5 days after the onset of illness, increasing to 80% by day 5 and 99% by day 10, where it peaks at about 2 weeks after the onset of symptoms and then generally decline to undetectable levels over 2 to 3 months. Our patient had dengue NS1 antigen positivity and classical signs and symptoms of dengue haemorrhagic fever. A mild disease is seen in majority of cases, only less than 2% of dengue patients presented with severe manifestations, dengue haemorrhagic fever and dengue shock syndrome which are both associated with considerable mortality and morbidity. Persistence of fever after

8 days in dengue should alert towards the diagnosis of HLH, as duration of dengue febrile phase is generally 3-7 days. Our patient was having persistent high grade fever spikes despite adequate antipyretics with worsening of pancytopenia even after 7 days of illness. As initial symptoms of HLH are non specific and may overlap with other inflammatory or hematopoietic conditions, it is very likely that the diagnosis of HLH secondary to dengue infection is missed.

Management of infection associated secondary HLH is to treat the underlying triggering infection. In majority of the cases of dengue related HLH, pulse dosage of methylprednisolone or dexamethasone have been used to suppress the hyperinflammatory state. The HLH-2004 guideline recommends chemo-immunotherapy with etoposide, dexamethasone, cyclosporine A upfront, and intrathecal therapy with methotrexate in selected patients[2]. HLH in pregnancy is particularly unique considering the limitations in therapeutic options. While the HLH-2004 protocol recommends a combination of etoposide, dexamethasone, and cyclosporine A, drugs like etoposide and cyclosporine are categorized as class C medications and pose potential risks to fetal development. Therefore, treatment must be tailored carefully, often relying on steroids like dexamethasone and, in some cases, intravenous immunoglobulin. However, some studies have shown that the use of etoposide would be of more benefit to the patient than potential harm to the foetus. In a literature review by Lidong *et al.*, etoposide was used in 32 of the 81 patients, among whom 23 women were in remission after treatment[7]. Song *et al.* reported the use of etoposide in a pregnant patient with HLH, and no congenital malformations were found in the fetus[8]. Teng *et al.* reported termination of pregnancy led to recovery from HLH in a 23 weeks POG female who had no response to corticosteroids[9]. There is currently no consensus on the treatment of HLH during pregnancy.

Dengue infection during pregnancy presents significant risks to both the mother and the fetus, especially when complicated by HLH, a rare but life-threatening hyperinflammatory condition. pregnant women have an elevated risk of complications which includes hemorrhage, preterm labor, fetal distress, and vertical transmission of the virus. The overlap of symptoms between dengue fever, HLH and normal pregnancy can delay the diagnosis, increasing the risk of severe complications for both mother and fetus. Due to the potential teratogenicity of standard HLH treatments like etoposide and cyclosporine, therapeutic options must be carefully chosen, often relying on high dose steroids. The interplay between dengue, HLH, and early pregnancy, with overlapping symptoms and limited treatment options makes this case unique. The present case underscores the need for more research on HLH in pregnant patients, especially in low and middle income countries where both dengue fever and HLH are underdiagnosed due to overlapping symptoms and limited healthcare resources.

4. Conclusions

Dengue poses a significant global health challenge which lacks specific treatments beyond supportive care. While treatment primarily focused on managing bleeding and capillary permeability, diagnosis of dengue-associated HLH is tricky. Treatment of HLH includes dexamethasone, etoposide, cyclosporine A and intravenous immunoglobulins. In our case, the use of certain drugs was restricted and steroids were mainstay of treatment. Persistent fever, pancytopenia, and splenomegaly are important clinical features of HLH. A high index of suspicion along with close monitoring of laboratory investigations and clinical parameters are crucial in early diagnosis and management of dengue associated HLH.

Conflict of interest statement

The authors declare that they have no conflict of interest.

Informed consent and ethical approval

Written informed consent was obtained from the patient for the publication of this case report and any accompanying images. Every effort has been made to maintain the patient's anonymity. Ethical approval for the publication of this case report was obtained.

Funding

The authors received no extramural funding for the study.

Authors' contributions

Conception and drafting of manuscript: PB, RB and RK; Supervised the clinical aspects of the case: BK, RK; Patient management and primary care: PB, RB and RK, assisted with the literature review and interpretation of findings: RB and RK.

References

[1] Morimoto A, Nakazawa Y, Ishii E. Hemophagocytic lymphohistiocytosis: Pathogenesis, diagnosis, and management. *Pediatr Int* 2016; **58**(9): 817-825.

[2] Henter JI, Horne A, Aricó M, Egeler RM, Filipovich AH, Imashuku S, et al. HLH-2004: Diagnostic and therapeutic guidelines for hemophagocytic lymphohistiocytosis. *Pediatr Blood Cancer* 2007; **48**(2): 124-131.

[3] National Center for Vector Borne Diseases Control. *Dengue situation in India*. [Online]. Available from: https://ncvbdc.mohfw.gov.in/index4.php?lang=1&level=0&linkid=431&lid=3715. [Accessed on 30 May 2024].

[4] Kan FK, Tan CC, Von Bahr Greenwood T, Khalid KE, Supramaniam P, Hed Myrberg I, et al. Dengue infection complicated by hemophagocytic lymphohistiocytosis: Experiences from 180 patients with severe dengue. *Clin Infect Dis* 2020; **70**(11): 2247-2255.

[5] Fardet L, Galicier L, Lambotte O, Marzac C, Aumont C, Chahwan D, et al. Development and validation of the HScore, a score for the diagnosis of reactive hemophagocytic syndrome. *Arthritis Rheumatol* 2014; **66**(9): 2613-2620.

[6] Rivière S, Galicier L, Coppo P, Marzac C, Aumont C, Lambotte O, et al. Reactive hemophagocytic syndrome in adults: A retrospective analysis of 162 patients. *Am J Med* 2014; **127**(11): 1118-1125.

[7] Liu L, Cui Y, Zhou Q, Zhao H, Li X. Hemophagocytic lymphohistiocytosis during pregnancy: A review of the literature in epidemiology, pathogenesis, diagnosis and treatment. *Orphanet J Rare Dis* 2021; **16**(1): 281.

[8] Song Y, Wang Z, Hao Z, Li L, Lu J, Kang H, et al. Requirement for etoposide in the treatment of pregnancy related hemophagocytic lymphohistiocytosis: A multicenter retrospective study. *Orphanet J Rare Dis* 2019; **14**(1): 50.

[9] Teng CL, Hwang GY, Lee BJ, Wang RC, Chou MM. Pregnancy-induced hemophagocytic lymphohistiocytosis combined with autoimmune hemolytic anemia. *J Chin Med Assoc* 2009; **72**(3): 156.

Publisher's note

The Publisher of the *Journal* remains neutral with regard to jurisdictional claims in published maps and institutional affiliations.

Edited by Pan Y, Lei Y, Zhang Q