

Case Report

Asian Pacific Journal of Tropical Medicine

apjtm.org

doi: 10.4103/apjtm.apjtm_6_25

# The first fatal case of *Fereydounia khargensis* peritonitis

Siti Nazihah Ab Karim[1], Siti Zulaikha Zakariah[1], Salina Mohamed Sukur[2]✉, Tengku Zetty Maztura Tengku Jamaluddin[1]

[1]*Department of Microbiology, Faculty of Medicine and Health Sciences, Universiti Putra Malaysia, Serdang, Selangor, Malaysia*

[2]*Bacteriology Unit, Infectious Disease Research Centre, Institute for Medical Research, National Institutes of Health, Shah Alam, Malaysia*

## ABSTRACT

**Rationale:** *Fereydounia* (*F.*) *khargensis* is a novel yeast species identified in 2014 from environmental samples and has emerged as a rare pathogen causing human infections.

**Patient concerns:** A 61-year-old male with end-stage renal failure on continuous ambulatory peritoneal dialysis, who presented with generalized abdominal pain, turbid dialysate and fever.

**Diagnosis:** Peritoneal fluid culture revealed the presence of yeast cells. *F. khargensis* was identified by polymerase chain reaction method.

**Interventions:** Removal of Tenckhoff catheter and intravenous fluconazole.

**Outcomes:** He succumbed after two weeks of hospitalization.

**Lessons:** This case report highlights the significance of a rare fungal pathogen, *F. khargensis*, which has been implicated in the mortality of an immunocompromised patient. Due to its rarity, *F. khargensis* poses significant challenges associated with its identification and has profound implications for clinical practice.

**KEYWORDS:** *Fereydounia khargensis*; Peritonitis; Rare; Fungal; Fatal

## 1. Introduction

*Fereydounia* (*F.*) *khargensis* was first identified in 2014 from plant material on Kharg Island in Iran's Persian Gulf. This yeast belongs to the order Urocystidales[1,2]. A study in Mooi River, South Africa, found *F. khargensis* at the furthest downstream sampling site[3]. Another study in Brazil detected *F. khargensis* present in healthcare air environments[4]. These findings indicate that *F. khargensis* is present in various environments.

Malaysia was the first country to report 2 cases of human infections with this organism in blood and peritoneal fluid in 2016[5]. The third case was reported in China, where *F. khargensis* caused catheter-related bloodstream infections[6]. Our case represents the fourth reported human infection and the first fatal case.

## 2. Case history

A 61-year-old male with end-stage renal failure on continuous ambulatory peritoneal dialysis presented with generalized abdominal pain, cloudy dialysate, and fever for two days. The full blood count results were unremarkable, while the C-reactive protein (CRP) level was elevated at 56.87 mg/L (reference range: 0-5 mg/L). Peritoneal fluid analysis showed a white blood cell count of 45 cells/mm$^3$ , with all cells being polymorphonuclear leukocytes. Peritoneal fluid was submitted for culture, and intraperitoneal ceftazidime and cefazolin were initiated. Gram staining of the peritoneal fluid samples revealed yeast cells. In light of the preliminary findings, the managing team administered intravenous fluconazole 200 mg, and the Tenckhoff

✉To whom correspondence may be addressed. E-mail: drsalina_msukur@moh.gov.my

This is an open access journal, and articles are distributed under the terms of the Creative Commons Attribution-Non Commercial-ShareAlike 4.0 License, which allows others to remix, tweak, and build upon the work non-commercially, as long as appropriate credit is given and the new creations are licensed under the identical terms.

**For reprints contact:** reprints@medknow.com

©2025 *Asian Pacific Journal of Tropical Medicine* Produced by Wolters Kluwer-Medknow.

**How to cite this article:** Karim SNA, Zakariah SZ, Sukur SM, Jamaluddin TZMT. The first fatal case of *Fereydounia khargensis* peritonitis. Asian Pac J Trop Med 2025; 18(8): 372-375.

**Article history:** Received 15 January 2025 Revision 17 July 2025
Accepted 21 July 2025 Available online 29 August 2025

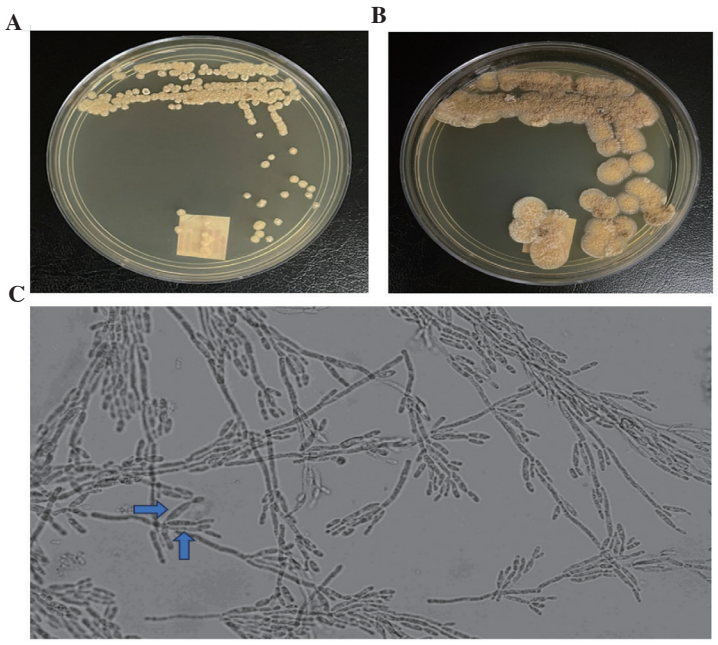


**Figure 1.** (A) Sabouraud dextrose agar displaying beige to cream, wrinkled colonies with fringed margins, observed on day 3 of incubation (plate positioned in front). (B) Sabouraud dextrose agar exhibiting cream to tan, wrinkled colonies with fringed margins, observed on day 9 of incubation, indicating a change in growth characteristics (plate positioned in front). (C) Microscopic view of slide culture displaying septate and hyaline hyphae, featuring branching conidiophores with sterigmata-like structures (blue arrows) that bear short chains of ovoid to ellipsoidal conidia (×40 magnification) in a 61-year-old male diagnosis with *Fereydounia khargensis* peritonitis.

catheter was removed. Dialysis was subsequently performed *via* hemodialysis using an internal jugular vein catheter (IJC). HIV serology returned non-reactive. Tenckhoff catheter tip and blood cultures yielded no growth. After one week of hospitalization, the patient was discharged with oral fluconazole 200 mg once daily for an additional two weeks. Five days post-discharge, the patient returned to the hospital because of a fever with tachycardia. His full blood count revealed a thrombocytopenia of $89\times10^6$/L (reference range: 150-400×$10^6$/L), and an increased CRP level of 74.46 mg/L (reference range: 0-5 mg/L), indicating severe systemic infection. In response to his deteriorating condition, the patient was treated with intravenous meropenem 500 mg and continued on intravenous fluconazole 200 mg. The patient's condition continued to decline, and he succumbed after two weeks of hospitalization.

## 3. Microbiology diagnosis

The peritoneal fluid was cultured using Sabouraud Dextrose Agar (SDA), colony morphology is shown in Figure 1A and 1B. The yeast produced dark green colonies on chromogenic agar. The urease test was positive. A slide culture on cornmeal agar was also performed (Figure 1C). However, the isolate could not be identified using matrix-assisted laser desorption/ionization time-of-flight mass spectrometry (MALDI-TOF).

The polymerase chain reaction (PCR) was conducted using primers Internal Transcribed Spacer (ITS) 1 and ITS 4 for amplification. The sequences of PCR amplicons were analyzed using the Basic Local Alignment Search Tool (BLAST) program from the National Center for Biotechnology Information (NCBI) to identify the organism. The sequence analysis revealed a 99.87% similarity to *F. khargensis*, with the accession number MK592780.1.

Antifungal susceptibility testing was performed using the Sensititre YeastOne method. The minimum inhibitory concentration (MIC) values obtained were flucytosine >64 μg/mL, amphotericin B 8 μg/mL, anidulafungin >8 μg/mL, caspofungin >8 μg/mL, fluconazole 4 μg/mL, itraconazole 0.25 μg/mL, micafungin >8 μg/mL, posaconazole 0.25 μg/mL, and voriconazole 0.12 μg/mL. There are no established antifungal breakpoints for *F. khargensis*. The management of the previous report cases and the MIC values are compared in Supplementary Tables 1 and 2.

Yeast was identified in the peritoneal fluid before the patient's death, prompting early initiation of intravenous fluconazole. However, species identification and antifungal susceptibility testing

were only available after the patient passed away, as the process took approximately one month due to outsourcing to a reference laboratory. The isolate demonstrated a high MIC to fluconazole, indicating reduced susceptibility. As a result, empirical therapy was continued. Timely availability of susceptibility data could have guided more appropriate antifungal selection.

## 4. Discussion

*F. khargensis* infection has been associated with bacteremia, catheter-related bloodstream infections, and peritoneal dialysis peritonitis. This pathogen has been observed in immunocompromised patients, particularly those with HIV infection and end-stage renal failure. The hallmark symptom presented by these patients is typically fever.

Peritoneal dialysis peritonitis is a distinct type of peritonitis directly associated with the use of peritoneal dialysis and its related procedures. Diagnostic imaging, especially computed tomography scans and ultrasound, plays a vital role in the evaluation of peritonitis. While they are not primarily used for diagnosis, these imaging modalities are essential for assessing the extent and source of the infection, identifying complications, and facilitating percutaneous drainage when warranted[7].

*F. khargensis* is morphologically unique, displaying dry, cream-colored colonies with slightly wrinkled, fringed margins on SDA. The colonies start to produce melanin-like pigment and darken with longer incubation. Slide cultures on cornmeal agar displayed the formation of retraction septate hyphae, pseudohyphae, and ballistoconidia were formed terminally on sterigma-like structures, which are distinct characteristics compared to other known yeasts[1]. Furthermore, the identification process was complicated by the inability of MALDI-TOF to identify the isolate due to a lack of a database[5,8]. Fortunately, molecular methods facilitated the identification process. If species identification and antifungal susceptibility testing had been available earlier, it could have guided more effective antifungal therapy and potentially altered the clinical course.

The International Society for Peritoneal Dialysis guidelines recommend immediate catheter removal and appropriate antifungal therapy for peritonitis caused by non-Candida yeast species[9]. The low MIC values observed for the azole group in the antifungal susceptibility tests conducted in this study indicate the *in vitro* effectiveness of these agents in inhibiting the growth of *F. khargensis*. However, it is essential to relate the MIC values to established clinical breakpoints to assess the potential effectiveness of antifungal therapy *in vivo*[10]. Thus, antifungal treatment can be challenging due to the lack of specific treatment guidelines and antifungal clinical breakpoints for this rare organism.

In conclusion, *F. khargensis* is a rare fungal species that presents significant challenges in clinical identification and treatment. The implications for clinical practice are profound, as early recognition and appropriate antifungal therapy are crucial for improving patient outcomes.

## Ethics approval and consent to participate

Publication of this case report was approved by the National Medical Research Register of Malaysia, with registration number NMRR-25-00813-MGA.

## Consent for publication

Written informed consent was obtained from the family of the patient for publication of this case report.

## Conflict of interest statement

The authors declare that they have no conflict of interest.

## Acknowledgments

We acknowledge Dr. Nor Zanariah Zainol Abidin from the Microbiology Unit, Pathology Department, Hospital Tuanku Ja'afar Seremban, Negeri Sembilan, Malaysia, as well as Stephanie Jane Ginsapu and Nurania Amisya Md Zul Hairi from the Institute for Medical Research Malaysia, for their tremendous assistance with this case. We also gratefully acknowledge the Director General of Health Malaysia for his permission to publish this case report. We are also thankful for the great support from the head of the department, and aid of the technical staff.

## Funding

This research did not receive any specific grant from funding agencies in the public, commercial, or not-for-profit sectors.

## Authors' contributions

AK, SN: first author, concept, design, data acquisition, manuscript

preparation, editing, and review. ZSZ: concept, design, manuscript preparation, editing, and review. MSS: concept, design, supervised the microbiology diagnostic aspect of the case, manuscript preparation, editing, and review, correspondence author. TJ, TZM: concept, design, manuscript preparation, editing, and review, senior author. The submitted version of the manuscript has been reviewed and approved by all authors. The authors confirm that the criteria for authorship have been fulfilled, and each author asserts that the manuscript reflects their genuine contributions and integrity in research.

## References

[1] Nasr S, Soudi MR, Shahzadeh Fazeli SA, Nguyen HDT, Lutz M, Piątek M. Expanding evolutionary diversity in the Ustilaginomycotina: Fereydouniaceae fam. nov. and *Fereydounia* gen. nov., the first urocystidalean yeast lineage. *Mycol Progress* 2014; **13**(4): 1012.

[2] Wang QM, Begerow D, Groenewald M, Liu XZ, Theelen B, Bai FY, et al. Multigene phylogeny and taxonomic revision of yeasts and related fungi in the Ustilaginomycotina. *Stud Mycol* 2015; **81**(1): 55-83.

[3] Monapathi M, Horn S, Vogt T, Van Wyk D, Mienie C, Ezeokoli OT, et al. Antifungal agents, yeast abundance and diversity in surface water: Potential risks to water users. *Chemosphere* 2021; **274**: 129718.

[4] Do Nascimento JPM, Dos Santos R, Dos Santos Silva MS, De Araújo MA, Anhezini L, Dos Santos DÉ, et al. Indoor air contamination by yeasts in healthcare facilities: Risks of invasive fungal infection. *Aerobiology* 2023; **1**(1): 3-18.

[5] Tap RM, Ramli NY, Sabaratnam P, Hashim R, Bakri ARA, Bee LB, et al. First two cases of fungal infections associated with multi-drug resistant yeast, *Fereydounia khargensis*. *Mycopathologia* 2016; **181**: 531-537.

[6] Zhang Q, Xie M, Liu Y, Chen D, Xie W, Zhang M, et al. First reported case of catheter-related bloodstream infection (CRBSI) caused by *Fereydounia khargensis* in an end-stage kidney disease patient. *medRixv* 2024. doi: https://doi.org/10.1101/2024.11.20.24317364.

[7] Taylor PM. Image-guided peritoneal access and management of complications in peritoneal dialysis. *Semin Dial* 2002; **15**(4): 250-258.

[8] Lu JJ, Lo HJ, Lee CH, Chen MJ, Lin CC, Chen YZ, et al. The use of MALDI-TOF mass spectrometry to analyze commensal oral yeasts in nursing home residents. *Microorganisms* 2021; **9**(1): 142.

[9] Li PKT, Chow KM, Cho Y, Fan S, Figueiredo AE, Harris T, et al. ISPD peritonitis guideline recommendations: 2022 update on prevention and treatment. *Perit Dial Int* 2022; **42**(2): 110-153.

[10]Otto WR, Arendrup MC, Fisher BT. A practical guide to antifungal susceptibility testing. *J Pediatr Infect Dis Society* 2023; **12**(4): 214-221.

## Publisher's note

The Publisher of the *Journal* remains neutral with regard to jurisdictional claims in published maps and institutional affiliations.

Edited by Pan Y, Lei Y, Zhang Q

**Supplementary Table**

**Supplementary Table 1.** Reported cases of *Fereydounia khargensis* infection.

| Year | Source/Sample | Comorbid | Treatment | Outcome | Country |
|---|---|---|---|---|---|
| 2016 | Blood | HIV | Amphotericin B was administered for 1 week; since the patient did not improve, the treatment was changed to IV itraconazole 200 mg twice daily for 2 days, followed by IV itraconazole 200 mg once daily for 12 days | Alive | Kota Kinabalu, Sabah, Malaysia |
| 2016 | Peritoneal Fluid | ESRF on CAPD | Fluconazole 400 mg once daily for 10 days | Alive | Muar, Johor, Malaysia |
| 2024 | Blood from peripheral and central. Catheter tip | ESRF on HD - CRBSI | IV voriconazole 400 mg once daily for 18 days | Alive | Suizhou, China. |
| 2025 | Peritoneal fluid | ESRF on CAPD | IV fluconazole 200 mg once daily for 33 days | Passed Away | Seremban, Negeri Sembilan, Malaysia |

**Supplementary Table 2.** Antifungal susceptibility test on reported cases of *Fereydounia khargensis* infection.

| **Antifungal** | **Tap et al Case 1 (Etest method)** | **Tap et al Case 2 (Etest method)** | **Zhang et al (Sensititre YeastOne method)** | **This case (Sensititre YeastOne method)** |
|---|---|---|---|---|
| Flucytosine | - | - | 64 | >64 |
| Amphotericin B | >32 | 16 | 0.5 | 8 |
| Anidulafungin | >32 | >32 | 0.25 | >8 |
| Caspofungin | >32 | 2 | 2 | >8 |
| Micafungin | - | - | 8 | >8 |
| Fluconazole | 0.5 | 3 | 4 | 4 |
| Itraconazole | 0.047 | 0.094 | 0.03 | 0.25 |
| Posaconazole | - | - | 0.06 | 0.25 |
| Voriconazole | 0.008 | 1 | 0.06 | 0.12 |