OPEN ACCESS

[DOI]10.12016/j.issn.2096-1456.202660048

·防治实践·

甲硝唑相关Stevens-Johnson综合征1例及文献回顾

石海波[1,2]，　刘长阳[1,2]，　那思家[1,3]，　李兴强[1,2]

1.西安交通大学口腔医院 陕西省颅颌面精准医学研究重点实验室，陕西 西安(710004)；　2.西安交通大学口腔医院头颈肿瘤外科，陕西 西安(710004)；　3.西安交通大学口腔医院口腔外科，陕西 西安(710004)

【摘要】　目的　分析甲硝唑相关史蒂文斯-约翰逊综合征(Stevens-Johnson syndrome，SJS)的临床特征及诊疗方案，为口腔围手术期用药安全提供临床参考。**方法**　获得单位伦理委员会批准，遵循赫尔辛基宣言，回顾性纳入1例下颌阻生牙拔除术后口服甲硝唑后发病的SJS病例。对中国知网、万方、PubMed、Web of Science数据库中报道的甲硝唑相关SJS病例进行检索及文献复习，分析人口学特征、用药方案、发病潜伏期、临床体征、干预措施及预后结局。**结果**　本院1例SJS患者临床表现为唇部肿胀，口腔黏膜广泛糜烂、溃疡，伴剧烈吞咽疼痛，躯干及四肢出现散在红斑、水疱，尼氏征阳性；会阴部皮肤、阴茎头表面黏膜出现糜烂，阴囊皮肤剥脱。经停用甲硝唑，先后予以糖皮质激素、免疫调节剂、静脉注射免疫球蛋白及血浆置换等综合救治后病情逐步缓解，随访14个月仅遗留轻度眼干，皮肤黏膜未遗留明显瘢痕，无其他严重后遗症，该病例因早期未能及时识别预警症状，存在停药与临床干预延迟问题。文献复习检索到6例甲硝唑相关SJS病例，其中男3例、女3例，年龄31~61岁，中位年龄45.5岁；甲硝唑用于十二指肠溃疡穿孔修补术后败血症抗感染、消化系统感染、黏膜病、盆腔炎、脓毒性蜂窝织炎合并肺炎及牙龈炎抗感染治疗各1例；给药途径包括口服2例、静脉给药3例、局部外用1例；用药至发病潜伏期0.25~7 d，中位潜伏期4 d。全部病例均见口腔黏膜糜烂，有5例尼氏征阳性。临床均以停用致敏药物为基础治疗，部分联合免疫调控、对症支持及多学科协作诊疗。预后个体差异较大，采用“停药+糖皮质激素+支持治疗”方案的4例中，3例痊愈，1例好转，采用“停药+单纯支持治疗”方案的2例中，1例痊愈，1例死亡。**结论**　甲硝唑相关SJS虽临床罕见，但进展迅猛，口腔黏膜损害普遍，发病多集中于用药后1周内。早期停用致敏药物并尽早启动糖皮质激素干预可改善患者预后。口腔围手术期应严格把控甲硝唑用药指征、强化早期症状监测预警并建立多学科协作诊疗模式，从源头降低重症药物不良反应发生风险。

【关键词】　甲硝唑；　史蒂文斯-约翰逊综合征；　口腔围手术期；　药物不良反应；　用药安全；　临床防治；　预后分析

【中图分类号】　R78　**【文献标志码】**　A　**【文章编号】**　2096-1456(2026)07-0688-08

【引用著录格式】　石海波，刘长阳，那思家，等. 甲硝唑诱发Stevens-Johnson综合征1例及文献回顾[J]. 口腔疾病防治, 2026, 34(7): 688-695. doi:10.12016/j.issn.2096-1456.202660048.

微信公众号

Metronidazole-related Stevens-Johnson syndrome: a case report and literature review

SHI Haibo[1,2], LIU Changyang[1,2], NA Sijia[1,3], LI Xingqiang[1,2].　1. Shaanxi Key Laboratory of Precision Medicine for Craniofacial Diseases, Stomatological Hospital of Xi′an Jiaotong University, Xi′an 710004, China;　2. Department of Head and Neck Oncology, Stomatological Hospital of Xi′an Jiaotong University, Xi′an 710004, China;　3. Department of Oral Surgery, Stomatological Hospital of Xi′an Jiaotong University, Xi′an 710004, China

Corresponding author: LI Xingqiang, Email: lixingqiang800825@163.com; Na Sijia, Email: sijiana@xjtu.edu.cn

【Abstract】　Objective　To analyze the clinical characteristics and management strategies of metronidazole-

【收稿日期】2026-01-29；　**【修回日期】**2026-06-05

【基金项目】陕西省卫生健康口腔颌面外科科研创新团队项目(2024TD-19)

【作者简介】石海波，主治医师，Email：1253788014@qq.com

【通信作者】李兴强，副主任医师，Email：lixingqiang800825@163.com；那思家，副主任医师，Email：sijiana@xjtu.edu.cn

associated Stevens-Johnson syndrome (SJS), and to provide a clinical basis for medication safety during the oral perioperative period. **Methods** The study adhered to the tenets of the Declaration of Helsinki and was approved by the Ethics Committee of Stomatological Hospital of Xi′an Jiaotong University. A retrospective analysis was conducted on a case of SJS following mandibular impacted tooth extraction, for which the patient had taken metronidazole. Additionally, a literature review was performed by searching databases including China National Knowledge Infrastructure, Wanfang, PubMed, and Web of Science to identify reported cases of metronidazole-associated SJS. Demographic features, medication regimens, latency periods, clinical signs, interventions, and prognosis were analyzed. **Results** The patient presented with lip swelling, extensive erosion and ulceration of the oral mucosa, and severe odynophagia. Scattered erythematous macules and bullae were observed on the trunk and extremities, with a positive Nikolsky sign. Additionally, there was erosion of the perineal skin and glans penis mucosa, along with skin desquamation of the scrotum. The patient with SJS was managed in the hospital by discontinuing metronidazole and administering sequential treatments, including glucocorticoids, immunomodulators, intravenous immunoglobulin, and plasma exchange. The condition gradually improved; after a 14-month follow-up, only mild dry eye remained, with no significant scarring of the skin or mucosa. However, delayed recognition of early warning signs resulted in delayed drug withdrawal and intervention. The literature review identified 6 additional cases (3 males, 3 females) with a median age of 45.5 years (range 31 – 61). Indications for metronidazole included postoperative sepsis prophylaxis after duodenal ulcer perforation repair, digestive system infections, mucosal diseases, pelvic inflammatory disease, septic cellulitis with pneumonia, and gingivitis. Administration routes comprised oral (n = 2), intravenous (n = 3), and topical (n = 1). The latency period from drug administration to onset ranged from 0.25 to 7 days (median 4 days). All of the cases presented with oral mucosal erosion, and a positive Nikolsky's sign was noted for five patients. Discontinuation of the causative drug was the cornerstone of treatment, supplemented by immunomodulatory therapy, symptomatic support, and multidisciplinary collaboration. Prognoses varied significantly: among the four patients treated with "drug withdrawal + glucocorticoids + supportive care," three recovered fully and one improved; among the two patients receiving "drug withdrawal + simple supportive care," one recovered and one died. **Conclusion** Although metronidazole-associated SJS is rare, it progresses rapidly and frequently involves oral mucosal damage, typically occurring within one week of administering the medication. Early drug withdrawal and prompt initiation of glucocorticoid therapy can improve prognosis. During the oral perioperative period, strict adherence to metronidazole indications, enhanced monitoring for early warning symptoms, and the establishment of a multidisciplinary collaborative diagnosis and treatment model are essential to minimize the risk of severe adverse drug reactions.

【Key words】 metronidazole; Stevens-Johnson syndrome; oral perioperative period; adverse drug reaction; medication safety; clinical prevention and treatment; prognostic analysis
J Prev Treat Stomatol Dis, 2026, 34(7): 688-695.

甲硝唑(metronidazole)是口腔颌面外科围手术期常用的高效抗厌氧菌药物,对牙龈卟啉单胞菌、中间普氏菌等口腔常见厌氧菌有良好抗菌活性[1-2],广泛应用于阻生智齿拔除、颌面部感染手术的感染预防与控制。临床常规剂量下甲硝唑不良反应发生率约1%,以胃肠道不适、头晕、味觉异常等轻微反应为主[3-6]。史蒂文斯-约翰逊综合征(Stevens-Johnson syndrome, SJS)作为甲硝唑极为罕见但病情凶险的严重皮肤黏膜不良反应,起病急骤、进展迅速,可广泛累及眼、口腔及泌尿生殖道黏膜,严重者可出现多器官损害,总体病死率可达5%~15%[7]。

口腔围手术期患者常因手术应激引发免疫紊乱,局部组织损伤释放的炎症介质可进一步激活机体免疫细胞;若叠加药物致敏因素,炎症微环境可增强免疫细胞对药物半抗原的识别敏感性,放大免疫损伤级联反应,进而升高SJS发病风险[8-12];同时,SJS早期表现为口腔黏膜广泛充血水肿、糜烂、水疱形成及表皮剥脱等表现,因发生于口腔围手术期,其急性黏膜损害易被临床医生误判为术后常规创伤反应,导致诊疗延误[7]。笔者报道口腔围手术期甲硝唑相关SJS病例1例,并进行文献回顾学习,系统梳理甲硝唑相关SJS的临床特征与诊疗要点,旨在揭示口腔围手术期用药风险隐患,为临床安全合理用药提供参考。

1　资料和方法

本研究遵循赫尔辛基宣言，经医院伦理委员会批准（审批号：2026-XJKQIEC-KY-QT-0027-001），且病例资料及图片的使用均获得患者的书面知情同意，符合医学伦理规范。

1.1　本院口腔围手术期甲硝唑相关SJS病例来源

本研究纳入2025年笔者所在医院口腔颌面外科收治的1例下颌阻生牙拔除术后口服甲硝唑诱发的SJS病例，病例资料完整，涵盖病史、术前诊疗、手术经过、用药方案、症状演变、实验室检查、全程干预措施及随访数据，用以总结本例围手术期SJS发病经过与临床救治经验。

1.2　甲硝唑相关SJS文献回顾

为系统归纳甲硝唑相关SJS的临床特征，笔者检索国内外已发表文献开展汇总分析。以“甲硝唑”、“metronidazole”、“史蒂文斯-约翰逊综合征”、“Stevens-Johnson syndrome”、“SJS”为关键词，检索中国知网、万方、PubMed、Web of Science数据库（检索时限：建库至2025年10月）。纳入标准：①明确使用甲硝唑后出现SJS临床表现，且排除其他明确致敏药物；②病例资料完整，包含用药场景、给药途径、发病时间、临床症状、诊疗流程及预后信息；③排除合并严重免疫缺陷、恶性肿瘤等影响预后的基础疾病病例。最终纳入6例文献病例。

由2名口腔颌面外科主治医师独立提取这6例文献病例的核心信息，内容包括：①人口学特征：性别、年龄；②用药特征：用药场景、给药途径、剂量及疗程；③临床特征：用药至发病时间、首发症状、黏膜及皮肤受累部位、典型体征；④诊疗与预后：治疗方案、症状愈合时间、后遗症及远期预后。提取完成后交叉核对，对存在分歧的条目，由1名资深口腔颌面外科主任医师查阅原始资料后判定，最终达成100%数据一致性，确保数据提取的客观性与准确性。

采用Excel 2021软件完成数据整理与描述性统计分析。计量资料以中位数（范围）表示，计数资料以例数表示。

2　结　果

2.1　本院病例详细资料

患者，男，51岁，因“要求拔除左侧下颌阻生智齿”来笔者所在医院口腔颌面外科就诊。

患者来本院10 d前因“左侧下颌阻生智齿伴颌面部间隙感染”于基层医院就诊时，初始接受静脉抗感染治疗：奥硝唑注射液（0.5 g，每12小时1次）联合头孢呋辛钠注射液（1.5 g，每日3次）。治疗第4天起加用地塞米松注射液（5 mg，每日1次），上述联合方案持续治疗7 d后，颌面部间隙感染得到有效控制，局部肿胀、疼痛症状消退。术前3 d停用奥硝唑注射液及头孢呋辛钠注射液，期间未使用其他药物，于笔者所在医院进一步行病灶牙拔除术。

既往无药物过敏史，无高血压、糖尿病、自身免疫性疾病等系统性疾病史，否认吸烟、饮酒史。

检查：体温36.8 ℃，脉搏78次/分，呼吸18次/min，血压125/80 mmHg。神志清楚，精神可，颌面部无明显肿胀，皮肤无红肿、皮疹，张口度正常，口腔黏膜无糜烂、溃疡，左侧下颌第三磨牙区无明显压痛，无活动性感染体征。

治疗：经患者签署知情同意书在局部麻醉下实施“左下颌阻生第三磨牙拔除术”。以2%利多卡因注射液5 mL行左下牙槽神经、舌神经阻滞麻醉，待麻醉起效后，进行翻瓣去骨，采用涡轮机分牙法完整拔除患牙，出血量约5 mL，术后创口常规缝合，无菌纱布压迫止血。为预防术后感染，术后开具口服甲硝唑片（安徽贝克生物制药有限公司，批号247270503）（每次0.2 g，每日3次），嘱患者规律服用，告知用药后可能出现的胃肠道不适等轻微不良反应及注意事项。

不良反应进展：术后24 h：患者出现眼部不适，表现为双眼结膜充血、异物感，未予特殊处理，症状呈进行性加重；术后3 d：出现唇部肿胀，口腔黏膜广泛糜烂、溃疡，伴剧烈吞咽疼痛，无法正常进食（图1a）；术后4 d：躯干（图1b）及四肢出现散在红斑（图1c），部分呈典型靶形损害，有水疱形成，尼氏征阳性；会阴部皮肤、阴茎头表面黏膜出现糜烂，阴囊皮肤剥脱（图1 d）。

实验室检查：血常规示白细胞计数12.5×10^9/L（正常参考值3.5~9.5×10^9/L），嗜酸性粒细胞计数0.3×10^9/L（正常参考值0.02~0.52×10^9/L）；炎症因子检测：白细胞介素-6（interleukin-6，IL-6）17.22 pg/mL（正常参考值 < 5.4 pg/mL），肿瘤坏死因子-α（tumor necrosis factor-alpha，TNF-α）3.2 pg/mL（正常参考值0~8.1 pg/mL）；肝肾功能、电解质等检查均未见明显异常。

诊断与转归：立即转诊至皮肤科会诊，结合患者甲硝唑用药史、典型临床表现（急性起病、皮肤靶形损害、广泛黏膜糜烂、尼氏征阳性），排除天疱

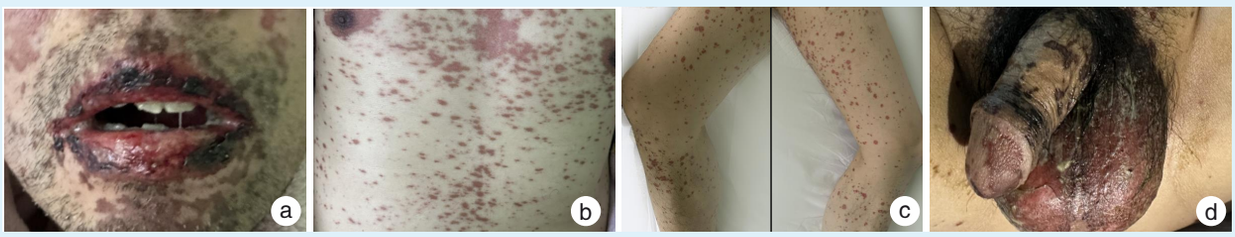

a: erosions and crusting of the lips and buccal mucosa; b & c: scattered erythema on the trunk and on the extremities; d: there was erosion of glans penis mucosa, along with skin desquamation of the scrotum

Figure 1　Manifestations of mucocutaneous lesions in a patient with metronidazole-related Stevens-Johnson syndrome

图1　甲硝唑相关史蒂文斯-约翰逊综合征患者皮肤黏膜损害表现

疮、中毒性表皮坏死松解症(toxic epidermal necrolysis,TEN)等鉴别诊断后,确诊为“史蒂文斯-约翰逊综合征(SJS)”。采用SJS/TEN专属ALDEN(algorithm of drug causality for epidermal necrolysis)评分及通用药物不良反应Naranjo评分评估,结果显示甲硝唑ALDEN评分为4分、Naranjo评分为8分,均判定为“很可能”致敏,综合确认甲硝唑为本次SJS发作的最可能致敏药物。因患者病情典型且危重,未行皮肤活检。治疗上立即停用甲硝唑,初始予甲泼尼龙80 mg,静脉滴注,每日1次;予依那西普50 mg皮下注射,每周2次,该药物仅短期联用3 d,同时联合补液、黏膜保护、眼部护理等对症支持治疗。患者病情进展,持续出现新发皮肤破溃,遂加用静脉注射免疫球蛋白(intravenous immunoglobulin,IVIG)25 g/d,连续治疗5 d,并将甲泼尼龙上调至100 mg,静脉滴注,每日1次,继续维持对症支持治疗。经上述治疗后,患者皮肤仍有新发红疹,提示病情危重,转入重症医学科(intensive care unit,ICU)行强化治疗:给予心电监护、吸氧、营养支持、水电解质平衡维持、器官功能保护等综合支持治疗,未行气管插管,未出现多器官功能衰竭;予血浆置换(plasma exchange,PE)4次,联合甲泼尼龙冲击治疗(第1天300 mg静脉滴注,第2天200 mg静脉滴注,接下来连续6 d 100 mg静脉滴注),全程严密监测生命体征、肝肾功能、炎症指标及皮肤黏膜进展。患者病情缓解后转出ICU,甲泼尼龙继续静脉滴注,每日1次,逐步规律减量:80 mg连续5 d→60 mg静脉滴注3 d;后续改为口服等效剂量泼尼松,并以每7天减量5 mg的速度逐步减量至停药,全程未出现病情反跳。随访14个月时,患者仅遗留轻度眼干不适,症状较半年前随访时明显缓解;口周皮肤无明显色素沉着,背部皮肤可见轻微色素沉着,皮肤及黏膜未见瘢痕形成(图2a、2b)。

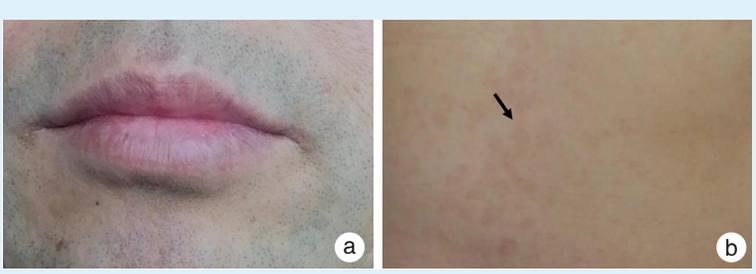

a: no obvious pigmentation or scarring was observed on the vermilion mucosa and perioral skin. b: pigmentation was present at the site of previous erosion on the dorsal skin (indicated by the arrow)

Figure 2　Skin and mucosal recovery in a patient with metronidazole-related Stevens-Johnson syndrome at 14-month follow-up

图2　甲硝唑相关史蒂文斯-约翰逊综合征患者随访14个月皮肤黏膜恢复情况

2.2　文献回顾结果

2.2.1　文献回顾病例人口学与用药特征　6例甲硝唑相关SJS患者中,男性3例,女性3例;年龄区间31~61岁,年龄中位数45.5岁。基础疾病方面,十二指肠溃疡穿孔修补术后1例,合并盆腔炎性反应1例,其余4例无明确基础疾病。用药情况

涉及十二指肠溃疡穿孔修补术后败血症抗感染、消化系统感染、黏膜病、盆腔炎、脓毒性蜂窝织炎合并肺炎及牙龈炎抗感染治疗各1例。给药途径包含口服、静脉给药与局部外用，其中口服给药2例，静脉给药3例，局部外用1例。用药时长0.25~7 d，疗程中位数3 d。甲硝唑常规用法：口服单次0.2~0.4 g，每日2次~3次；局部外用采用0.75%乳膏，每日2次，静脉给药的3例未明确记载具体用药剂量。

2.2.2　文献回顾病例临床特征　用药至发病潜伏期最短0.25 d(6 h)，最长7 d，中位数4 d。首发症状眼部不适及口腔黏膜糜烂1例、口腔黏膜糜烂1例、皮肤红斑/水疱3例、头痛头晕1例。黏膜受累部位：所有病例均出现口腔黏膜糜烂，5例伴眼部黏膜受累，3例伴生殖器黏膜受累。典型体征：5例尼氏征阳性，1例外用给药病例尼氏征阴性。实验室异常：5例白细胞计数升高，4例IL-6升高，2例TNF-α轻度升高，嗜酸性粒细胞均无明显异常。

2.2.3　文献回顾病例诊疗与预后特征　6例甲硝唑相关SJS病例的治疗均以立即停用致敏药物为基础。症状愈合时间为7~21 d(中位数14 d)，其中，4例采用“停药+糖皮质激素+支持治疗”方案，预后为3例痊愈、1例好转；2例采用“停药+单纯支持治疗”方案，预后为1例痊愈、1例死亡。6例中，有3例实施了多学科协作诊疗，包括皮肤科会诊2例、眼科会诊1例。死亡病例为35岁男性，因消化系统感染口服甲硝唑后发病，未接受糖皮质激素治疗，最终因多器官衰竭死亡。

3　讨　论

3.1　SJS诊断及鉴别诊断

SJS是药物或感染诱发的严重皮肤黏膜超敏反应，常累及多器官且预后凶险[1, 13-17]。尽管抗生素、抗癫痫药及非甾体抗炎药为常见诱因[18]，但甲硝唑所致SJS在临床上仍属罕见。眼、口腔、泌尿生殖道黏膜受累是SJS/TEN高度特征性的临床表现，多部位黏膜损害对该病诊断具有较高敏感性与特异性。SJS需与TEN相鉴别，后者以皮肤剥脱面积>30%体表面积为特征[19-20]。

3.2　SJS临床治疗原则与干预策略

SJS治疗应立即停用致敏药物、给予器官支持、炎症控制[21]，国际指南与近年高质量研究均强调早期干预是改善预后的关键[22]。糖皮质激素为SJS一线治疗药物，其通过强效抑制细胞免疫、阻断$CD8^+$T细胞活化、下调IL-6等促炎因子释放、抑制颗粒溶素与Fas-FasL(tumor necrosis factor receptor superfamily member 6/Fas ligand)通路，快速控制上皮细胞凋亡与组织坏死。早期、足量、短程使用可显著降低病情进展风险，减少眼部后遗症与器官损伤，是降低病死率的重要手段[23]。静脉注射免疫球蛋白(intravenous immune globulin，IVIG)可竞争性结合Fas受体、抑制角质形成细胞凋亡，多用于中重度及危重症SJS[23]；血浆置换可快速清除循环致敏药物、免疫复合物及炎症介质，适用于病情进行性加重的危重病例[24]。TNF-α抑制剂(如依那西普)被证实可抑制下游炎症通路，减少皮肤与黏膜持续损伤，近年来已被推荐用于重症SJS辅助治疗[21]。

SJS主要死亡诱因为脓毒症、多器官功能衰竭。延迟停用致敏药物、未及时启动激素干预、多系统受累及广泛性黏膜损伤均为预后不良独立危险因素[22]。

3.3　甲硝唑相关SJS临床特征及用药特征分析

从本院病例临床特征来看，本例为口腔围手术期甲硝唑致敏发病，首发症状集中于眼部与口腔黏膜损伤，后续陆续出现皮损，符合甲硝唑相关SJS以黏膜受累为先的特征[18]。因黏膜病变发生于拔牙术后，易与手术创伤表现混淆，是造成早期识别延迟的重要原因。

综合文献回顾病例总结本病共性临床特征：本病发病窗口期集中于用药1周以内，属于用药早期高发的重症药物不良反应[18]；临床以口腔黏膜糜烂为必有表现，常合并眼、生殖器多部位黏膜损害；在诊疗相关预后特征上，及时停用甲硝唑联合糖皮质激素干预可显著改善预后，错失早期干预时机、仅行对症支持治疗者病情偏重、死亡风险升高[25]。

3.4　甲硝唑相关SJS发病机制与基因易感特征

甲硝唑相关SJS的发病机制尚未完全阐明，目前认为属于$CD8^+$T细胞介导的Ⅳc型迟发型超敏反应[9, 26-27]；甲硝唑代谢产物与组织蛋白结合形成半抗原，诱导T细胞活化，通过颗粒溶素、Fas-FasL通路介导上皮细胞凋亡与坏死[28]。黏膜组织因驻留T细胞丰富、上皮屏障薄弱、药物渗透性更强，成为免疫攻击优先靶点，这也可以解释眼结膜、口腔及泌尿生殖器黏膜损害常早于皮肤损害出现的临床特征[29]。药物基因组学研究提示，药物诱发的SJS/TEN与人类白细胞抗原(human leukocyte anti-

gen，HLA）基因多态性存在关联，特定HLA分子可通过半抗原/前半抗原、药理学免疫受体相互作用（pharmacological interaction with immune receptors，p-i）、肽库改变等模式，与药物或其代谢产物结合并呈递给T细胞受体（T cell receptor，TCR），进而触发系列T细胞活化及针对角质形成细胞的异常免疫反应[30-31]。已有大量研究明确了经典高风险药物与HLA等位基因的强关联，且该关联具有显著的种族特异性：如卡马西平诱发SJS/TEN与东南亚人群的HLA-B15：02强相关（*OR*>100）、别嘌醇相关SJS/TEN与亚裔人群的HLA-B58：01高度关联（*OR*>100）[28，31]，但截至目前，甲硝唑诱发的SJS/TEN目前尚未发现明确的相关易感基因。

3.5　炎症标志物在SJS病情评估中的价值

相关研究证实，IL-6与IP-10可作为SJS/TEN早期预测标志物[32]。IL-6水平与病情活动度及治疗反应密切相关，可用于评估炎症强度并指导治疗[33]。本院甲硝唑相关SJS病例中，IL-6显著升高而TNF-α无明显异常，提示IL-6可能参与甲硝唑相关SJS的炎症调控，为后续机制研究及临床监测提供方向。

3.6　口腔围手术期安全用药防控策略

3.6.1　严格把控甲硝唑用药指征，摒弃“常规预防”理念　目前口腔临床存在“甲硝唑作为拔牙术后常规预防性用药”的认知偏差，违背“有指征用药”原则。根据《口腔颌面外科感染诊疗指南》[34]，甲硝唑术后预防性应用仅适用于感染风险极高的病例（如颌面部间隙感染清创术、智齿冠周炎伴脓肿形成术后）；对于无感染的常规拔牙术、小肿物切除术等操作，无需预防性使用甲硝唑[35-36]。临床需严格遵循“感染风险分层”原则，避免无意义用药，从源头降低不良反应风险。

3.6.2　优化用药选择，规避序贯用药风险　本院病例先后使用奥硝唑与甲硝唑，属于硝基咪唑类药物序贯应用。两类药物化学结构相近，易引发交叉致敏或造成药物蓄积，加重异常免疫反应[37]。目前口腔围手术期对此类用药风险重视不足，普遍缺乏系统化药学监护，增加了重症不良反应的发生概率。同一治疗周期内避免甲硝唑、奥硝唑、替硝唑等硝基咪唑类药物序贯使用，防止交叉致敏或药物蓄积。用药前详细询问过敏史及硝基咪唑类药物接触史，过敏体质者优先选用其他类别抗菌药物。

3.6.3　强化早期监测与识别，建立预警机制　口腔医生作为术后随访的一线人员，应将结膜充血、异物感等眼部症状，以及非术区黏膜糜烂、进行性加重溃疡或疼痛等口腔黏膜异常纳入常规监测，尤其在用药72 h内加强随访。注意区分SJS早期表现与术后正常创伤反应：术后黏膜损伤多局限于术区并逐渐缓解，而SJS黏膜损害范围广、进展快，常伴眼部症状或皮肤红斑。出现上述预警征象时应立即停药并转诊皮肤科，做到早发现、早停药、早转诊。

3.6.4　规范诊疗流程，强化多学科协作　SJS作为多系统受累的严重不良反应，单一科室难以全面救治[20，26]。口腔医生发现疑似症状后，需立即启动多学科协作机制，联合皮肤科明确诊断、制定糖皮质激素治疗方案，联合眼科、口腔黏膜病科处理受累黏膜，联合急诊科保障支持治疗，最大程度降低眼部后遗症、多器官衰竭等不良结局风险[38-39]。治疗原则为“立即停用致敏药物+早期足量糖皮质激素+全面支持治疗”，避免仅依赖支持治疗导致病情进展[16，21，25]。

4　小　结

甲硝唑相关SJS虽罕见但病情凶险、进展迅速，均伴口腔黏膜损害，首发症状多样，可伴眼部不适、皮肤损害等，发病集中于用药后1周内，早期停用甲硝唑并联合糖皮质激素治疗可显著改善预后。口腔围手术期需严格把控用药指征、避免硝基咪唑类药物序贯使用、强化早期症状监测，并建立多学科协作诊疗模式，以降低诊疗风险，保障患者用药安全。

【Author contributions】 Shi HB was responsible for data collection, literature retrieval and manuscript drafting. Liu CY was responsible for data extraction and statistical analysis. Na SJ was responsible for case verification. Li XQ was responsible for study design, manuscript revision and final approval. All authors read and approved the final manuscript as submitted.

【Ethics Statement】 The study adhered to the Declaration of Helsinki and was approved by the Ethics Committee of Stomatological Hospital of Xi′an Jiaotong University (Approval No. 2026-XJKQIEC-KY-QT-0027-001), and written informed consent was obtained from the patient.

【Funding】 This study was funded by Research Innovation Team of Oral and Maxillofacial Surgery of Shaanxi Provincial Health Commission (No. 2024TD-19). The funder had no role in the study design, data collection and analysis, decision to publish, or preparation of the manuscript.

【Competing interests】 All authors have completed the ICMJE uniform disclosure form at www.icmje.org/disclosure-of-interest/ and de-

clare: support from Research Innovation Team of Oral and Maxillofacial Surgery of Shaanxi Provincial Health Commission (No. 2024TD-19) for the submitted work; no financial relationships with any organisations that might have an interest in the submitted work in the previous three years; no other relationships or activities that could appear to have influenced the submitted work.

【Data availability statement】 The original contributions presented in this study are included in the article. Further inquiries can be directed to the corresponding author upon reasonable request.

【Generative AI statement】 The authors declared that generative AI was not used in the creation of this manuscript.

参考文献

[1] Ali J, Rahman M, Ahmad A, et al. Toxic epidermal necrolysis secondary to metronidazole[J]. Cureus, 2021, 13(8): e17101. doi: 10.7759/cureus.17101.

[2] Mehravani M, Houshyar E, Jamalnia S, et al. Effects of local and systemic metronidazole as adjunctive treatment in chronic periodontitis patients[J]. Clin Exp Dent Res, 2024, 10(6): e70050. doi: 10.1002/cre2.70050.

[3] Dilley M, Geng B. Immediate and delayed hypersensitivity reactions to antibiotics: aminoglycosides, clindamycin, linezolid, and metronidazole[J]. Clin Rev Allergy Immunol, 2022, 62(3): 463-475. doi: 10.1007/s12016-021-08878-x.

[4] Lee SJ, Kim J, Lee KH, et al. Frequency and risk factor analysis for metronidazole-associated neurologic adverse events[J]. J Gen Intern Med, 2024, 39(6): 912-920. doi: 10.1007/s11606-023-08566-w.

[5] Retamal-Valdes B, Tavares APL, Monique S, et al. Adverse events of metronidazole and amoxicillin: retrospective analysis of a large data set of five randomized clinical trials[J]. J Clin Periodontol, 2022, 49(11): 1121-1132. doi: 10.1111/jcpe.13704.

[6] Wu Q, Wu F, Jiang H, et al. Safety evaluation of nitroimidazole antibiotics based on the FAERS database[J]. Clin Exp Pharmacol Physiol, 2025, 52(12): e70084. doi: 10.1111/1440-1681.70084.

[7] Mockenhaupt M. Epidemiology of cutaneous adverse drug reactions[J]. Allergol Sel, 2017, 1(1): 96-108. doi: 10.5414/ALX01508E.

[8] Ganio EA, Stanley N, Lindberg-Larsen V, et al. Preferential inhibition of adaptive immune system dynamics by glucocorticoids in patients after acute surgical trauma[J]. Nat Commun, 2020, 11(1): 3737. doi: 10.1038/s41467-020-17565-y.

[9] Martin T, Li H. Severe cutaneous adverse drug reactions: a review on epidemiology, etiology, clinical manifestation and pathogenesis [J]. Chin Med J, 2008, 121(8): 756-761. doi: 10.1097/00029330-200804020-00019.

[10] Albertsmeier M, Quaiser D, von Dossow-Hanfstingl V, et al. Major surgical trauma differentially affects T-cells and APC[J]. Innate Immun, 2015, 21(1): 55-64. doi: 10.1177/1753425913516659.

[11] Ebo DG, Clarke RC, Mertes PM, et al. Molecular mechanisms and pathophysiology of perioperative hypersensitivity and anaphylaxis: a narrative review[J]. Br J Anaesth, 2019, 123(1): e38-e49. doi: 10.1016/j.bja.2019.01.031.

[12] Zhou L, Lu Y, Zou Y, et al. Drug-induced Stevens-Johnson syndrome and toxic epidermal necrolysis: a 10-year retrospective study of 103 cases[J]. Clin Exp Dermatol, 2025, 50(11): 2200-2208. doi: 10.1093/ced/llaf278.

[13] Mazumdar G, Shome K. Stevens-Johnson syndrome following use of metronidazole in a dental patient[J]. Indian J Pharmacol, 2014, 46(1): 121-122. doi: 10.4103/0253-7613.125193.

[14] Chen KT, Twu SJ, Chang HJ, et al. Outbreak of Stevens-Johnson syndrome/toxic epidermal necrolysis associated with mebendazole and metronidazole use among Filipino laborers in Taiwan[J]. Am J Public Health, 2003, 93(3): 489-492. doi: 10.2105/ajph.93.3.489.

[15] Connolly R, Russell S. Acute oromucosal and palmar desquamation: a severe cutaneous adverse reaction to amphotericin and metronidazole[J]. BMJ Case Rep, 2014, 2014: bcr2014205501. doi: 10.1136/bcr-2014-205501.

[16] Chang HC, Wang TJ, Lin MH, et al. A review of the systemic treatment of Stevens - Johnson syndrome and toxic epidermal necrolysis[J]. Biomedicines, 2022, 10(9): 2105. doi: 10.3390/biomedicines10092105.

[17] McPherson T, Exton LS, Biswas S, et al. British association of dermatologists′ guidelines for the management of Stevens - Johnson syndrome/toxic epidermal necrolysis in children and young people, 2018[J]. Br J Dermatol, 2019, 181(1): 37-54. doi: 10.1111/bjd.17841.

[18] Oshikoya KA, Ogunyinka IA, Ogar CK, et al. Severe cutaneous adverse drug reactions manifesting as Stevens-Johnson syndrome and toxic epidermal necrolysis reported to the national pharmacovigilance center in Nigeria: a database review from 2004 to 2017 [J]. Ther Adv Drug Saf, 2020, 11: 2042098620905998. doi: 10.1177/2042098620905998.

[19] Cheever CR, Blasiak RC, Stecher A, et al. Diagnostic sensitivity and specificity of mucosal involvement versus skin biopsy for Stevens-Johnson syndrome/toxic epidermal necrolysis[J]. J Am Acad Dermatol, 2026, 94(4): 1350-1352. doi: 10.1016/j.jaad.2025.12.004.

[20] Pu T, Teng Y, Zhang Y, et al. Immune checkpoint inhibitor-related Stevens-Johnson syndrome and toxic epidermal necrolysis: a retrospective analysis of 21 cases[J]. Front Immunol, 2026, 16: 1734346. doi: 10.3389/fimmu.2025.1734346.

[21] Heuer R, Paulmann M, Mockenhaupt M, et al. Systemic immunomodulating therapies for epidermal necrolysis (Stevens-Johnson syndrome/toxic epidermal necrolysis): a systematic review and meta-analysis[J]. J Dtsch Dermatol Ges, 2026, 24(1): 34-42. doi: 10.1111/ddg.15804.

[22] Lee HY, Creamer D. Drug eruptions[M]. 1st ed. Cham: Springer International Publishing, 2022.

[23] Kim KH, Park SW, Kim MK, et al. Effect of age and early intervention with a systemic steroid, intravenous immunoglobulin or amniotic membrane transplantation on the ocular outcomes of patients with Stevens-Johnson syndrome[J]. Korean J Ophthalmol, 2013, 27(5): 331-340. doi: 10.3341/kjo.2013.27.5.331.

[24] Hama N, Aoki S, Chen CB, et al. Recent progress in Stevens-

Johnson syndrome/toxic epidermal necrolysis: diagnostic criteria, pathogenesis and treatment[J]. Br J Dermatol, 2024, 192(1): 9-18. doi: 10.1093/bjd/ljae321.

[25] Lee HY, Dunant A, Sekula P, et al. The role of prior corticosteroid use on the clinical course of Stevens-Johnson syndrome and toxic epidermal necrolysis: a case-control analysis of patients selected from the multinational EuroSCAR and RegiSCAR studies[J]. Br J Dermatol, 2012, 167(3): 555-562. doi: 10.1111/j. 1365-2133.2012.11074.x.

[26] Thwala BN, Teixeira N, Zitha E, et al. Comment on: proposal for a new diagnostic classification of photodistributed Stevens-Johnson syndrome and toxic epidermal necrolysis[J]. Eur J Med Res, 2024, 29(1): 83. doi: 10.1186/s40001-024-01652-7.

[27] Ahmad F, Mateo JMP, Joy FE, et al. Involvement of B cell subsets in patients with Steven Johnson syndrome/toxic epidermal necrolysis (SJS/TEN)[J]. Allergy, 2026. doi: 10.1111/all.70269.

[28] de Malet Pintos-Fonseca A, Riesco-Dávila L, Mirete-Bachiller S, et al. Association between HLA alleles and adverse drug reactions. Mechanisms involved[J]. Adv Lab Med, 2025, 7(1): 1-9. doi: 10.1515/almed-2025-0118.

[29] Thompson BB, Baker NM, Corey S, et al. Vulvovaginal involvement in Stevens-Johnson syndrome/toxic epidermal necrolysis: a retrospective review at a tertiary care center (2016-2024)[J]. J Am Acad Dermatol, 2026, 94(1): 307-310. doi: 10.1016/j. jaad.2025.09.027.

[30] Chen CB, Chang WC, Wu MY, et al. Attenuation of Wnt/β-catenin signaling in patients with Stevens-Johnson syndrome and toxic epidermal necrolysis[J]. Int J Biol Sci, 2020, 16(2): 353-364. doi: 10.7150/ijbs.32331.

[31] Miyagawa F, Asada H. Current perspective regarding the immunopathogenesis of drug-induced hypersensitivity syndrome/drug reaction with eosinophilia and systemic symptoms (DIHS/DRESS)[J]. Int J Mol Sci, 2021, 22(4): 2147. doi: 10.3390/ijms22042147.

[32] Shiohara T, Mizukawa Y, Aoyama Y. Monitoring the acute response in severe hypersensitivity reactions to drugs[J]. Curr Opin Allergy Clin Immunol, 2015, 15(4): 294-299. doi: 10.1097/ACI.0000000000000180.

[33] Mizukawa Y, Shiohara T. Cytokine profile-guided management of Stevens-Johnson syndrome and toxic epidermal necrolysis (SJS/TEN): a management algorithm useful for guiding the selection of treatment options[J]. Allergol Int, 2026, 75(2): 207-217. doi: 10.1016/j.alit.2025.09.005.

[34] 《口腔颌面部间隙感染治疗中抗菌药物合理应用专家共识》编写组. 口腔颌面部间隙感染治疗中抗菌药物合理应用专家共识[J]. 中华口腔医学杂志, 2025, 60(8): 809-821. doi: 10.3760/cma.j.cn112144-20250506-00168.
Expert Group of Expert Consensus on Rational Use of Antimicrobial Agents in the Treatment of Oral and Maxillofacial Space Infection. Expert consensus on rational use of antimicrobial agents in the treatment of oral and maxillofacial space infection[J]. Chin J Stomatol, 2025, 60(8) : 809-821. doi: 10.3760/cma. j. cn112144-20250506-00168.

[35] Cuevas-Gonzalez MV, Cuevas-Gonzalez JC, Espinosa-Cristóbal LF, et al. Use or abuse of antibiotics as prophylactic therapy in oral surgery: a systematic review[J]. Medicine, 2023, 102(37): e35011. doi: 10.1097/MD.0000000000035011.

[36] Gazal G, Al-Samadani KH, Alsaidalani HM, et al. A comparison of pre-emptive co-amoxiclav, postoperative amoxicillin, and metronidazole for prevention of postoperative complications in dentoalveolar surgery: a randomized controlled trial[J]. Int J Environ Res Public Health, 2022, 19(7): 4178. doi: 10.3390/ijerph19074178.

[37] Bai H, Wang X, Wang Y, et al. Ornidazole induced Stevens-Johnson syndrome without body surface involved: a case report[J]. Medicine, 2024, 103(5): e37164. doi: 10.1097/MD.0000000000037164.

[38] Barea-Jiménez N, Calero J, Molina-Negrón D, et al. Treatment for oral lesions in pediatric patients with Stevens-Johnson's syndrome: a case report and literature review[J]. Int J Paediatr Dent, 2020, 30(4): 489-496. doi: 10.1111/ipd.12615.

[39] 林鹃, 于凡, 李晓娜, 等. 史蒂文斯-约翰逊综合征继发双侧舌侧缘巨大炎性增生物1例并文献复习[J]. 华西口腔医学杂志, 2023, 41(5): 599-603. doi: 10.7518/hxkq.2023.2023086.
Lin J, Yu F, Li XN, et al. Stevens-Johnson syndrome secondary to massive inflammatory hyperplasia of bilateral lingual margins: a case report and literature review[J]. West Chin J Stomatol, 2023, 41(5): 599-603. doi: 10.7518/hxkq.2023.2023086.

（编辑　张琳）

Open Access
This article is licensed under a Creative Commons Attribution 4.0 International License.
Copyright © 2026 by Editorial Department of Journal of Prevention and Treatment for Stomatological Diseases

官网