Advancing Precision Oncology with Predictive Biomarker Testing for Emerging Antibody-Drug Conjugates in Solid Tumors

Xuemin Xue[1,†], Jianfeng Wu[2,†], Ying Yang[3,†], Yuanhao Liu[1], Shun Lu[3,*], Zhe Wang[2,*], Jianming Ying[1,*]

[1] Department of Pathology, National Cancer Center/National Clinical Research Center for Cancer/Cancer Hospital, Chinese Academy of Medical Sciences and Peking Union Medical College, Beijing, China
[2] Department of Pathology, State Key Laboratory of Holistic Integrative Management of Gastrointestinal Cancers, Xijing Hospital and School of Basic Medicine, Fourth Military Medical University, Xi'an, China
[3] Shanghai Chest Hospital, Shanghai Jiao Tong University School of Medicine, Shanghai, China

*__Correspondence:__ Jianming Ying, Department of Pathology, National Cancer Center/National Clinical Research Center for Cancer/Cancer Hospital, Chinese Academy of Medical Sciences & Peking Union Medical College, Beijing 100021, China.
E-Mail: jmying@cicams.ac.cn
Zhe Wang, Department of Pathology, Xijing Hospital and School of Basic Medicine, Fourth Military Medical University, Xi'an 710032, China.
E-Mail: zhwang@fmmu.edu.cn
Shun Lu, Shanghai Chest Hospital, Shanghai Jiao Tong University School of Medicine, Shanghai 200030, China.
E-Mail: shunlu@sjtu.edu.cn

Abstract

Antibody-drug conjugates (ADCs) represent an advanced therapeutic strategy that combines the selective targeting of monoclonal antibodies with potent cytotoxic payloads. The clinical efficacy of ADCs critically depends on accurately identifying patients whose tumors express the target antigen, necessitating robust biomarker assessment. This review aims to systematically consolidate and clarify the methodologies for biomarker testing in ADC therapy for solid tumors, thereby providing a structured framework to facilitate clinical implementation. We focus on ADCs targeting HER2, folate receptor-α, c-MET (cellular mesenchymal–epithelial transition factor), CLDN18.2 and TROP2, with particular emphasis on targets of greater clinical maturity and clearer relevance to biomarker-guided patient selection. Additionally, technological advancements such as multiplex biomarker detection and liquid biopsy techniques further refine tumor characterization, addressing heterogeneity in antigen expression. Moreover, we also discuss emerging artificial intelligence (AI)-driven pathology tools and quantitative continuous scoring systems that enhance biomarker assessment and interlaboratory reproducibility. By enabling more objective and precise biomarker quantification, these approaches may improve predictive performance compared with conventional categorical scoring systems.

[†] These authors contributed equally to this work.

Received: 6 May 2026; **Accepted:** 30 June 2026
DOI: 10.2738/PR.2026.0007

© The Author(s) 2026. This article is published by Higher Education Press at journal.hep.com.cn.
This is an open access article distributed under the Creative Commons Attribution License 4.0 (CC BY), which permits unrestricted use, distribution, and reproduction in any medium, provided the original work is properly cited.

Keywords: antibody-drug conjugates; predictive biomarkers; precision oncology; digital pathology; quantitative continuous scoring

Introduction

Antibody-drug conjugates (ADCs) represent an important targeted therapeutic strategy in oncology, wherein a monoclonal antibody selectively delivers a potent cytotoxic drug to tumor cells expressing a specific antigen. Structurally, an ADC comprises an antibody linked to a cytotoxic payload via a chemical linker[1]. Upon binding to the target on a cancer cell, the ADC is internalized and releases the payload intracellularly, causing tumor cell death while largely sparing normal tissues.

Over the past decade, ADCs have evolved from concept to clinical applications, with multiple agents receiving approval from the U.S. Food and Drug Administration (FDA) for oncology indications. Numerous additional ADC candidates are in development, targeting a diverse array of tumor-associated antigens[2]. Unlike chemotherapy, the efficacy of an ADC depends on the expression of its target antigen on tumor cells and the tumor's sensitivity to the cytotoxic payload. Therefore, patient selection via biomarker testing is critical to identify those most likely to benefit from treatment. For instance, early ADCs, such as gemtuzumab ozogamicin targeting myeloid cell surface antigen cluster of differentiation 33 (CD33) in acute myeloid leukemia and trastuzumab emtansine (T-DM1) approved for human epidermal growth factor receptor 2 (HER2)-positive breast cancer (BC), determined patient eligibility based on tumor antigen expression levels[3]. In recent years, next-generation ADCs featuring enhanced linker technologies and potent payloads have broadened therapeutic potential, enabling treatment of tumors with lower antigen density or those expressing novel targets. Accordingly, treatment response to ADCs cannot be attributed to antigen expression alone, but reflects the combined influence of antigen-related and agent-related factors. This evolution has underscored the critical need for standardized biomarker assays to reliably assess target expression and guide clinical decision-making[4].

Despite these advancements, several challenges remain unresolved: How should emerging biomarkers be tested, and which scoring criteria should be adopted? How should "borderline" levels of antigen expression be interpreted? Can reproducibility and standardization of biomarker testing be ensured across different laboratories? How do intratumoral heterogeneity and dynamic changes in antigen expression over time influence the efficacy of ADCs? Addressing these issues is crucial for optimizing the clinical application of ADCs. This review provides a comprehensive analysis of the most recent literature on predictive biomarker assessment for ADC therapy, focusing on five key ADC targets: HER2, folate receptor-α (FRα), c-MET, claudin 18.2 (CLDN18.2), and trophoblast cell surface antigen 2 (TROP2). Fig. 1 illustrates major ADC targets and the process of antigen binding and internalization. These membrane-bound proteins serve as crucial antigens for targeted ADC delivery, and their differential expression patterns across tumor types have guided the development of multiple ADCs with tissue-selective cytotoxicity.

In this review, we also summarize the clinical development of ADCs targeting these biomarkers and highlight the impact of biomarker-driven patient selection on therapeutic efficacy. Furthermore, we evaluate current methodologies for biomarker detection, including immunohistochemistry (IHC) scoring systems, genomic profiling techniques, and artificial intelligence (AI)-assisted digital pathology approaches, discussing their respective advantages and limitations. We also discuss emerging strategies in ADC biomarker assessment, such as quantitative continuous scoring (QCS), single-cell analytics, liquid biopsies, and molecular imaging, which show significant potential for improving patient stratification. This review aims to provide oncologists, pathologists, and translational researchers with a practically applicable framework for ADC biomarker testing, thereby supporting the integration of ADC therapies into precision practice.

Clinical development and biomarker detection methods for approved and investigational ADCs

This section reviews the clinical development and biomarker testing of approved and investigational ADCs

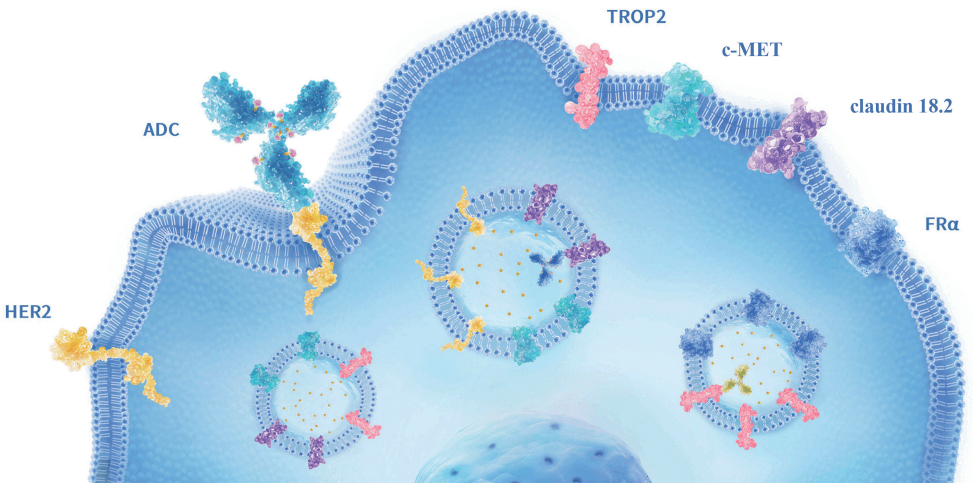

Figure 1: Biomarkers of ADCs in solid tumors

Schematic representation of major cell surface antigens targeted by ADCs in solid tumors. HER2, TROP2, c-MET, claudin 18.2, and FRα are among the most extensively investigated targets. Upon internalization, the cytotoxic payload is released, leading to tumor cell death. Each antigen is illustrated with its corresponding ADC bound to the tumor cell membrane, highlighting specific antigen–ADC interaction and subsequent internalization. This figure was created by the authors. All rights reserved.

targeting HER2, FRα, c-MET, CLDN18.2, and TROP2. The approved indications and companion diagnostic (CDx) information are summarized in Table 1.

HER2 targeted ADCs

HER2 is a transmembrane tyrosine kinase receptor overexpressed in various solid tumors, particularly breast and gastric cancers (GCs), and serves as a well-established therapeutic target for ADCs[5].

T-DM1 for BC

T-DM1 was the first HER2 targeted ADC to receive FDA approval in February 2013 for the treatment of patients with HER2-positive metastatic (late-stage) BC based on its improved outcomes in the phase III EMILIA trial[6]. Subsequently, in May 2019, the FDA expanded the indication to include adjuvant treatment of patients with HER2-positive early BC who have residual invasive disease after neoadjuvant therapy[5] (Table 1).

Trastuzumab deruxtecan (T-DXd) for BC, GC, non-small cell lung cancer (NSCLC), and solid tumors

T-DXd is a next-generation ADC composed of the anti-HER2 monoclonal antibody trastuzumab and a cleavable tetrapeptide-based linker. The cytotoxic payload is an exatecan derivative that functions through inhibition of topoisomerase I (TOP1), with a drug-to-antibody ratio of 8:1. T-DXd has substantially expanded the therapeutic landscape for HER2-expressing cancers[5]. In December 2019, the FDA granted accelerated approval to T-DXd for the treatment of adult patients with unresectable or metastatic HER2-positive BC who had received two or more prior anti-HER2 regimens, based on results from the phase II DESTINY-Breast01 trial demonstrating a high objective response rate (ORR) and durable responses (Table 1)[7]. The landmark DESTINY-Breast03 trial demonstrated the superior efficacy of T-DXd compared to T-DM1 in patients with HER2-positive BC[8]. Furthermore, the DESTINY-Breast04 trial established the clinical benefit of T-DXd in HER2-low BC, defined as IHC 1^+ or 2^+ without *HER2* gene amplification[9]. These findings have established a new therapeutic category encompassing approximately 50% of all BCs (Table 1). HER2-ultralow (IHC 0 with faint staining) is a therapeutically relevant subgroup. An interim analysis of DESTINY-Breast06 led to FDA approval of T-DXd for hormone receptor-positive (HR^+), HER2-low (IHC 1^+ or IHC 2^+/ISH^-), or HER2-ultralow BC in January 2025 (Table 1). In DESTINY-Breast06 ($n = 866$), T-DXd significantly prolonged PFS versus chemotherapy in the overall population with HR-positive, HER2-low or HER2-ultralow metastatic breast cancer (HR, 0.63; 95% CI, 0.53–0.75). In the exploratory HER2-ultralow

Table 1: FDA-approved indications and FDA-authorized companion diagnostics for ADCs used in solid tumors as of May 2025

ADC drug	Target	Payload	FDA-approved indications	FDA-authorized companion diagnostics
Ado-trastuzumab emtansine (T-DM1)	HER2	DM1 (maytansinoid microtubule inhibitor)	HER2-positive metastatic breast cancer after trastuzumab and a taxane, separately or together; patients must have received prior metastatic therapy or relapsed during or within 6 months after completing adjuvant therapy. Single-agent treatment.	HercepTest (IHC); HER2 FISH pharmDx Kit (FISH); FoundationOne CDx (ERBB2 amplification, tissue NGS); PATHWAY anti-HER-2/neu (4B5) Rabbit Monoclonal Primary Antibody (IHC). [FDA-01, FDA-09–FDA-12]
			Adjuvant single-agent treatment of HER2-positive early breast cancer with residual invasive disease after neoadjuvant taxane- and trastuzumab-based treatment.	HercepTest (IHC); HER2 FISH pharmDx Kit (FISH); FoundationOne CDx (ERBB2 amplification, tissue NGS); PATHWAY anti-HER-2/neu (4B5) Rabbit Monoclonal Primary Antibody (IHC). [FDA-01, FDA-09–FDA-12]
Fam-trastuzumab deruxtecan-nxki (T-DXd)	HER2	Deruxtecan (DXd; exatecan-derived TOP1 inhibitor)	Adults with unresectable or metastatic HER2-positive (IHC 3^+ or ISH-positive) breast cancer after an anti-HER2 regimen for metastatic disease, or recurrence during or within 6 months after completing neoadjuvant/adjuvant anti-HER2 therapy.	HER2 IHC/ISH testing; no Enhertu-specific CDx authorized for this HER2-positive breast cancer indication by the cutoff. [FDA-02, FDA-14, FDA-19]
			Adults with unresectable or metastatic HR-positive, HER2-low (IHC 1^+ or IHC 2^+/ISH-negative) or HER2-ultralow (IHC 0 with membrane staining) breast cancer progressing on ≥ 1 endocrine therapy in the metastatic setting.	PATHWAY anti-HER-2/neu (4B5) Rabbit Monoclonal Primary Antibody (IHC; breast tissue); IHC 2^+ requires ISH confirmation of non-amplification. [FDA-02, FDA-13, FDA-14, FDA-21]
			Adults with unresectable or metastatic HER2-low (IHC 1^+ or IHC 2^+/ISH-negative) breast cancer after chemotherapy for metastatic disease, or recurrence during or within 6 months after completing adjuvant chemotherapy.	PATHWAY anti-HER-2/neu (4B5) Rabbit Monoclonal Primary Antibody (IHC; breast tissue); IHC 2^+ requires ISH confirmation of non-amplification. [FDA-02, FDA-13, FDA-14]
			Adults with unresectable or metastatic NSCLC harboring activating *HER2* (ERBB2) mutations, detected by an FDA-approved test, after prior systemic therapy. Accelerated approval.	Oncomine Dx Target Test (tumor tissue); Guardant360 CDx (plasma): activating ERBB2 SNVs and exon 20 insertions. If plasma testing is negative, test tumor tissue. [FDA-02, FDA-15, FDA-16]
Fam-trastuzumab deruxtecan-nxki (T-DXd)	HER2	Deruxtecan (DXd; exatecan-derived TOP1 inhibitor)	Adults with locally advanced or metastatic HER2-positive (IHC 3^+ or IHC 2^+/ISH-positive) gastric or gastroesophageal junction adenocarcinoma after a trastuzumab-based regimen.	HER2 IHC/ISH testing; no Enhertu-specific CDx authorized for this gastric/GEJ indication by the cutoff. [FDA-02, FDA-19]
			Adults with unresectable or metastatic HER2-positive (IHC 3^+) solid tumors after prior systemic treatment, with no satisfactory alternative treatment options. Accelerated approval.	HER2 IHC 3^+ required; the January 2025 label states that an FDA-approved test for this indication was not available. [FDA-02]
Mirvetuximab soravtansine-gynx (MIRV)	FRα	DM4 (maytansinoid microtubule inhibitor)	Adults with FRα-positive, platinum-resistant epithelial ovarian, fallopian tube, or primary peritoneal cancer after 1–3 prior systemic treatment regimens, selected using an FDA-approved test.	VENTANA FOLR1 (FOLR1-2.1) RxDx Assay (IHC; tumor tissue): ≥ 75% of viable tumor cells with moderate (2^+) and/or strong (3^+) membrane staining. [FDA-03, FDA-17]

(*continued*)

Table 1

(continued)

ADC drug	Target	Payload	FDA-approved indications	FDA-authorized companion diagnostics
Sacituzumab govitecan-hziy (SG)	TROP2	SN-38 (TOP1 inhibitor)	Adults with unresectable locally advanced or metastatic triple-negative breast cancer after ≥ 2 prior systemic therapies, including ≥ 1 for metastatic disease.	None specified; TROP2 expression testing is not required. [FDA-04, FDA-19]
			Adults with unresectable locally advanced or metastatic HR-positive, HER2-negative (IHC 0, IHC 1^+, or IHC 2^+/ISH-negative) breast cancer after endocrine-based therapy and ≥ 2 additional systemic therapies in the metastatic setting.	None specified; TROP2 expression testing is not required. [FDA-04, FDA-19]
Datopotamab deruxtecan-dlnk (Dato-DXd)	TROP2	Deruxtecan (DXd; exatecan-derived TOP1 inhibitor)	Adults with unresectable or metastatic HR-positive, HER2-negative (IHC 0, IHC 1^+, or IHC 2^+/ISH-negative) breast cancer after endocrine-based therapy and chemotherapy for unresectable or metastatic disease.	None specified; TROP2 expression testing is not required. [FDA-05, FDA-19]
Enfortumab vedotin-ejfv (EV)	Nectin-4	MMAE (microtubule inhibitor)	In combination with pembrolizumab for adults with locally advanced or metastatic urothelial cancer.	None specified; Nectin-4 expression testing is not required. [FDA-06, FDA-19]
Enfortumab vedotin-ejfv (EV)	Nectin-4	MMAE (microtubule inhibitor)	Single-agent treatment of adults with locally advanced or metastatic urothelial cancer after a PD-1/PD-L1 inhibitor and platinum-containing chemotherapy; or cisplatin-ineligible patients after ≥ 1 prior line of therapy.	None specified; Nectin-4 expression testing is not required. [FDA-06, FDA-19]
Tisotumab vedotin-tftv (TV)	Tissue factor	MMAE (microtubule inhibitor)	Adults with recurrent or metastatic cervical cancer progressing on or after chemotherapy.	None specified; tissue-factor expression testing is not required. [FDA-07, FDA-19]
Telisotuzumab vedotin-tllv (Teliso-V)	c-MET	MMAE (microtubule inhibitor)	Adults with locally advanced or metastatic nonsquamous NSCLC with high c-MET protein overexpression (≥ 50% of tumor cells with strong [3^+] staining), determined by an FDA-approved test, after prior systemic therapy. Accelerated approval.	VENTANA MET (SP44) RxDx Assay (IHC; tumor tissue): ≥ 50% of tumor cells with strong (3^+) membrane and/or cytoplasmic staining. [FDA-08, FDA-18]

FDA source documents are indexed in Supplementary File S1.

Abbreviations: ADC, antibody-drug conjugate; CDx, companion diagnostic; ERBB2, erb-b2 receptor tyrosine kinase 2; FRα, folate receptor-α; GEJ, gastroesophageal junction; HER2, human epidermal growth factor receptor 2; HR, hormone receptor; IHC, immunohistochemistry; ISH, *in situ* hybridization; MMAE, monomethyl auristatin E; NGS, next-generation sequencing; NSCLC, non-small-cell lung cancer; PD-1/PD-L1, programmed death 1/programmed death-ligand 1; SNV, single-nucleotide variant; TOP1, topoisomerase I.

subgroup, median PFS was 13.2 versus 8.3 months (HR, 0.78; 95% CI, 0.50–1.21), and confirmed ORRs were 61.8% versus 26.3%, respectively. These exploratory findings support the antitumor activity of T-DXd in HER2-ultralow disease[10]. For the CDx of T-DXd, the FDA approved the PATHWAY anti-HER2/neu (4B5) assay as a CDx for T-DXd in HER2-low BC in 2022, with a 2025 label expansion to identify HR^+ metastatic HER2-ultralow disease[5,10] (Fig. 2). Although T-DXd has demonstrated robust antitumor activity across the entire HER2 expression spectrum, precise biomarker-guided patient selection remains essential to optimize therapeutic outcomes and minimize unnecessary exposure[1,5].

Beyond BC, T-DXd has also demonstrated promising efficacy in GC. DESTINY-Gastric01 trial, a multicenter, open-label, randomized phase II study, demonstrated superior clinical outcomes of T-DXd in HER2-positive

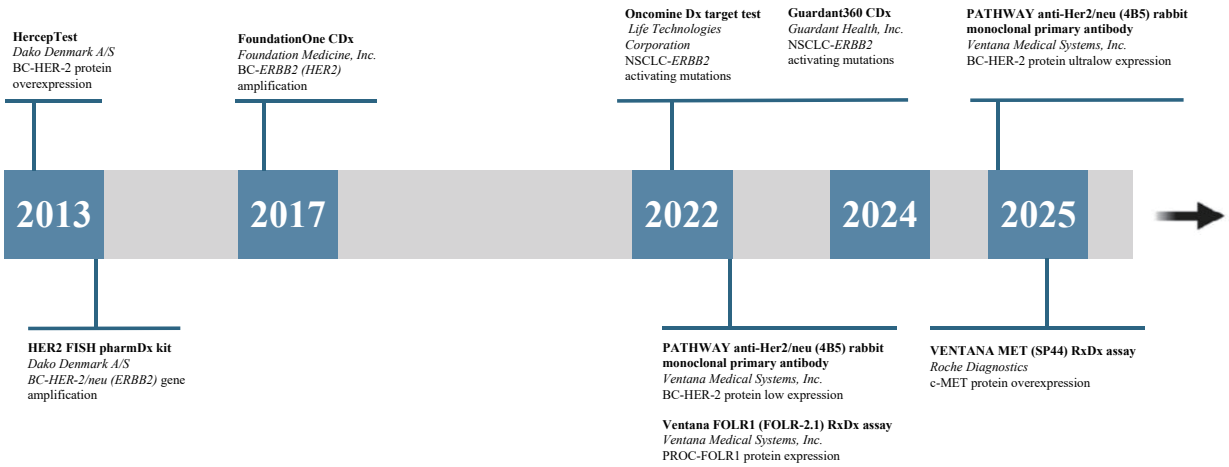

Figure 2: Timeline of approved ADC diagnostic and therapeutic milestones

This timeline depicts FDA-approved companion diagnostic milestones for ADCs from 2013 to May 2025. All data are derived from the official FDA website and are current as of May 2025.

GC, leading to its regular FDA approval on January 15, 2021 (Table 1)[11]. Moreover, T-DXd demonstrated variable antitumor activity in patients with NSCLC. In the DESTINY-Lung01 study, an open-label, phase 2 trial, T-DXd showed substantial efficacy in patients with HER2-mutant NSCLC ($n = 91$), achieving an ORR of 55%, and a disease control rate (DCR) of 92%, with a median PFS of 8.2 months at a median follow-up of 13.1 months[12]. Additionally, T-DXd showed antitumor activity in patients with HER2-overexpressing NSCLC (IHC 2^+ or 3^+; $n = 49$), with an ORR of 26.5%, a DCR of 69%, and a median PFS of 5.7 months (Table 1)[13]. In August 2022, the U.S. FDA approved T-DXd for the treatment of adult patients with unresectable or metastatic NSCLC harboring activating *HER2* mutations, as identified by an FDA-approved CDx, following prior systemic therapy. The approval was accompanied by authorization of two CDx assays, Guardant360® CDx (Guardant Health, Inc.) and Oncomine™ Dx Target Test (Life Technologies Corporation), both designed to detect activating *ERBB2* mutations, including single nucleotide variants and exon 20 insertions, in tumor tissue or plasma, thereby enabling precise molecular stratification of NSCLC patients eligible for T-DXd therapy (Table 1, Fig. 2).

DESTINY-PanTumor02, an open-label phase II trial in patients with locally advanced or metastatic HER2-expressing solid tumors (IHC $3^+/2^+$) across multiple cohorts, including endometrial, cervical, ovarian, bladder, biliary tract, pancreatic, and other malignancies, reported a confirmed ORR of 37.1% (95% CI, 31.3–43.2). Responses were observed in all cohorts, with the greatest benefit in the IHC 3^+ population (ORR 61.3%). The median overall survival (OS) reached 13.4 months (95% CI, 11.9–15.5) in this heavily pretreated group (Table 1)[14]. The DESTINY-CRC02 study investigated the use of T-DXd in patients with HER2-positive (IHC 3^+ or IHC 2^+/ISH$^+$) metastatic colorectal cancer (mCRC), reporting a confirmed ORR of 37.8% in the 5.4 mg/kg arm and 27.5% in the 6.4 mg/kg arm and showing the antitumor activity of T-DXd in patients with HER2-positive mCRC[15]. Based on the above results, the FDA has expanded the indication for T-DXd to include adult patients with unresectable or metastatic HER2-positive (IHC 3^+) solid tumors who have received prior systemic therapy and for whom there are no satisfactory treatment alternatives (Table 1). Observational studies, including the EN-DEAVOR gastric cancer cohort and a single-centre breast cancer series, report clinical activity and safety outcomes for T-DXd in heavily pretreated patients[16,17].

Disitamab vedotin (RC48) in BC and solid tumors

RC48 has also shown antitumor activity in BC and HER2-expressing malignancies[18,19]. A phase I/Ib study demonstrated significant activity in both HER2-overexpressing and HER2-low metastatic BC[18]. At the recommended

dose of 2.0 mg/kg, the ORR was 42.9% in HER2-overexpressing patients and 33.3% in HER2-low patients, with median PFS of 5.7 months and 5.1 months, respectively. Beyond BC, RC48 has demonstrated activity in gastric and urothelial carcinomas expressing HER2. A multicenter phase II study in HER2-overexpressing advanced GC (≥ 2 prior lines of systemic therapy) showed an ORR of 24.8%, with a median PFS of 4.1 months and a median OS of 7.9 months[20]. In a combined analysis of two phase II trials (RC48-C005 and RC48-C009), disitamab vedotin monotherapy achieved a confirmed ORR of 50.5% (95% CI, 40.6–60.3) in 107 patients with previously treated HER2-positive (IHC 2^+ or 3^+) locally advanced or metastatic urothelial carcinoma[21]. These findings highlight the need for robust biomarker assessment across tumor types to optimize therapeutic impact. Based on the above results, RC48 has received several approvals from the National Medical Products Administration in China. It was first approved on June 9, 2021, for the treatment of unresectable or metastatic HER2-overexpressing (IHC 2^+ or 3^+) gastric or gastroesophageal junction adenocarcinoma after at least two prior systemic therapies. In 2025, RC48 was approved in China for HER2-positive advanced breast cancer with liver metastases following prior treatment with trastuzumab (or a biosimilar) and a taxane. In summary, HER2-directed ADCs now span multiple tumor types and expression categories. Eligibility remains specific to the drug, tumor type, and regulatory indication

FRα targeted ADCs

FRα, a cell-surface glycoprotein overexpressed in many epithelial ovarian cancers, has emerged as a promising target for ADCs[22].

Mirvetuximab soravtansine (MIRV) in ovarian cancer

MIRV, comprising a FRα-binding antibody linked to the tubulin inhibitor maytansinoid (DM4), demonstrated significant clinical benefit in platinum-resistant ovarian cancer (PROC)[23]. The SORAYA trial reported an ORR of 32% in patients with high expression of FRα, leading to the accelerated FDA approval on November 14, 2022[24]. Subsequently, the randomized Phase III MIRASOL trial confirmed superior PFS (5.6 vs. 4.0 months), response rate (42% vs. 16%), and OS (16.46 vs. 12.75 months) of the ADC compared to chemotherapy. Patient selection was based on a validated FRα IHC assay requiring ≥ 75% of tumor cells with at least moderate staining intensity[23]. In SORAYA, 36% of screened patients with platinum-resistant ovarian cancer and evaluable tissue were FRα-high[25]. Biomarker positivity should be distinguished from overall treatment eligibility (Table 1). The strong correlation between FRα expression levels and clinical benefit exemplifies the critical importance of quantitative biomarker assessment in the development and application of ADCs. However, a key diagnostic challenge has been ensuring consistent and reproducible scoring of FRα IHC across different laboratories. This has spurred ongoing efforts to develop analysis technologies, which aim to provide more precise and standardized quantification of FRα expression[26].

c-MET targeted ADCs

c-MET overexpression occurs in various malignancies and correlates with aggressive disease and therapeutic resistance[27].

Telisotuzumab vedotin (Teliso-V) in non-squamous NSCLC

Teliso-V, an anti-MET antibody conjugated to monomethyl auristatin E (MMAE), has demonstrated promising activity in the phase II LUMINOSITY trial[28]. In epidermal growth factor receptor (EGFR) wild-type, non-squamous NSCLC with high MET expression, Teliso-V achieved an ORR of 34.6%, compared to 22.9% in MET-intermediate expressors and 11% in MET-positive tumors with *EGFR* mutations or squamous histology[28] (Table 1). In LUMINOSITY, central IHC defined c-MET-high nonsquamous tumors as having strong (3^+) membranous staining in ≥ 50% of tumor cells. Intermediate expression required 3^+ staining in ≥ 25% to < 50% of tumor cells. Patient selection was based on protein overexpression rather than MET amplification.

On May 14, 2025, the FDA granted accelerated approval to Teliso-V for adults with locally advanced or metastatic, non-squamous NSCLC with high c-MET protein overexpression (≥ 50% of tumor cells with strong IHC 3^+ staining), as determined by an FDA-approved test, who have received a prior systemic therapy (Table 1).

Initiated in 2022, the randomized phase III TeliMET NSCLC-01 study compares Teliso-V monotherapy with docetaxel in previously treated, c-Met-overexpressing, EGFR-wildtype nonsquamous NSCLC[29].

TROP2 targeted ADCs

TROP2 is expressed in multiple epithelial malignancies and in several normal epithelial tissues. Its expression and cellular localization provide a rationale for TROP2-directed ADC development.

Sacituzumab govitecan in BC

Sacituzumab govitecan, linking an anti-TROP2 antibody to 7-ethyl-10-hydroxycamptothecin (SN-38), received FDA approval on April 22, 2020 for metastatic triple-negative BC, and FDA approval on February 3, 2023 for unresectable locally advanced or metastatic HR^+/HER2-negative BC (Table 1)[30]. Patient selection for sacituzumab govitecan does not require TROP2-expression testing. However, an exploratory *post hoc* analysis of the phase III ASCENT trial suggested an association between higher TROP2 expression and longer PFS with sacituzumab govitecan. Median PFS was 2.7, 4.8, 6.8, and 6.9 months across increasing TROP2 H-score quartiles (Q1–Q4), respectively[31]. Therefore, patients with ultra/high TROP2-expressing tumors may derive even more pronounced benefit from sacituzumab govitecan, leading to calls for prospective trials stratified by TROP2 expression category.

Datopotamab deruxtecan (Dato-DXd) in BC and NSCLC

Dato-DXd was approved by FDA on January 17, 2025, for treating unresectable or metastatic HR-positive, HER2-negative BC. Approval was based on TROPION-Breast01 study results[32]. The biomarker for eligibility is HR-positive, HER2-negative status (IHC 0, $IHC1^+$, or 2^+&ISH^-), identifying patients likely to benefit from this TROP2 directed ADC, as TROP2 is widely expressed in these cancer cells[33]. Based on a retrospective analysis of the TROPION-Lung01 phase III trial, the QCS platform demonstrated potential relevance in predicting treatment response in patients with lung cancer, particularly NSCLC[34,35]. The study showed that patients with TROP2 quantitative continuous scoring (TROP2-QCS) biomarker-positive tumors (defined as a normalized membrane ratio ≤ 0.56 in $\geq 75\%$ of tumor cells) achieved superior clinical outcomes with Dato-DXd compared to docetaxel. In the TROP2-QCS-positive population, Dato-DXd was associated with a 43% reduction in the risk of disease progression or death compared to docetaxel (median PFS: 6.9 vs. 4.1 months; HR 0.57; 95% CI, 0.41–0.79). In biomarker-positive nonsquamous non-AGA disease, median PFS was 7.2 versus 4.1 months (HR, 0.52; 95% CI, 0.35–0.78). These findings indicate that the QCS platform may serve as a promising predictive biomarker tool for identifying patients with lung cancer who are most likely to benefit from TROP2-targeted therapies such as Dato-DXd.

CLDN18.2 targeted ADCs

CLDN18.2, a tight-junction protein predominantly expressed in gastric mucosa and frequently in gastrointestinal malignancies, has emerged as a promising ADC target[36]. Early-phase trials of CLDN18.2 directed ADCs have demonstrated encouraging efficacy.

Sonesitatug vedotin (CMG901) in gastroesophageal cancer and SYSA1801 in GC (under investigation)

CLDN18.2-directed ADCs have shown preliminary antitumor activity in early-phase studies. In a phase Ia dose-escalation study, CMG901 achieved an ORR of 75.0% (6/8) in a retrospectively identified CLDN18.2-positive gastric/gastroesophageal junction cancer subgroup. In a separate phase I study, SYSA1801 achieved an ORR of 47.1% (8/17) among efficacy-evaluable patients with gastric cancer[37,38]. These small, nonrandomized cohorts support further investigation but do not establish comparative efficacy or a common predictive expression threshold. Reliable CLDN18.2 assessment requires standardized testing and context-specific interpretation. Practical IHC guidance recommends evaluating membranous staining alongside matched H&E sections[39].

Biomarker testing should follow indication-specific requirements, complementing histological diagnosis where validated biomarker criteria guide ADC selection. The following sections discuss the clinical applications of these biomarkers and advances in their detection.

Clinical implications of predictive and prognostic biomarkers in ADC therapy

Biomarker expression may have both predictive and prognostic implications in ADC therapy, depending on the drug and disease context. Target antigen expression is essential for ADC binding, internalization, and payload delivery, and thus provides the biological rationale for biomarker-guided patient selection. Nevertheless, the extent to which antigen expression functions as a predictive marker varies across different ADCs and clinical settings. For HER2, FRα and c-MET in selected therapeutic contexts, its predictive value is more clearly established, whereas for other targets antigen expression is often used primarily to enrich for potentially responsive populations or to support treatment stratification[40]. At the same time, the expression of several ADC-related targets is also associated with tumor aggressiveness and unfavorable clinical outcomes, indicating that these biomarkers may also have prognostic implications in certain disease settings. Taken together, the clinical interpretation of biomarker expression in ADC therapy should be made in the context of the specific drug, tumor type, testing method, and available level of evidence[41]. For example, MET overexpression in NSCLC is associated with shorter survival and resistance to EGFR inhibitors[42]. Similarly, MIRASOL demonstrated the benefit of mirvetuximab soravtansine over chemotherapy in patients with FRα-high, platinum-resistant ovarian cancer[23].

Establishing biomarker cutoff criteria for ADC therapy

The application of ADC biomarkers in clinical practice requires defining precise cutoff criteria for "positivity" to ensure correlation with therapeutic benefit. Clinical trials have adopted specific thresholds (Table 2). For instance, the HER2 cutoff was initially derived from trastuzumab trials, with later findings showing T-DXd efficacy in HER2-low populations, leading to a new classification. Defining the optimal cutoff remains challenging because overly strict thresholds may exclude potential responders, whereas less stringent criteria can dilute clinical efficacy outcomes. Exploratory analyses from ADC studies have sought to refine these thresholds. In the ASCENT trial, sacituzumab govitecan efficacy was stratified by TROP2 IHC H-score. All groups benefited versus chemotherapy, but low TROP2 expression showed relatively lower response rates[31]. In HER2-low BC, studies suggest "ultra-low" HER2 levels (IHC 0 with faint staining) may still confer ADC sensitivity. Preliminary data show some IHC 0 tumors exhibit faint HER2 expression on digital assays and respond to T-DXd, though validation is ongoing. Improved diagnostics and ADC potency with bystander effects may further redefine these thresholds[43,44]. Most ADCs in clinical trials use biomarker detection and standardized criteria for patient selection, but exceptions exist like Nectin-4-targeting ADCs. Nectin-4, a cell adhesion molecule, is frequently expressed in urothelial carcinoma (e.g., bladder cancer), with positivity rates typically between 60% and 90%[45,46]. Enfortumab vedotin, an Nectin-4 targeting ADC, shows antitumor activity in locally advanced or metastatic urothelial carcinoma without mandatory Nectin-4 expression testing[47,48].

Expanding biomarker applications in ADC therapy

An emerging strategy involves the integration of multiple biomarkers. Currently, the selection of ADCs is predominantly based on a single antigen target. However, the incorporation of additional biomarkers may enhance the accuracy of response prediction and facilitate the identification of underlying resistance mechanisms[49]. Beyond antigen expression, alterations in payload targets may provide complementary biomarkers of ADC resistance. Abelman et al. identified *TOP1* mutations in 4 of 31 ADC-exposed patients with metastatic breast cancer. Selected variants conferred resistance to both SN-38 and deruxtecan in functional studies, implicating *TOP1* mutations in cross-resistance among ADCs with TOP1 inhibitor payloads[50]. These findings support evaluating *TOP1* mutational status to inform sequential ADC treatment, although its clinical utility requires validation.

Drug efflux pumps or deoxyribonucleic acid (DNA) repair enzymes may affect ADC efficacy by mediating cytotoxic payload resistance[51,52]. Though unvalidated clinically, exploratory studies examine resistance mechanisms (e.g., drug resistance gene upregulation, antigen loss post-treatment) as potential biomarkers for therapy selection.

Table 2: Summary of biomarkers inclusion criteria in key clinical trials as of May 2025

ADC	Key clinical trial	NCT number	Biomarker inclusion criteria	Biomarker definitions
Trastuzumab emtansine (T-DM1)	EMILIA[6]	NCT00829166	HER2-positive breast cancer	Centrally confirmed IHC 3^+ or HER2 amplification by FISH (HER2/CEP17 ratio $\geq$ 2.0), or both.
	KATHERINE[87,88]	NCT01772472	HER2-positive early breast cancer with residual invasive disease after neoadjuvant therapy	Centrally confirmed IHC 3^+ or ISH-positive (HER2/chromosome 17 ratio $\geq$ 2.0). Testing preferentially used the pretreatment biopsy; residual surgical tissue could be used if the pretreatment specimen was unavailable or inadequate.
Trastuzumab deruxtecan (T-DXd)	DESTINY-Breast03[8]	NCT03529110	HER2-positive unresectable or metastatic breast cancer	HER2 positivity, defined as IHC 3^+ or ISH-positive, was centrally confirmed before enrollment.
	DESTINY-Breast04[9]	NCT03734029	HER2-low unresectable or metastatic breast cancer; HR-positive and HR-negative cohorts	IHC 1+ or IHC 2^+/ISH-negative by central testing. IHC used the VENTANA HER2/neu (4B5) investigational assay and an algorithm adapted from the 2018 ASCO/CAP guidelines; IHC 2^+ specimens underwent reflex ISH.
	DESTINY-Gastric01[11,89]	NCT03329690	HER2-positive primary cohort; separate HER2-low exploratory cohorts in gastric/GEJ adenocarcinoma	Primary cohort: centrally confirmed IHC 3^+ or IHC 2^+/ISH-positive. Exploratory cohort 1: IHC 2^+/ISH-negative; exploratory cohort 2: IHC 1^+. The exploratory cohorts were anti-HER2-treatment-naive and distinct from the trastuzumab-pretreated randomized primary cohort.
Trastuzumab deruxtecan (T-DXd)	DESTINY-Lung01[12,13]	NCT03505710	Separate HER2-overexpressing and *HER2*-mutant nonsquamous NSCLC cohorts	Protein-expression cohorts 1/1A: IHC 2^+ or 3^+, without known *HER2* mutations. Mutation cohort 2: an activating *HER2* (ERBB2) mutation detected in tumor tissue and confirmed by a certified local laboratory; an IHC expression or amplification threshold was not required for this cohort.
	DESTINY-Lung02[90]	NCT04644237	Activating *HER2* (ERBB2) mutation in metastatic NSCLC	A known activating *HER2* mutation documented in archival or fresh tumor tissue by certified local laboratory testing. Central confirmation with Oncomine Dx Target Test was retrospective; HER2 protein overexpression or amplification was not an entry requirement.
	DESTINY-PanTumor02[14]	NCT04482309	HER2-expressing advanced solid tumors, generally IHC 2^+ or 3^+	IHC 2^+ or 3^+ using ASCO/CAP gastric-specific scoring, based on local testing where available or central HercepTest assessment. ISH positivity was not required. Limited IHC 1^+ enrollment was permitted after a protocol-defined interim analysis; five such patients entered the cervical cohort.
Trastuzumab deruxtecan (T-DXd)	DESTINY-CRC02[15]	NCT04744831	HER2-positive advanced colorectal cancer; BRAF wild-type, with RAS wild-type or mutant disease permitted	Centrally confirmed HER2 IHC 3^+ or IHC 2^+ with positive ISH.
	DESTINY-Breast06[10]	NCT04494425	HR-positive, HER2-low or HER2-ultralow metastatic breast cancer	HER2-low: IHC 1^+ or IHC 2^+/ISH-negative. HER2-ultralow: IHC 0 with detectable membrane staining (IHC $>$ 0 and $<$ 1^+; faint staining in $>$ 0% to $\leq$ 10% of tumor cells), centrally confirmed; the ultralow cohort required a specimen obtained after metastatic disease had occurred.

(*continued*)

Table 2

(continued)

ADC	Key clinical trial	NCT number	Biomarker inclusion criteria	Biomarker definitions
Disitamab vedotin (RC48)	RC48-C008[20]	NCT03556345	HER2-overexpressing gastric/GEJ adenocarcinoma	IHC 2^+ or 3^+. HER2 amplification was not required for IHC 2^+ tumors.
	RC48-C005[21,91]	NCT03507166	HER2-overexpressing locally advanced or metastatic urothelial carcinoma	IHC 2^+ or 3^+. The study included IHC 2^+/FISH-negative tumors; FISH positivity was not mandatory.
Mirvetuximab soravtansine	SORAYA[25]	NCT04296890	FRα-high platinum-resistant high-grade serous ovarian, fallopian-tube or primary peritoneal cancer	PS2$^+$ scoring: ≥ 75% of viable tumor cells with moderate (2^+) or strong (3^+) membrane staining using the Ventana FOLR1 assay.
	MIRASOL[23]	NCT04209855	FRα-high platinum-resistant high-grade serous ovarian, fallopian-tube or primary peritoneal cancer	PS2$^+$ scoring: ≥ 75% of viable tumor cells with moderate (2^+) or strong (3^+) membrane staining, assessed with the VENTANA FOLR1 (FOLR1-2.1) RxDx assay.
Telisotuzumab vedotin	LUMINOSITY[28]	NCT03539536	c-Met-overexpressing nonsquamous EGFR-wildtype NSCLC (expanded efficacy cohort)	Central MET (SP44) clinical-trial IHC: ≥ 25% of tumor cells with strong (3^+) membranous staining. High: ≥ 50%; intermediate: ≥ 25% to < 50%. These thresholds describe the nonsquamous cohorts, not the squamous cohort enrolled in stage 1 of the trial.

IHC 2^+/ISH-positive requires both IHC 2^+ and ISH positivity; IHC 3^+ is an alternative category. Breast HER2-positive, HER2-low, gastric HER2-positive and RC48 HER2-overexpression definitions are not interchangeable.

Abbreviations: CEP17, chromosome 17 centromere; FISH, fluorescence *in situ* hybridization; FRα, folate receptor-α; GEJ, gastroesophageal junction; HR, hormone receptor; IHC, immunohistochemistry; ISH, *in situ* hybridization; NCT, ClinicalTrials.gov identifier; NSCLC, non-small-cell lung cancer; PS2$^+$, percentage of tumor cells staining at intensity ≥ 2^+.

Immune features, including PD-L1 expression and CD8$^+$ T-cell infiltration, are being explored as potential correlates of response to ADCs and ADC–immune checkpoint inhibitor combinations[53]. BC studies assessed ADC-immune checkpoint inhibitor combinations, suggesting further patient selection may combine tumor antigen expression and immune profiles[54]. However, these approaches remain experimental.

Current detection methods and scoring criteria for ADC biomarkers

Traditional methods for ADC target detection, primarily IHC for protein and *in situ* hybridization (ISH) for gene amplification, face sensitivity and throughput limitations. Emerging advances aim to enhance biomarker detection and quantification for improved ADC utilization[55]. Another important pre-analytical consideration is the temporal and spatial heterogeneity of ADC target expression. Biomarker status may differ between primary tumors and metastatic or progressed lesions, and may also vary between core needle biopsy and surgical resection specimens because of intratumoral heterogeneity and sampling limitations. This issue is particularly relevant for low-level antigen expression, such as HER2-low/ultralow disease, where small differences in staining intensity or the proportion of positive tumor cells may alter treatment eligibility. Therefore, when clinically feasible, biomarker testing should preferentially be performed on the most recent and clinically relevant tumor tissue, especially in patients with recurrent or metastatic disease, while recognizing that tissue availability and assay validation may vary across tumor types and ADC targets[56,57]. Current mainstay techniques have distinct advantages and limitations.

IHC-based protein detection and scoring

IHC on formalin-fixed, paraffin-embedded tissue is the most widely used technique to assess protein expression in tumors, including HER2, FRα, TROP2, CLDN18.2, and c-MET. Protein expression is typically assessed based on staining intensity and percentage of positive cells; however, cutoff values for positivity vary across

different biomarkers. Inter-observer variability and technical factors, such as antibody clones and staining protocols, can influence assay results, posing particular challenges in borderline cases, such as distinguishing between HER2 IHC 0 and IHC 1^+ expression[58–60]. In addition, tumor heterogeneity can lead to sampling errors and false negatives. However, IHC remains essential for its accessibility and direct visualization of tumor morphology and protein localization. Current improvements focus on standardized protocols, consistent scoring, and automated image analysis to minimize subjectivity. A comprehensive summary of the updated scoring criteria and guideline references for these biomarkers is provided in Table 3 to support standardized interpretation across cancer types. Representative IHC staining patterns for commonly used ADC biomarkers are shown in Fig. 3.

ISH-based DNA/RNA assessment

ISH methods, including fluorescence (FISH) or chromogenic ISH, are utilized to detect gene amplification or

Table 3: Immunohistochemistry scoring criteria and guidelines for selected biomarkers across cancer types as of May 2025

Biomarker	Cancer	Reference	Updated year	Scoring criteria
HER2	Breast cancer	ASCO–CAP HER2 testing guideline update[68]	2023	IHC 3^+ (positive for overexpression): > 10% of invasive tumor cells show intense, complete circumferential membrane labeling. IHC 2^+ (equivocal): complete membrane labeling of weak or moderate intensity in > 10% of invasive tumor cells; perform reflex ISH. IHC 1^+ (negative for overexpression): > 10% of invasive tumor cells show faint, incomplete membrane labeling. IHC 0 (negative for overexpression): staining is absent, or faint, incomplete membrane labeling involves ≤ 10% of invasive tumor cells.
HER2	Gastric/ gastroesophageal junction adenocarcinoma	CAP–ASCP–ASCO HER2 testing guideline[59]	2017	IHC 3^+ (positive): strong membrane labeling, complete or basolateral/lateral, in ≥ 10% of tumor cells in a resection, or in a qualifying tumor-cell cluster in a biopsy. IHC 2^+ (equivocal): weak/moderate membrane labeling, complete or basolateral/lateral, in ≥ 10% of tumor cells in a resection, or in a qualifying biopsy cluster; perform reflex ISH. IHC 1^+ (negative): faint, partial membrane labeling in ≥ 10% of resection tumor cells, or faint membrane labeling in a qualifying biopsy cluster. IHC 0 (negative): resection, staining absent or membrane labeling in < 10% of tumor cells; biopsy, no tumor-cell membrane labeling.
FRα	Epithelial ovarian, fallopian tube, or primary peritoneal cancer	VENTANA FOLR1 (FOLR1-2.1) RxDx Assay interpretation guide (P220006) [FDA-23]	2022	Intensity 3^+ (strong): dark-brown to black membrane labeling. Partial or circumferential patterns are acceptable. Intensity 2^+ (moderate): brown membrane labeling meeting the assay's moderate-intensity reference-slide standard. Intensity 1^+ (weak): faint gold/light-brown membrane labeling. Intensity 0: specific membrane signal is absent; pale-grey discoloration does not constitute specific staining.

(*continued*)

Table 3

(continued)

Biomarker	Cancer	Reference	Updated year	Scoring criteria
FRα	Epithelial ovarian, fallopian tube, or primary peritoneal cancer	VENTANA FOLR1 (FOLR1-2.1) RxDx Assay interpretation guide (P220006) [FDA-23]	2022	Assay classification: positive when ≥ 75% of viable tumor cells have $2^+/3^+$ membrane labeling; negative below 75%. Cytoplasmic staining is excluded. Intensity 3^+ (strong): saturated dark-brown/black membrane and/or cytoplasmic labeling, readily evident with a 2× – 4× objective. Intensity 2^+ (moderate): rich-brown membrane/cytoplasmic labeling, more readily appreciated with a 4× – 10× objective. Intensity 1^+ (weak): pale-tan/light-brown membrane/cytoplasmic labeling, requiring approximately a 10× – 20× objective. Intensity 0: no specific signal; pale-grey membrane discoloration alone is disregarded.
c-MET	Non-squamous NSCLC	VENTANA MET (SP44) RxDx Assay FDA labeling and interpretation guide (P240037) [FDA-18, FDA-24]	2025	
c-MET	Non-squamous NSCLC	VENTANA MET (SP44) RxDx Assay FDA labeling and interpretation guide (P240037) [FDA-18, FDA-24]	2025	Assay classification: positive when ≥ 50% of tumor cells have 3^+ membrane and/or cytoplasmic labeling; negative below 50%.
CLDN18.2	Gastric/gastroesophageal junction adenocarcinoma	Fassan et al., practical CLDN18.2 IHC guidance[39]	2024	Intensity 3^+ (strong): a distinct brown membrane network is evident at low power, approximately a 2.5× – 5× objective. Intensity 2^+ (moderate): membrane labeling is evident with a 10× objective; confirmation may require 20×. Intensity 1^+ (weak): faint membrane labeling may be visible at 20× but requires 40× confirmation; it does not contribute to the $2^+/3^+$ positive fraction. Intensity 0: no specific membrane labeling. Report the percentage of tumor cells at each intensity and apply the therapy-specific cutoff.

FDA source documents are indexed in Supplementary File S1.

ASCO, American Society of Clinical Oncology; CAP, College of American Pathologists; ASCP, American Society for Clinical Pathology; CLDN18.2, claudin 18.2; FRα, folate receptor-α; IHC, immunohistochemistry; ISH, *in situ* hybridization; NSCLC, non-small cell lung cancer. Magnifications indicate objective lenses.

Breast HER2: uncommon patterns, including intense complete staining in ≤ 10% of cells or moderate/intense incomplete staining, are considered IHC 2^+ equivocal. The 2023 update retained the existing score categories. "Negative" refers to overexpression, not absence of HER2 protein; ADC eligibility is indication-specific[68] .

Gastric HER2: a qualifying biopsy cluster contains ≥ 5 neoplastic cells; the percentage of the biopsy involved is irrelevant. Count membrane staining, including lateral/basolateral patterns; exclude cytoplasmic or isolated luminal/apical labeling[59] .

FRα: assess approximately ≥ 100 viable tumor cells, using the moderate-intensity reference slide. Apical, partial and complete membrane patterns can count. Cases with 65%–85% $2^+/3^+$ cells require independent rereading/adjudication according to the guide. [FDA-23]

c-MET: assess approximately ≥ 100 viable tumor cells. Strong membrane staining may be complete, partial or basolateral; strong cytoplasmic signal also counts. Obtain a second independent review for 40%–60% 3^+ cells or borderline $2^+/3^+$ intensity and report a consensus result. These are the 2025 RxDx criteria, not a universal MET scoring system. [FDA-18, FDA-24]

CLDN18.2: evaluate convincing membrane labeling (complete, basolateral or lateral) alongside matched H&E; exclude nuclear, cytoplasmic and nonspecific granular signal. The ≥ 75% $2^+/3^+$ cutoff in this guidance concerns zolbetuximab. It is not a validated universal eligibility threshold for investigational CLDN18.2 ADCs; use each trial's assay and cutoff[39] .

messenger ribonucleic acid (mRNA) transcripts. HER2 FISH is well established for clarifying equivocal IHC 2^+ cases[61]. For MET, ISH can identify increased gene copy number; however, protein overexpression may occur independently of gene amplification. Since not all ADC targets such as FRα, TROP2, and CLDN18.2 are associated with gene amplification, IHC remains the preferred testing method in these scenarios[62]. Overall, ISH

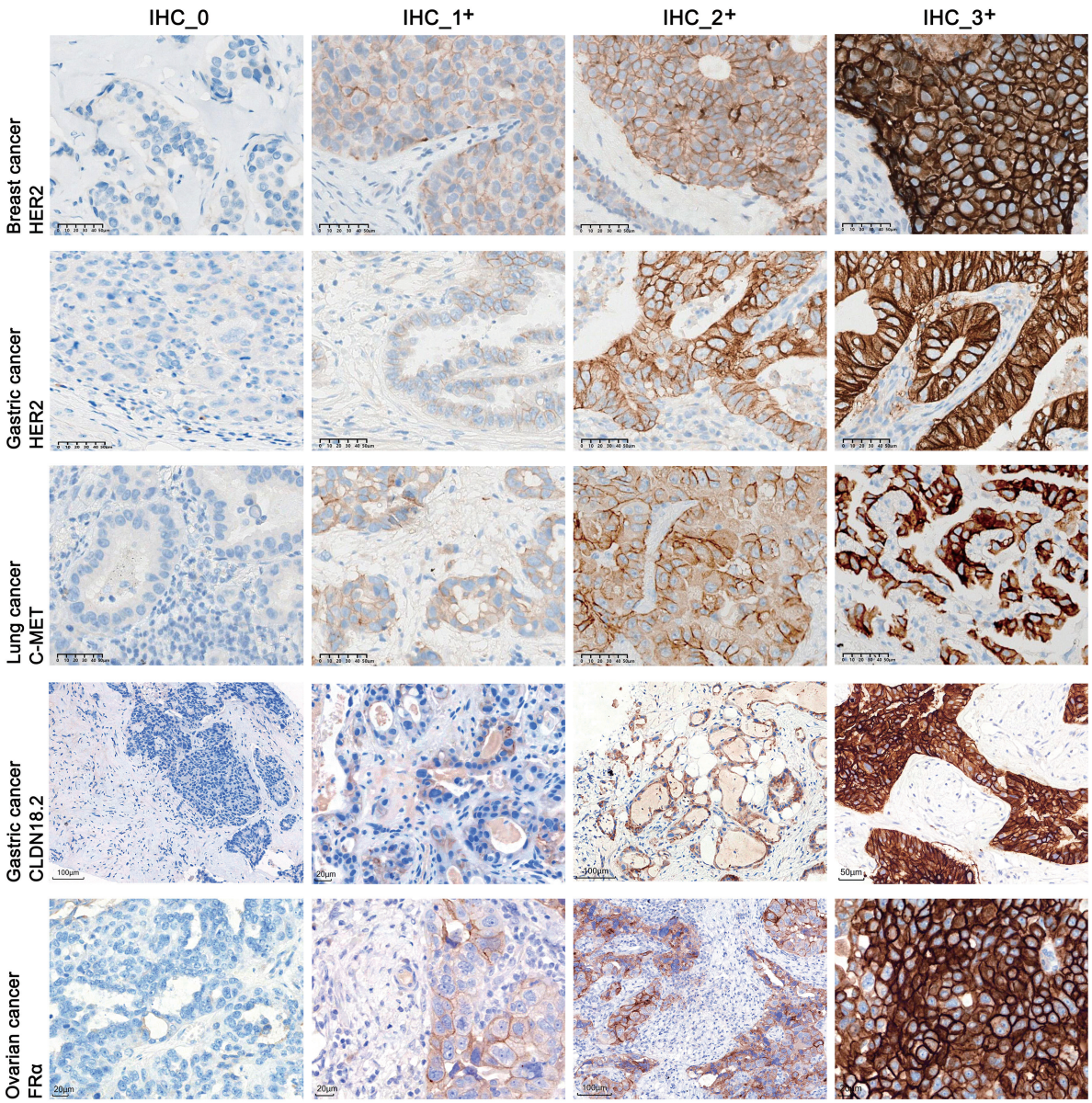

Figure 3: Representative IHC staining patterns of ADC biomarkers across cancer types

This figure illustrates the IHC staining intensities (IHC 0, 1^+, 2^+, and 3^+) for four ADC-relevant biomarkers, HER2 (in breast and gastric cancer), c-MET (in lung cancer), CLDN18.2 (in gastric cancer), and FRα (in ovarian cancer). Each row represents a distinct biomarker-tumor combination, showing the progressive increase in membranous or cytoplasmic staining intensity from IHC 0 (negative) to IHC 3^+ (strong positive). These representative images serve as visual references to support consistent and reproducible IHC scoring and underscore the heterogeneity in expression patterns across tumor types and molecular targets. Representative IHC images were obtained from de-identified archival diagnostic specimens processed using standard IHC protocols.

complements IHC when gene amplification is relevant to an indication, particularly in HER2 IHC 2^+ tumors. Amplification testing should not be used as a surrogate for surface protein expression or imposed on protein-defined ADC indications unless required by the validated testing algorithm.

Next-generation sequencing (NGS) based DNA profiling and genomic tests

NGS-based genomic profiling is increasingly integrated into routine oncology practice to detect actionable DNA alterations, including single-nucleotide variants,

insertions/deletions, copy-number alterations, and gene fusions[63]. In the context of ADC biomarker testing, however, genomic assays should be distinguished from protein-level antigen assessment by IHC. Protein-expression assays define eligibility for selected HER2-, FRα- and c-MET-directed ADC indications. By contrast, approved TROP2-directed ADCs do not require a TROP2-expression cutoff, and selection criteria for investigational CLDN18.2-directed ADCs remain trial-specific. HER2-mutant NSCLC is an established example in which an activating ERBB2 alteration defines eligibility for ADC treatment[64]. Beyond initial patient selection, genomic profiling may provide complementary information on resistance mechanisms after ADC exposure. Acquired alterations may affect either the antigen target or the payload-related pathway. For example, clinical resistance to sacituzumab govitecan has been associated with parallel genomic alterations in TACSTD2, encoding TROP2, and TOP1, the payload target of SN-38[65]. More recently, plasma-based genotyping identified recurrent *TOP1* mutations emerging at progression on TOP1 inhibitor-based ADCs, suggesting a potential mechanism of cross-resistance to sequential ADCs with similar payloads[50]. These findings support the potential value of post-progression genomic testing in selected patients, particularly when considering ADC sequencing or enrollment in biomarker-driven trials. Nevertheless, genomic testing currently plays a supportive rather than primary role in ADC biomarker evaluation. DNA-level alterations do not necessarily reflect antigen abundance, membrane localization, intratumoral heterogeneity, or ADC internalization efficiency, all of which are critical for ADC activity[50].

Multiplex protein quantification in research settings

In research settings, tumor dissociation and antigen density measurement via flow cytometry is feasible. For instance, biopsy analysis can quantify antibody binding sites per cell (a metric used in target comparison). However, this method lacks spatial context and is impractical for routine solid tumor diagnostics. Imaging mass cytometry and multiplexed ion beam imaging use metal-tagged antibodies to quantify multiple proteins while preserving tissue architecture[66,67]. These approaches generate spatially resolved, high-dimensional data for translational research, but require further standardization and validation before routine ADC selection.

A key challenge in biomarker detection is establishing reproducible and clinically relevant scoring systems. Each ADC target typically requires its own scoring method, often developed during trials. HER2 scoring, initially based on trastuzumab-era criteria, is being revised for HER2-low cases[49]. FRα scoring was developed alongside mirvetuximab trials using the Ventana FOLR1 IHC assay to define "FRα-high" and ensure consistency[25]. MET scoring required standardization due to varied literature methods. The College of American Pathologists (CAP) updated HER2 testing recommendations addressing HER2-low interpretation and helped harmonize detection methods[68]. Similar guidelines may emerge for FRα in ovarian cancer or CLDN18.2 in GC. In summary, as ADC indications extend to lower antigen-expression levels, assay validation and reproducible scoring become increasingly important for treatment eligibility.

Future directions in ADC predictive biomarker testing

AI-assisted pathology and QCS are being evaluated to improve the reproducibility and quantitative resolution of ADC biomarker assessment.

Application of AI in biomarker detection

AI-powered digital pathology is helping standardize IHC biomarker assessment by overcoming limitations of manual scoring, which is subjective and variable[69]. Deep learning models trained on extensive pathology datasets minimize discrepancies[70]. These AI systems reduce observer bias, detect subtle patterns, and enhance reproducibility for ADC biomarkers.

AI-assisted image analysis can support more consistent HER2 IHC scoring for borderline cases across pathologists and institutions[70,71]. The technology enables precise biomarker quantification on tissue slides by distinguishing tumor/stroma compartments and cellular structures[69]. It measures staining intensity continuously (positive membrane area, chromogen density per cell) rather than

using categorical scores[72]. This IHC analysis better captures tumor heterogeneity and provides objective protein expression data of HER2, reducing human error and refining ADC selection thresholds[71].

AI models can integrate histopathology with molecular and clinical data to develop candidate predictive biomarkers[73,74]. In oncology, deep learning can integrate histopathological images with transcriptomic and proteomic features to predict molecular alterations and pathological stage across cancer types[73]. Trained in large datasets, AI combines IHC, genomic, and radiologic information for superior predictors. These models may guide ADC use by assessing protein expression and tumor-intrinsic factors like mutations and immune context[74]. A diagnostic meta-analysis showed promising overall accuracy of AI-based HER2 IHC classification, demonstrating enhanced sensitivity in borderline IHC 1^+ cases, thereby enabling more precise patient selection for T-DXd therapy[75].

QCS concept and benefits

QCS uses digital image analysis to quantify biomarker expression continuously and spatially, supporting data-driven thresholds beyond categorical IHC scores[76]. Key steps involve scanning IHC slides, using AI to measure staining intensity (e.g. diaminobenzidine optical density per tumor cell membrane), and generating per-cell expression distributions or summary metrics. Calibration and rigorous quality control are needed for reproducible quantification, while interlaboratory performance requires further validation[77]. In 2024, Kapil et al. used HER2 QCS to identify potential T-DXd responders among patients with conventionally HER2-negative breast cancer. Across the cohort, median PFS was 14.8 versus 8.6 months in the QCS-defined high and low groups, respectively[76]. In NSCLC, TROP2 QCS used the normalized membrane ratio (NMR), which is membrane optical density divided by the sum of membrane and cytoplasmic optical densities. TROP2 QCS-NMR positivity identified a subgroup with greater PFS benefit from Dato-DXd than from docetaxel[35]. This localization-based category differs from conventional TROP2-high expression. Therefore, QCS refines "positive" biomarker thresholds, improving patient selection by aligning therapy with tumor biology.

Emerging technologies and integrative approaches

In contrast to currently established single-biomarker assays, several emerging technologies are being developed to support more comprehensive and dynamic ADC biomarker assessment. These approaches, including single-cell and spatial omics, liquid biopsy, and molecular imaging, are not yet routine tools for determining ADC eligibility in most clinical settings, but they may help characterize tumor heterogeneity, monitor treatment response, and identify mechanisms of resistance. Single-cell RNA sequencing and spatial transcriptomics enable high-resolution profiling of tumor heterogeneity and the tumor microenvironment[78]. Unlike bulk genomic assays, single-cell RNA sequencing profiles ADC target-gene expression across cell populations, whereas spatial transcriptomics maps these patterns while preserving tissue context. These approaches can characterize heterogeneity relevant to ADC response and resistance, supporting target discovery and rational combination strategies. They serve primarily as discovery and translational research tools that complement routine IHC-based protein assessment[79]. Beyond tissue analysis, liquid biopsies offer minimally invasive biomarker tools for ADCs. Circulating tumor DNA (ctDNA) assays detect tumor-derived DNA in blood, reflecting tumor burden dynamically. Circulating proteins and extracellular vesicles also provide real-time treatment response indicators[80]. In patients receiving patritumab deruxtecan (HER3-DXd), clearance of EGFR-mutant ctDNA at week 3 or 6 was associated with higher response rates and longer progression-free survival[81]. ctDNA clearance indicates effective tumor cell destruction, while rising levels may signal treatment failure or resistance before clinical progression[82]. Improved digital polymerase chain reaction (PCR) and NGS sensitivity will enhance ctDNA's role in ADC biomarker strategies, from early decision-making to detecting minimal residual disease and relapse.

Recent advances in molecular imaging have enabled positron emission tomography-computed tomography (PET-CT) based tracer technologies for assessing ADCs. Radiolabeled antibodies, antibody fragments, or target-specific ligands can be used to assess tracer uptake and target accessibility across multiple lesions,

providing a whole-body complement to tissue-based testing[83,84]. This approach overcomes limitations of traditional histopathology, which lacks dynamic, whole-body pharmacokinetic data. In the ZEPHIR study, baseline ^{89}Zr-trastuzumab PET, combined with early FDG-PET assessment, was evaluated for predicting outcomes with T-DM1 in HER2-positive advanced breast cancer[85]. Serial molecular imaging is being explored to monitor changes in tracer uptake and treatment response; whether imaging-guided treatment adaptation improves ADC outcomes remains to be established.

Clinically, this imaging strategy offers three advantages: improved patient selection by identifying low target expression; early detection of tumor response/resistance for timely modifications; and systemic ADC pharmacokinetic/pharmacodynamic profiling to support personalized treatment. Advances in radiolabeled agents and imaging platforms will enhance PET-CT's role in ADC therapy, while big data analytics and real-world evidence improve predictive biomarker discovery[86].

Conclusion

Biomarker testing is central to ADC development and clinical use, with requirements determined by the specific drug and indication. HER2, FRα, and c-MET illustrate the clinical value of biomarker-defined patient selection. The efficacy of T-DXd in HER2-low disease further emphasizes the need for treatment-specific interpretation of biomarker results. Standardized IHC and ISH remain essential components of established testing workflows. AI-assisted quantification, genomic profiling, and liquid biopsy may improve the assessment of tumor heterogeneity and resistance, but their contribution to treatment selection requires prospective validation. Collaboration among oncologists, pathologists, and diagnostic specialists will help integrate these approaches into consistent testing practices and informed ADC treatment decisions.

Author contributions

Xuemin Xue, Jianfeng Wu, and Ying Yang collected and analyzed data for the manuscript and made substantial contributions to the conceptualization and discussion of content. Yuanhao Liu contributed to the acquisition of pathological images. Xuemin Xue, Jianfeng Wu, Ying Yang, Shun Lu, Zhe Wang, and Jianming Ying drafted the manuscript. All authors critically revised the work and approved the final version for submission.

Acknowledgements

This work was supported by grants from Chinese Academy of Medical Sciences (CAMS) Innovation Fund for Medical Sciences (CIFMS) (No. 2021-1-I2M-012), and the National Natural Science Foundation of China (Grant No. 82172876). We express our sincere gratitude to the editor and reviewers for their constructive comments and to the journal and its publisher for their professional support.

Ethics statement

Not applicable.

Data availability statement

No datasets were generated or analyzed for this work.

AI statement

The authors used GPT-5.6 Sol as a language-editing tool to improve grammar, clarity, and readability. The AI tool was not used for data generation, image processing, or scientific content creation. All outputs were carefully reviewed and verified by the authors, who take full responsibility for the final content. The authors created, assembled, and annotated the figure using Adobe Illustrator and Microsoft PowerPoint.

Conflicts of interest

Jianming Ying serves as Editor-in-Chief and Zhe Wang serves as a member of the Editorial Board of this journal. They were not involved in the editorial review or decision-making process for this manuscript. All editorial decisions were made independently by other members of the Editorial Board who have no conflicts of interest.

Supplementary files

Electronic supplementary material (Supplementary File S1. Index of FDA regulatory source documents supporting ADC indications and companion diagnostic information

as of May 2025) is available in the online version of this article at doi/10.2738/PR.2026.0007 and is accessible for authorized users.

References

1. Fu Z, Li S, Han S, Shi C, Zhang Y. Antibody drug conjugate: the "biological missile" for targeted cancer therapy. *Signal Transduct Target Ther*. 2022;7(1):93.
2. Gu Y, Wang Z, Wang Y. Bispecific antibody drug conjugates: making 1 + 1 > 2. *Acta Pharm Sin B*. 2024;14(5): 1965-1986.
3. Gogia P, Ashraf H, Bhasin S, Xu Y. Antibody-drug conjugates: a review of approved drugs and their clinical level of evidence. *Cancers (Basel)*. 2023;15(15):3886.
4. Zhou Y, Tao L, Qiu J, et al. Tumor biomarkers for diagnosis, prognosis and targeted therapy. *Signal Transduct Target Ther*. 2024;9(1):132.
5. Zimmerman BS, Esteva FJ. Next-generation HER2-targeted antibody-drug conjugates in breast cancer. *Cancers (Basel)*. 2024;16(4):800.
6. Verma S, Miles D, Gianni L, et al. Trastuzumab emtansine for HER2-positive advanced breast cancer. *N Engl J Med*. 2012;367(19):1783-1791.
7. Modi S, Saura C, Yamashita T, et al. Trastuzumab deruxtecan in previously treated HER2-positive breast cancer. *N Engl J Med*. 2020;382(7):610-621.
8. Cortés J, Kim SB, Chung WP, et al. Trastuzumab deruxtecan versus trastuzumab emtansine for breast cancer. *N Engl J Med*. 2022;386(12):1143-1154.
9. Modi S, Jacot W, Yamashita T, et al. Trastuzumab deruxtecan in previously treated HER2-low advanced breast cancer. *N Engl J Med*. 2022;387(1):9-20.
10. Bardia A, Hu X, Dent R, et al. Trastuzumab deruxtecan after endocrine therapy in metastatic breast cancer. *N Engl J Med*. 2024;391(22):2110-2122.
11. Shitara K, Bang YJ, Iwasa S, et al. Trastuzumab deruxtecan in previously treated HER2-Positive gastric cancer. *N Engl J Med*. 2020;382(25):2419-2430.
12. Li BT, Smit EF, Goto Y, et al. Trastuzumab deruxtecan in HER2-Mutant non-small-cell lung cancer. *N Engl J Med*. 2022;386(3):241-251.
13. Smit EF, Felip E, Uprety D, et al. Trastuzumab deruxtecan in patients with metastatic non-small-cell lung cancer (DESTINY-Lung01): primary results of the HER2-overexpressing cohorts from a single-arm, phase 2 trial. *Lancet Oncol*. 2024;25(4):439-454.
14. Meric-Bernstam F, Makker V, Oaknin A, et al. Efficacy and safety of trastuzumab deruxtecan in patients with HER2-expressing solid tumors: primary results from the DESTINY-PanTumor02 phase II trial. *J Clin Oncol*. 2024;42(1):47-58.
15. Raghav K, Siena S, Takashima A, et al. Trastuzumab deruxtecan in patients with HER2-positive advanced colorectal cancer (DESTINY-CRC02): primary results from a multicentre, randomised, phase 2 trial. *Lancet Oncol*. 2024;25(9):1147-1162.
16. Nakanishi K, Sugimoto N, Kodera Y, et al. Prognostic factors and treatment response in HER2-positive gastric cancer patients receiving trastuzumab deruxtecan: secondary analysis of the EN-DEAVOR study. *ESMO Gastrointest Oncol*. 2025;8:100184.
17. Lazaratos AM, Dankner M, Hamouda A, et al. The real-world clinical outcomes of heavily pretreated HER2^{+} and HER2-low metastatic breast cancer patients treated with trastuzumab deruxtecan at a single centre. *Curr Oncol*. 2024;32(1):1.
18. Wang J, Liu Y, Zhang Q, et al. Disitamab vedotin, a HER2-directed antibody-drug conjugate, in patients with HER2-overexpression and HER2-low advanced breast cancer: a phase I/Ib study. *Cancer Commun (Lond)*. 2024; 44(7):833-851.
19. Li Y, Zeng D, Wu Y, et al. Effectiveness and safety of disitamab vedotin (RC48) in pretreated HER2-positive advanced breast cancer: a real-world experience in China. *J Clin Oncol*. 2024;42(16_suppl):e13022-e13022.
20. Peng Z, Liu T, Wei J, et al. Efficacy and safety of a novel anti-HER2 therapeutic antibody RC48 in patients with HER2-overexpressing, locally advanced or metastatic gastric or gastroesophageal junction cancer: a single-arm phase II study. *Cancer Commun*. 2021;41(11):1173-1182.
21. Sheng X, Wang L, He Z, et al. Efficacy and safety of disitamab vedotin in patients with human epidermal growth factor receptor 2-positive locally advanced or metastatic urothelial carcinoma: a combined analysis of two phase II clinical trials. *J Clin Oncol*. 2024;42(12):1391-1402.
22. Martin LP, Konner JA, Moore KN, et al. Characterization of folate receptor alpha (FRα) expression in archival tumor and biopsy samples from relapsed epithelial ovarian cancer patients: a phase I expansion study of the FRα-targeting antibody-drug conjugate mirvetuximab soravtansine. *Gynecol Oncol*. 2017;147(2):402-407.
23. Moore KN, Angelergues A, Konecny GE, et al. Mirvetuximab soravtansine in FRα-Positive, platinum-resistant ovarian cancer. *N Engl J Med*. 2023;389(23): 2162-2174.
24. Dilawari A, Shah M, Ison G, et al. FDA approval summary: mirvetuximab soravtansine-gynx for frα-positive, platinum-resistant ovarian cancer. *Clin Cancer Res*. 2023;29(19): 3835-3840.
25. Matulonis UA, Lorusso D, Oaknin A, et al. Efficacy and safety of mirvetuximab soravtansine in patients with platinum-resistant ovarian cancer with high folate receptor alpha expression: results from the SORAYA study. *J Clin Oncol*. 2023;41(13):2436-2445.
26. Deutschman E, Fulton R, Sloss CM. Evaluation of laboratory-derived immunohistochemical assays for folate receptor α expression in epithelial ovarian cancer and

comparison with a companion diagnostic. *Arch Pathol Lab Med*. 2025;149(10):930-937.
27. Sierra JR, Tsao MS. c-MET as a potential therapeutic target and biomarker in cancer. *Ther Adv Med Oncol*. 2011;3(Suppl 1):S21-S35.
28. Camidge DR, Bar J, Horinouchi H, et al. Telisotuzumab vedotin monotherapy in patients with previously treated c-MET protein-overexpressing advanced nonsquamous egfr-wildtype non-small cell lung cancer in the phase II LUMINOSITY Trial. *J Clin Oncol*. 2024;42(25):3000-3011.
29. Lu S, Goldman JW, Tanizaki J, et al. A phase 3 global study of telisotuzumab vedotin versus docetaxel in previously treated patients with c-MET overexpressing, EGFR wild-type, locally advanced/metastatic nonsquamous NSCLC (TeliMET NSCLC-01). *J Clin Oncol*. 2024;42(16_suppl): TPS8656.
30. Hu Y, Zhu Y, Qi D, Tang C, Zhang W. Trop2-targeted therapy in breast cancer. *Biomark Res*. 2024;12(1):82.
31. Bardia A, Rugo HS, Tolaney SM, et al. Final results from the randomized phase III ASCENT clinical trial in metastatic triple-negative breast cancer and association of outcomes by human epidermal growth factor receptor 2 and trophoblast cell surface antigen 2 expression. *J Clin Oncol*. 2024;42(15):1738-1744.
32. Bardia A, Jhaveri K, Im SA, et al. Datopotamab deruxtecan versus chemotherapy in previously treated inoperable/metastatic hormone receptor-positive human epidermal growth factor receptor 2-negative breast cancer: primary results from TROPION-Breast01. *J Clin Oncol*. 2025;43(3): 285-296.
33. Meric-Bernstam F, Yuca E, Evans KW, et al. Antitumor activity and biomarker analysis for TROP2 antibody-drug conjugate datopotamab deruxtecan in patient-derived breast cancer xenograft models. *Clin Cancer Res*. 2025;31(3): 573-587.
34. Ahn MJ, Tanaka K, Paz-Ares L, et al. Datopotamab deruxtecan versus docetaxel for previously treated advanced or metastatic non-small cell lung cancer: the randomized, open-label phase III TROPION-Lung01 study. *J Clin Oncol*. 2025;43(3):260-272.
35. Garassino MC, Sands J, Paz-Ares L, et al. PL02.11 normalized membrane ratio of TROP2 by quantitative continuous scoring is predictive of clinical outcomes in TROPION-Lung 01. *J Thorac Oncol*. 2024;19(10, Supplement):S2-S3.
36. Mathias-Machado MC, de Jesus VHF, Jácome A, et al. Claudin 18.2 as a new biomarker in gastric cancer-what should we know? *Cancers (Basel)*. 2024;16(3):679.
37. Wang Y, Gong J, Lin R, et al. First-in-human dose escalation and expansion study of SYSA1801, an antibody-drug conjugate targeting claudin 18.2 in patients with resistant/refractory solid tumors. *J Clin Oncol*. 2023; 41(Suppl 16):3016-3016.
38. Xu R-H, Wei X, Zhang D, et al. A phase 1a dose-escalation, multicenter trial of anti-claudin 18.2 antibody drug conjugate CMG901 in patients with resistant/refractory solid tumors. *J Clin Oncol*. 2023;41(Suppl 4):352-352.
39. Fassan M, Kuwata T, Matkowskyj KA, Röcken C, Rüschoff J. Claudin-18.2 immunohistochemical evaluation in gastric and gastroesophageal junction adenocarcinomas to direct targeted therapy: a practical approach. *Mod Pathol*. 2024;37(11):100589.
40. Ascione L, Guidi L, Prakash A, et al. Unlocking the potential: biomarkers of response to antibody-drug conjugates. *Am Soc Clin Oncol Educ Book*. 2024;44(3):e431766.
41. Katrini J, Boldrini L, Santoro C, Valenza C, Trapani D, Curigliano G. Biomarkers for antibody-drug conjugates in solid tumors. *Mol Cancer Ther*. 2024;23(4):436-446.
42. Feldt SL, Bestvina CM. The role of MET in resistance to EGFR inhibition in NSCLC: a review of mechanisms and treatment implications. *Cancers (Basel)*. 2023;15(11):2998.
43. Püsküllüoğlu M, Rudzińska A, Pacholczak-Madej R. Antibody-drug conjugates in HER-2 negative breast cancers with poor prognosis. *Biochim Biophys Acta Rev Cancer*. 2023;1878(6):188991.
44. Venetis K, Crimini E, Sajjadi E, et al. HER2 low, ultra-low, and novel complementary biomarkers: expanding the spectrum of HER2 positivity in breast cancer. *Front Mol Biosci*. 2022;9:834651.
45. Wong JL, Rosenberg JE. Targeting nectin-4 by antibody-drug conjugates for the treatment of urothelial carcinoma. *Expert Opin Biol Ther*. 2021;21(7):863-873.
46. Dernbach G, Eich ML, Dragomir MP, et al. Spatial expression of HER2, NECTIN4, and TROP-2 in muscle-invasive bladder cancer and metastases: implications for pathological and clinical management. *Mod Pathol*. 2025; 38(7):100753.
47. Powles T, Rosenberg JE, Sonpavde GP, et al. Enfortumab vedotin in previously treated advanced urothelial carcinoma. *N Engl J Med*. 2021;384(12):1125-1135.
48. Wang N, Tully KH. Balancing effectiveness, toxicity, and individualization: enfortumab vedotin in advanced urothelial cancer. *Transl Androl Urol*. 2025;14(3):503-506.
49. Passaro A, Al Bakir M, Hamilton EG, et al. Cancer biomarkers: emerging trends and clinical implications for personalized treatment. *Cell*. 2024;187(7):1617-1635.
50. Abelman RO, Wu B, Barnes H, et al. *TOP1* mutations and cross-resistance to antibody-drug conjugates in patients with metastatic breast cancer. *Clin Cancer Res*. 2025;31(10): 1966-1974.
51. Li G, Guo J, Shen BQ, et al. Mechanisms of acquired resistance to trastuzumab emtansine in breast cancer cells. *Mol Cancer Ther*. 2018;17(7):1441-1453.
52. Mosele F, Deluche E, Lusque A, et al. Trastuzumab deruxtecan in metastatic breast cancer with variable HER2 expression: the phase 2 DAISY trial. *Nat Med*. 2023;29(8): 2110-2120.
53. Wu B, Zhang B, Li B, Wu H, Jiang M. Cold and hot

tumors: from molecular mechanisms to targeted therapy. *Signal Transduct Target Ther*. 2024;9(1):274.
54. Pretelli G, Mati K, Motta L, Stathis A. Antibody-drug conjugates combinations in cancer treatment. *Explor Target Antitumor Ther*. 2024;5(3):714-741.
55. Ascione L, Crimini E, Trapani D, Marra A, Criscitiello C, Curigliano G. Predicting response to antibody drug conjugates: a focus on antigens' targetability. *Oncologist*. 2023; 28(11):944-960.
56. Schrijver WAME, Suijkerbuijk KPM, van Gils CH, van der Wall E, Moelans CB, van Diest PJ. Receptor conversion in distant breast cancer metastases: a systematic review and meta-analysis. *J Natl Cancer Inst*. 2018;110(6):568-580.
57. Almstedt K, Krauthauser L, Kappenberg F, et al. Discordance of HER2-Low between primary tumors and matched distant metastases in breast cancer. *Cancers (Basel)*. 2023; 15(5):1413.
58. Bartley AN, Washington MK, Ventura CB, et al. HER2 testing and clinical decision making in gastroesophageal adenocarcinoma: guideline from the college of American pathologists, American society for clinical pathology, and American society of clinical oncology. *Am J Clin Pathol*. 2016;146(6):647-669.
59. Bartley AN, Washington MK, Colasacco C, et al. HER2 testing and clinical decision making in gastroesophageal adenocarcinoma: guideline from the college of American pathologists, American society for clinical pathology, and the American society of clinical oncology. *J Clin Oncol*. 2017;35(4):446-464.
60. Uzunparmak B, Haymaker C, Raso G, et al. HER2-low expression in patients with advanced or metastatic solid tumors. *Ann Oncol*. 2023;34(11):1035-1046.
61. Furrer D, Sanschagrin F, Jacob S, Diorio C. Advantages and disadvantages of technologies for HER2 testing in breast cancer specimens. *Am J Clin Pathol*. 2015;144(5): 686-703.
62. Monné Rodríguez JM, Frisk AL, Kreutzer R, et al. European society of toxicologic pathology (pathology 2.0 molecular pathology special interest group): review of *in situ* hybridization techniques for drug research and development. *Toxicol Pathol*. 2023;51(3):92-111.
63. Caputo V, De Falco V, Ventriglia A, et al. Comprehensive genome profiling by next generation sequencing of circulating tumor dna in solid tumors: a single academic institution experience. *Ther Adv Med Oncol*. 2022;14: 17588359221096878.
64. Mehta GU, Vellanki PJ, Ren Y, et al. FDA approval summary: fam-trastuzumab deruxtecan-nxki for unresectable or metastatic non-small cell lung cancer with activating *HER2* mutations. *Oncologist*. 2024;29(8):667-671.
65. Coates JT, Sun S, Leshchiner I, et al. Parallel genomic alterations of antigen and payload targets mediate polyclonal acquired clinical resistance to sacituzumab govitecan in triple-negative breast cancer. *Cancer Discov*. 2021;11(10): 2436-2445.
66. Giesen C, Wang HA, Schapiro D, et al. Highly multiplexed imaging of tumor tissues with subcellular resolution by mass cytometry. *Nat Methods*. 2014;11(4):417-422.
67. Angelo M, Bendall SC, Finck R, et al. Multiplexed ion beam imaging of human breast tumors. *Nat Med*. 2014; 20(4):436-442.
68. Wolff AC, Somerfield MR, Dowsett M, et al. Human epidermal growth factor receptor 2 testing in breast cancer: ASCO-College of American pathologists guideline update. *J Clin Oncol*. 2023;41(22):3867-3872.
69. Poalelungi DG, Neagu AI, Fulga A, et al. Revolutionizing pathology with artificial intelligence: innovations in immunohistochemistry. *J Pers Med*. 2024;14(7):693.
70. Selcuk SY, Yang X, Bai B, et al. Automated HER2 scoring in breast cancer images using deep learning and pyramid sampling. *BME Front*. 2024;5:0048.
71. Xiong Z, Liu K, Liu S, et al. Precision HER2: a comprehensive AI system for accurate and consistent evaluation of HER2 expression in invasive breast Cancer. *BMC Cancer*. 2024;24(1):1204.
72. Brattoli B, Mostafavi M, Lee T, et al. A universal immunohistochemistry analyzer for generalizing AI-driven assessment of immunohistochemistry across immunostains and cancer types. *NPJ Precis Oncol*. 2024;8(1):277.
73. Wang JM, Hong R, Demicco EG, et al. Deep learning integrates histopathology and proteogenomics at a pan-cancer level. *Cell Rep Med*. 2023;4(9):101173.
74. Prelaj A, Miskovic V, Zanitti M, et al. Artificial intelligence for predictive biomarker discovery in immuno-oncology: a systematic review. *Ann Oncol*. 2024;35(1):29-65.
75. Albuquerque DAN, Vianna MT, Sampaio LAF, Vasiliu A, Neves Filho EHC. Systematic review and meta-analysis of artificial intelligence in classifying HER2 status in breast cancer immunohistochemistry. *NPJ Digit Med*. 2025;8(1):144.
76. Kapil A, Spitzmüller A, Brieu N, et al. HER2 quantitative continuous scoring for accurate patient selection in HER2 negative trastuzumab deruxtecan treated breast cancer. *Sci Rep*. 2024;14(1):12129.
77. Wen Z, Luo D, Wang S, et al. Deep learning-based H-score quantification of immunohistochemistry-stained images. *Mod Pathol*. 2024;37(2):100398.
78. Molla Desta G, Birhanu AG. Advancements in single-cell RNA sequencing and spatial transcriptomics: transforming biomedical research. *Acta Biochim Pol*. 2025;72:13922.
79. Hu B, He R, Pang K, et al. High-resolution spatially resolved proteomics of complex tissues based on microfluidics and transfer learning. *Cell*. 2025;188(3):734-748. e22.
80. Ma L, Guo H, Zhao Y, et al. Liquid biopsy in cancer current: status, challenges and future prospects. *Signal Transduct Target Ther*. 2024;9(1):336.

81. Jänne PA, Baik C, Su WC, et al. Efficacy and safety of patritumab deruxtecan (HER3-DXd) in EGFR inhibitor-Resistant, *EGFR*-mutated non-small cell lung cancer. *Cancer Discov*. 2022;12(1):74-89.
82. Wen X, Pu H, Liu Q, Guo Z, Luo D. Circulating tumor DNA—a novel biomarker of tumor progression and its favorable detection techniques. *Cancers (Basel)*. 2022; 14(24):6025.
83. Huang W, Zhou J, Liu Y, et al. Advances in immunoPET/SPECT imaging: the role of Fab and $F(ab')_2$ fragments in theranostics. *Acta Pharm Sin B*. 2025;15(8):3888-3924.
84. Zhang S, Wang X, Gao X, et al. Radiopharmaceuticals and their applications in medicine. *Signal Transduct Target Ther*. 2025;10(1):1.
85. Mileva M, de Vries EGE, Guiot T, et al. Molecular imaging predicts lack of T-DM1 response in advanced HER2-positive breast cancer (final results of ZEPHIR trial). *NPJ Breast Cancer*. 2024;10(1):4.
86. Di Maio M, Perrone F, Conte P. Real-world evidence in oncology: opportunities and limitations. *Oncologist*. 2020; 25(5):e746-e752.
87. von Minckwitz G, Huang CS, Mano MS, et al. Trastuzumab emtansine for residual invasive HER2-positive breast cancer. *N Engl J Med*. 2019;380(7):617-628.
88. Loibl S, Huang CS, Mano MS, et al. Adjuvant trastuzumab emtansine in HER2-positive breast cancer patients with HER2-negative residual invasive disease in KATHERINE. *NPJ Breast Cancer*. 2022;8(1):106.
89. Yamaguchi K, Bang YJ, Iwasa S, et al. Trastuzumab deruxtecan in anti-human epidermal growth factor receptor 2 treatment-naive patients with human epidermal growth factor receptor 2-low gastric or gastroesophageal junction adenocarcinoma: exploratory cohort results in a phase II trial. *J Clin Oncol*. 2023;41(4):816-825.
90. Goto K, Goto Y, Kubo T, et al. Trastuzumab deruxtecan in patients with *HER2*-mutant metastatic non-small-cell lung cancer: primary results from the randomized, phase II DESTINY-Lung02 trial. *J Clin Oncol*. 2023;41(31):4852-4863.
91. Sheng X, Yan X, Wang L, et al. Open-label, multicenter, phase II study of RC48-ADC, a HER2-targeting antibody-drug conjugate, in patients with locally advanced or metastatic urothelial carcinoma. *Clin Cancer Res*. 2021; 27(1):43-51.