

apjtm.org

Case Report

Asian Pacific Journal of Tropical Medicine

doi: 10.4103/apjtm.apjtm_696_25

Mycotic aortic aneurysm associated with salmonellosis presenting as a fatal triad of aortitis, spondylodiscitis, and iliopsoas abscess: A case report

Ling Lee[1,2], Sung-Yuan Hu[1,2,3,4,5,6]✉, Chung-Lin Tsai[3,7], Tzu-Chiang Chiang[8]

[1]*School of Medicine, National Defense Medical University, Taipei, 114201, Taiwan, China*

[2]*Department of Emergency Medicine, Taichung Veterans General Hospital, Taichung, 407219, Taiwan, China*

[3]*Department of Post-Baccalaureate Medicine, National Chung Hsing University, Taichung, 40227, Taiwan, China*

[4]*School of Medicine, Chung Shan Medical University, Taichung, 40201, Taiwan, China*

[5]*Institute of Medicine, Chung Shan Medical University, Taichung, 40201, Taiwan, China*

[6]*School of Medicine, National Yang Ming Chiao Tung University, Taipei, 11221, Taiwan, China*

[7]*Division of Cardiovascular Surgery, Department of Surgery, Taichung Veterans General Hospital, Taichung, 407219, Taiwan, China*

[8]*Department of Information Management, Tunghai University, Taichung, 407224, Taiwan, China*

ABSTRACT

Rationale: Mycotic aortic aneurysm (MAA) is uncommon, accounting for 1%-3% of all aortic aneurysms. Delayed treatment carries a high risk of rapid enlargement, rupture, and death. MAA may spread contiguously from an abdominal aortic source to the adjacent vertebrae and psoas, resulting in spondylodiscitis and psoas abscess. MAA is an uncommon but life-threatening condition. The simultaneous presentation of an MAA with both spondylodiscitis and an iliopsoas abscess (IPA) represents an exceedingly rare and fatal triad of complications from invasive non-typhoidal *Salmonella* infection.

Patient concerns: A 59-year-old male presented with progressive low back pain and intermittent fever for about 6 six weeks. Imaging revealed multiple infrarenal mycotic aortic aneurysms, an L3-L4 spondylodiscitis, and extensive bilateral IPAs. Blood and abscess cultures identified *Salmonella* group D1.

Diagnosis: Salmonellosis associated with mycotic aortic aneurysm.

Intervention: The endovascular stent-graft repair was implanted combined parenteral antibiotics, with initial clinical improvement after surgical debridement for abscess.

Outcome: He represented with recurrent *Salmonella* bacteremia three months later and subsequently expired.

Lessons: Physician must keep a high index of suspicion for an underlying MAA in patients presenting with spondylodiscitis or IPA. It tragically illustrates the significant risk of treatment failure with endovascular stent-graft repair, emphasizing that rigorous long-term surveillance is essential for patients managed with this approach.

KEYWORDS: Aortitis; Iliopsoas abscess; Mycotic aortic aneurysm; *Salmonella*; Spondylodiscitis

1. Introduction

Mycotic aortic aneurysm (MAA) is a rare but lethal condition, accounting for 1%-3% of all aortic aneurysms[1]. Invasive non-

✉To whom correspondence may be addressed. E-mail: song9168@pie.com.tw

This is an open access article distributed under the terms of the Creative Commons Attribution-Non-Commercial-No Derivatives License 4.0 (CCBY-NC-ND), where it is permissible to download and share the work provided it is properly cited. The work cannot be changed in any way or used commercially without permission from the journal.

For reprints contact: reprints@medknow.com

©2026 *Asian Pacific Journal of Tropical Medicine* Produced by Wolters Kluwer-Medknow.

How to cite this article: Lee L, Hu SY, Tsai CL, Chiang TC. Mycotic aortic aneurysm associated with salmonellosis presenting as a fatal triad of aortitis, spondylodiscitis, and iliopsoas abscess: A case report. Asian Pac J Trop Med 2026; 19(5): 222-225.

Article history: Received 30 November 2025 Revision 10 February 2026
Accepted 21 May 2026 Available online 29 May 2026

typhoidal *Salmonella* (iNTS) is a leading causative agent, especially in Asian cohorts, and is associated with a particularly aggressive clinical course[2]. The infection typically seeds pre-existing atherosclerotic plaques during transient bacteremia, leading to rapid arterial wall destruction[3]. While contiguous spread of the infection to adjacent structures such as the spine or the psoas muscle has been described, the concurrent presentation of an MAA with both spondylodiscitis and an iliopsoas abscess (IPA) is exceedingly rare[4]. We report a case of *Salmonella*-induced MAA presenting as this fatal triad, highlighting the profound diagnostic and therapeutic challenges.

2. Case history

A 59-year-old male cook, with a history of long-term smoking and daily alcohol consumption, presented with a six-week history of progressive low back pain and intermittent fever. On examination, he had pale conjunctivae and localized lumbar tenderness. Laboratory tests were significant for leukocytosis (11 780/μL with 86.2% neutrophils), severe anemia (hemoglobin 7.6 g/dL), and markedly elevated inflammatory markers (C-reactive protein 14.93 mg/dL, ESR >140 mm/h). Further laboratory data were shown in Table 1.

Table 1. Significantly abnormal laboratory data of the first admission in the present patient.

Laboratory items	Patient data	Reference range
White blood cell count, $\times 10^9$/L	11.8	3.9-10.6
Neutrophils, %	86.2	40.0-75.0
Hemoglobin, g/dL	7.6	13.5-17.5
Albumin, g/dL	3.1	3.5-5
Alkaline phosphatase, U/L	203	40-150
C-reactive protein, mg/dL	14.93	<0.50
Erythrocyte sedimentation rate, mm/h	>140	0-20
Lactate, mg/dL	36.2	4.5-19.8

Given the non-specific symptoms, a contrast-enhanced computed tomography angiography was performed. It revealed a catastrophic constellation of findings: multiple infrarenal MAAs with a periaortic abscess, L3-L4 spondylodiscitis with vertebral body destruction, and extensive bilateral IPAs with an associated paraspinal abscess as shown in Figure 1.

The patient was started on empiric broad-spectrum antibiotics with ceftriaxone 2 000 mg per day. One week later, he underwent a hybrid procedure consisting of endovascular stent-graft repair (EVAR) of the aorta (Figure 1), followed by orthopedic debridement of the multiple abscesses. The cultures of blood and intraoperative abscess subsequently yielded *Salmonella* group D1 (*Salmonella enteritidis*) and the results of antibiotic sensitivity test revealed sensitivity to ampicillin/sulbactam, ceftriaxone, cefepime, and *etc*.

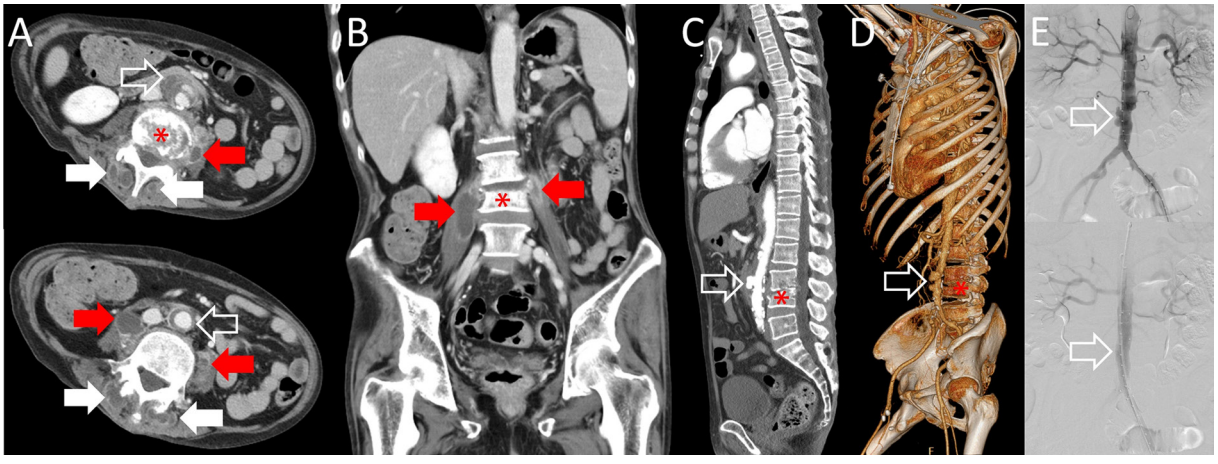

Figure 1. Images from a 59-year-old male with mycotic aortic aneurysm associated with salmonellosis. The axial (A), coronal (B), and sagittal (C) views demonstrated infrarenal mycotic aneurysms with paraaortic abscesses (white hollow arrows), bilateral psoas muscle abscesses (red arrows), paraspinal abscess (white arrows), and spondylodiscitis (red asterisk) at the third and fourth lumbar vertebral body levels. The reconstructive images (D) depicted infrarenal mycotic aneurysms (white hollow arrows) and spondylodiscitis (red asterisk) at the third and fourth lumbar vertebral body levels. The aortography (E) revealed infrarenal mycotic aneurysms (white hollow arrow) and endovascular aortic repair (EVAR) with implantation of a stent graft (white hollow arrow) to treat infrarenal mycotic aneurysms.

(Supplementary materials). The antibiotic regimen was tailored to cefepime and continued intravenously for six weeks. Initial follow-up showed clinical and radiological improvement, with patent endografts and negative repeat blood cultures. The patient was transferred to the local veteran's hospital for the use of long-term antibiotics. However, after approximately three months, the patient was re-admitted with pneumonia and recurrent *Salmonella* bacteremia. The repeated computed tomography angiography depicted presence of a marginal enhancing lesion next to the stent with gas bubble and compression fracture of L4 (Supplementary materials). Surgical intervention for eradication of infectious focus with graft replacement was recommended. However, it carried a high risk of mortality for the patient with septicemia and multiorgan failure. The poor prognosis of recurrent bacteremia caused by MAA was explained to the family. In accordance with the family's do-not-resuscitate decision, he was transitioned to comfort care and subsequently expired.

3. Discussion

This case presented the severe spectrum of invasive salmonellosis and its devastating vascular complications. The patient's occupation as a chef suggests a plausible, yet often overlooked, portal of entry for his bacteremia, likely through frequent occupational exposure to contaminated eggs—a known source of *Salmonella enteritidis*[5]. This highlights the importance of obtaining a thorough dietary and occupational history in patients with suspected infective vascular disease.

A critical feature of this case is the diagnostic challenge posed by the rare triad of MAA, spondylodiscitis, and IPA. The MAA was diagnosed incidentally during the workup for a suspected IPA, which was prompted by the patient's presenting symptom of back pain. This diagnostic journey critically underscores the need for a high index of suspicion for an underlying aortic pathology in any patient presenting with an IPA or spondylodiscitis. Early cross-sectional imaging is essential, as delayed diagnosis of the vascular source is almost fatal[6].

The management of MAA presents a significant clinical dilemma. The choice between traditional open surgery repair (OSR) and EVAR is controversial. While OSR allows for radical debridement of the infectious source, it carries a prohibitively high perioperative mortality rate in critically ill patients[7]. In contrast, EVAR has emerged as a viable, less-invasive alternative for acute stabilization, particularly in high-risk patients[8]. In this case, EVAR was reasonably chosen as a first-line damage-control strategy.

However, the fatal recurrence of bacteremia three months later, despite initial improvement, tragically illustrates the primary risk of EVAR in infected fields: failure of source control. The endograft, a foreign body, can provide a surface where bacteria can colonize and shield themselves from antibiotics, making complete eradication of the infection exceedingly difficult[9]. This outcome is consistent with literature demonstrating the challenge of achieving durable source control with EVAR alone[10].

In conclusion, it emphasizes that for patients managed with an endovascular approach, rigorous and prolonged surveillance is essential. Furthermore, it raises the question of whether EVAR for MAA should be considered a bridge to a definitive open repair in select patients once they are stabilized, rather than a curative treatment. This case serves as a stark reminder of the limitations of modern endovascular therapy in the face of overwhelming infection.

Conflict of interest statement

All authors have no competing of interest to declare.

Ethical approval

The institutional review board (IRB) of Taichung Veterans General Hospital approved this study on 12 Sep 2024 (The study period ranged from 12 Sep 2024 to 11 Sep 2025) (IRB file number: CE24414B).

Consent for publication

Patient's written informed consent for publication was waived as the data were fully anonymized and analyzed retrospectively in accordance with institutional and national research.

Acknowledgements

The authors would like to thank all the staff of the intensive care unit to take care this patient.

Funding

This work was supported by grants from the Taichung Veterans General Hospital (TCVGH), Taichung, Taiwan (TCVGH-T1127801, TCVGH-1137203C, and TCVGHT1137801). The funders had no

role in the study design, data collection, analysis, decision to publish, or preparation of the manuscript. No additional external funding was received for this study.

Data availability

All data generated or analyzed relating to this study are presented within this published article.

Authors' contributions

Conceptualization, LL, SYH; Funding acquisition, SYH; Investigation, LL, SYH, CLT, and TCC; Supervision, SYH and TCC; Validation, SYH and CLT; Writing—original draft, LL and SYH; Writing—review and editing SYH and TCC. All authors contributed to the article and approved the submitted version. All authors have read and agreed to the published version of the manuscript.

References

[1] Raavi L, Garg P, Hussain MWA, Wadiwala IJ, Mateen NT, Elawady MS, et al. Mycotic thoracic aortic aneurysm: Epidemiology, pathophysiology, diagnosis, and management. *Cureus* 2022; **14**(11): e31010.

[2] Hosaka A, Kumamaru H, Takahashi A, Azuma N, Obara H, Miyata T, et al. Nationwide study of surgery for primary infected abdominal aortic and common iliac artery aneurysms. *Br J Surg* 2021; **108**(3): 286-295.

[3] Guo Y, Bai Y, Yang C, Wang P, Gu L. Mycotic aneurysm due to *Salmonella* species: Clinical experiences and review of the literature. *Braz J Med Biol Res* 2018; **51**(9): e6864.

[4] Ng JH, Heng KWJ. Infected native aortic aneurysm with spondylodiscitis in an elderly septic man with back pain. *BMJ Case Rep* 2021; **14**: e235439.

[5] Bermudez-Aguirre D, Carter J, Niemira BA. An investigation about the historic global foodborne outbreaks of *Salmonella* spp. in eggs: From hatcheries to tables. *Compr Rev Food Sci Food Saf* 2025; **24**(3): e70202.

[6] Hu SY, Hsieh MS, Chang YT, Huang CC, Tsai CA, Tsai CL, et al. Clinical features, management, and outcome of iliopsoas abscess associated with cardiovascular disorders: A hospital-based observational case series study. *BMC Musculoskelet Disord* 2019; **20**(1): 474.

[7] Liu MY, Jiao Y, Yang Y, Li Q, Zhang X, Li W, et al. Open surgery and endovascular repair for mycotic aortic aneurysms: Benefits beyond survival. *J Thorac Cardiovasc Surg* 2020; **159**(5): 1708-1717.e3.

[8] Han M, Wang J, Zhao J, Ma Y, Huang B, Yuan D, et al. Systematic review and meta-analysis of outcomes following endovascular and open repair for infective native aortic aneurysms. *Ann Vasc Surg* 2022; **79**: 348-358.

[9] Puppala S, Cuthbert GA, Tingerides C, Russell DA, McPherson SJ. Endovascular management of mycotic aortic aneurysms-A 20-year experience from a single UK centre. *Clin Radiol* 2020; **75**(9): 712.e13-712.e21.

[10]Sorelius K, Wanhainen A, Wahlgren CM, Langenskiold M, Roos H, Resch T, et al. Nationwide study on treatment of mycotic thoracic aortic aneurysms. *Eur J Vasc Endovasc Surg* 2019; **57**(2): 239-246.

Publisher's note

The Publisher of the *Journal* remains neutral with regard to jurisdictional claims in published maps and institutional affiliations.

Edited by Pan Y, Lei Y, Zhang Q

Supplementary

Antibiotic sensitivity test of the patient’s blood culture.

陽性結果 Salmonella Group D1 (Salmonella non-typhi)

菌落數目

菌落量定義： P:Pure H:Heavy M:Moderate S:Slight moderate F:Few E:Enrich

	Ampicillin	Cefazolin	Clindamycin	Clarithromy	Gentamicin	Amikacin	Chloromycin
(1)							
(2)							
(3)							
(4)							

	Unasyn	Penicillin	GM(120ug)	SMX+TMP	Vancomycin	Oxacillin	Cefpirome
(1)	S<=2			S<=20			
(2)							
(3)							
(4)							

	Carbapen(IPM)	Cefoperazone /Sulbactam	Cefotaxime	Ceftazidime	Cefepime	Ceftriaxone	Flomoxef
(1)	S<=0.25	S<=8		S=0.25	S<=0.12	S<=0.25	S<=2
(2)							
(3)							
(4)							

	Metronidazole	Ciprofloxac	Minocycline	Teicoplanin	Tazocin	Cefmetazone	Aztreonam
(1)		S<=0.25			S<=4		
(2)							
(3)							

CTA at 3 months after treatment.

