

Case Report

Asian Pacific Journal of Tropical Medicine

apjtm.org

doi: 10.4103/apjtm.apjtm_553_25

Bilateral abducens nerve palsy in anicteric leptospirosis: A case report

Dipankar Pal✉

Department of Infectious Diseases, School of Tropical Medicine, Kolkata, India

ABSTRACT

Rationale: Neuroleptospirosis is an uncommon manifestation of leptospirosis. Cranial nerve involvement is extremely rare.

Patient concerns: A 17-year-old girl presented with fever, myalgia, and mild transaminitis. Her serology was positive for *Leptospira* in the second week of illness. During her hospital stay she developed bilateral 6th nerve palsy.

Diagnosis: Rare manifestation of neuroleptospirosis presenting as bilateral abducens nerve palsy.

Interventions: Antibiotics, cerebrospinal fluid analysis, retinal examination and careful monitoring.

Outcomes: She recovered without any residual neurological deficit.

Lessons: Patients suffering from acute febrile illness with cranial nerve palsy in tropical and subtropical regions may have central nervous system involvement due to pathogenic leptospires (*i.e.*, neuroleptospirosis). Early suspicion, careful monitoring, and timely intervention are required.

KEYWORDS: Leptospirosis; Neglected tropical disease; Neurological involvement; Abducens nerve palsy

1. Introduction

Leptospiros is thought to be the most widespread zoonosis in the world. A systematic review estimated that there are more than one million cases worldwide, with nearly 60 000 deaths annually. In 2018, the phylogeny of *Leptospira* underwent a major overhaul. Seventy-four species, divided into 2 clades and 4 subclades, have been described. Pathogenic *Leptospirae* were classified into the P1 and P2 subclades, consisting of 21 and 22 species, respectively. The non-pathogenic strains were grouped into the S1 and S2 subclades, consisting of 26 and 5 saprophytes, respectively. *Leptospira interrogans*, the most common etiological species, was classified in the P1 subclade[1].

Leptospira gets transmitted from exposure to urine, blood, and tissues of infected rodents in tropical countries. It has also been reported in temperate countries due to recreational water exposures. The organism persists in the renal tubules of infected mammals and is excreted in urine. Rodents once infected in utero or during birth will remain as asymptomatic carriers and continue to excrete the bacteria in urine. A variety of other wild and domestic animals may become infected and develop clinical disease. Cattle, swine, dogs, horses, sheep, and goats are among the extra-rodent reservoirs. The organism can survive in urine-contaminated soil or water for days to months. It enters *via* cuts, abraded skin, mucus membranes and conjunctiva. Both professional and non-professional exposures may lead to leptospirosis. Recreational activities, household contacts, low socioeconomic status, poor living conditions, as well as residence in flood-prone areas, and travel to endemic areas are the common risk factors for leptospirosis.

Leptospirosis has protean clinical manifestations. Usually, it presents as an acute febrile illness but may be completely asymptomatic. Symptomatic disease is mostly anicteric leptospirosis. In the first week of this illness, it presents with fever, rigor, myalgia, and headache. Approximately one half of the patients

✉To whom correspondence may be addressed. E-mail: dipankarpal.2009@gmail.com

This is an open access article distributed under the terms of the Creative Commons Attribution-Non-Commercial-No Derivatives License 4.0 (CCBY-NC-ND), where it is permissible to download and share the work provided it is properly cited. The work cannot be changed in any way or used commercially without permission from the journal.

For reprints contact: reprints@medknow.com

©2025 *Asian Pacific Journal of Tropical Medicine* Produced by Wolters Kluwer-Medknow.

How to cite this article: Pal D. Bilateral abducens nerve palsy in anicteric leptospirosis: A case report. Asian Pac J Trop Med 2025; 18(12): 565-568.

Article history: Received 29 September 2025 Revision 14 December 2025
Accepted 21 December 2025 Available online 24 December 2025

have nausea and vomiting. One-third of the patients may have non-productive cough. Arthralgia, bone pain, acalculous cholecystitis and pancreatitis may be present less frequently. Leptospirosis is a biphasic illness. The initial acute febrile phase usually persists for 7 days, followed by an immune phase that may last up to 30 days. In the immune phase, *Leptospira* are cleared from the blood and anti-*Leptospira* antibodies start to appear. Leptospiruria is present and may aid in diagnosis in this second phase. Aseptic meningitis may manifest in this immune phase. Symptoms of meningitis usually disappear in one or two days. Uveitis is another manifestation of the immune phase which may either be unilateral or bilateral. Both meningitis and uveitis have excellent prognosis. *Leptospira* usually affects the central nervous system (CNS) *via* immune-mediated damage, as described in a large study in Vietnam[2]. Rarely it may directly involve the central nervous system.

In 5%-10% of cases, leptospirosis may present as a fulminant or fatal disease involving the liver, lungs, and kidneys, along with bleeding from various sites—a form known as icteric leptospirosis. This severe presentation, referred to as Weil's disease, has an overall mortality rate of 10%-15%[3]. Early suspicion and diagnosis may reduce morbidity and case fatality.

2. Case report

A 17-year-old girl from rural West Bengal with no pre-existing comorbidities presented with fever, headache, and myalgia. The fever was high-grade and intermittent, and she had taken antipyretics for temporary relief. She consulted a physician, but despite receiving oral antibiotics, her fever persisted. Three days later, she developed pain in the upper abdomen and a few episodes of vomiting. Her condition deteriorated, and she was taken to a local hospital, where she was admitted and received intravenous fluids, ciprofloxacin and metronidazole injections. As her condition failed to improve, she was brought to Kolkata and admitted to our department.

On admission, she was febrile, with headache, vomiting, and upper abdominal pain. Her blood pressure was 100/68 mmHg, pulse was 98 beats per minute, and temperature was 37.7 ℃. Respiratory, cardiovascular, and neurological status was normal. On general examination, she had no pallor but mild icterus. Abdominal examination revealed mild hepatosplenomegaly. Other systems were unremarkable. Blood cultures and other routine investigations were sent for tropical fever workup. She was started on intravenous ceftriaxone 2 g once daily along with other supportive medications. Malarial parasites were absent; dengue IgM and scrub typhus IgM were negative. Urine routine analysis showed no active sediment. Hemoglobin was 10.8 g/dL, total leukocyte count: 7 800/mm^3 , and platelets: 187 000/mm^3 . Liver function tests were normal except for mild transaminitis, with AST of 78 U/L and ALT of 69 U/L. Chest radiograph was normal. Abdominal ultrasonography showed mild hepatosplenomegaly without ascites. She became afebrile after 48 h of antibiotic therapy; her appetite improved, vomiting resolved, and abdominal pain gradually lessened. Blood cultures showed no organism growth after 72 h of incubation. *Leptospira* IgM ELISA was borderline positive [10.6 nephelometric turbidity units (NTU); <9 NTU=negative].

On day 3 of admission, she started to complain of diplopia when looking at distant objects. She had no complaints of projectile vomiting, and there was no recurrence of headache or fever. On examination, there was no neck stiffness and her mental status was normal. A convergent squint was noted on neutral gaze (Figure 1A). Cranial nerve examination revealed bilateral sixth nerve palsy. An ophthalmologist was consulted, and fundoscopy showed no evidence of papilledema (Figure 1B). A brain CT was performed, with no evidence of meningeal enhancement or other radiological abnormalities (Figure 1C). The CSF opening pressure was normal, and the fluid was clear and colorless. Cerebrospinal fluid (CSF) analysis showed a protein level of 80 mg/dL, glucose of 43 mg/dL, and a total cell count of 20/mm^3 (all lymphocytes). Xpert MTB/RIF (GeneXpert) was negative for *Mycobacterium tuberculosis*. CSF PCR for *Leptospira* was negative. CSF cultures were sent, and she was maintained on the same antibiotic regimen. A diagnosis of neuroleptospirosis was made based on her clinical presentation and CSF findings. As there was no definitive indication for systemic steroids in the treatment of CNS involvement due to leptospirosis, steroids were not administered. She was closely monitored, and from day 5 onward, her ocular symptoms began to improve. CSF cultures showed no organism growth. She received a total of 7 days of intravenous ceftriaxone in accordance with published guidelines[4]. She was discharged in a stable condition, and one week later, her lateral rectus palsy had completely resolved (Figure 1A).

3. Discussion

Leptospirosis is an important cause of acute febrile illness in Africa, South and Central America, Australia, and Southeast Asia including India. The first phase is characterized by acute febrile illness due to Leptospiraemia or septicaemia, which may last for up to 7 days. IgM antibodies against *Leptospira* develop in the second phase. The patients may have immune-mediated complications involving one or more organs.

The CNS is involved rather uncommonly in leptospirosis. CNS manifestations are seen in the immune phase of anicteric leptospirosis. Severe leptospirosis that involves major organs—manifesting as jaundice, acute respiratory distress syndrome, and bleeding—represents a separate entity known as Weil's disease and is observed in a subset of patients. *Leptospira* can enter the CSF as early as 48 hours after inoculation into the human body. Neuroleptospirosis, though rare, has protean manifestations. Aseptic meningitis is the most common

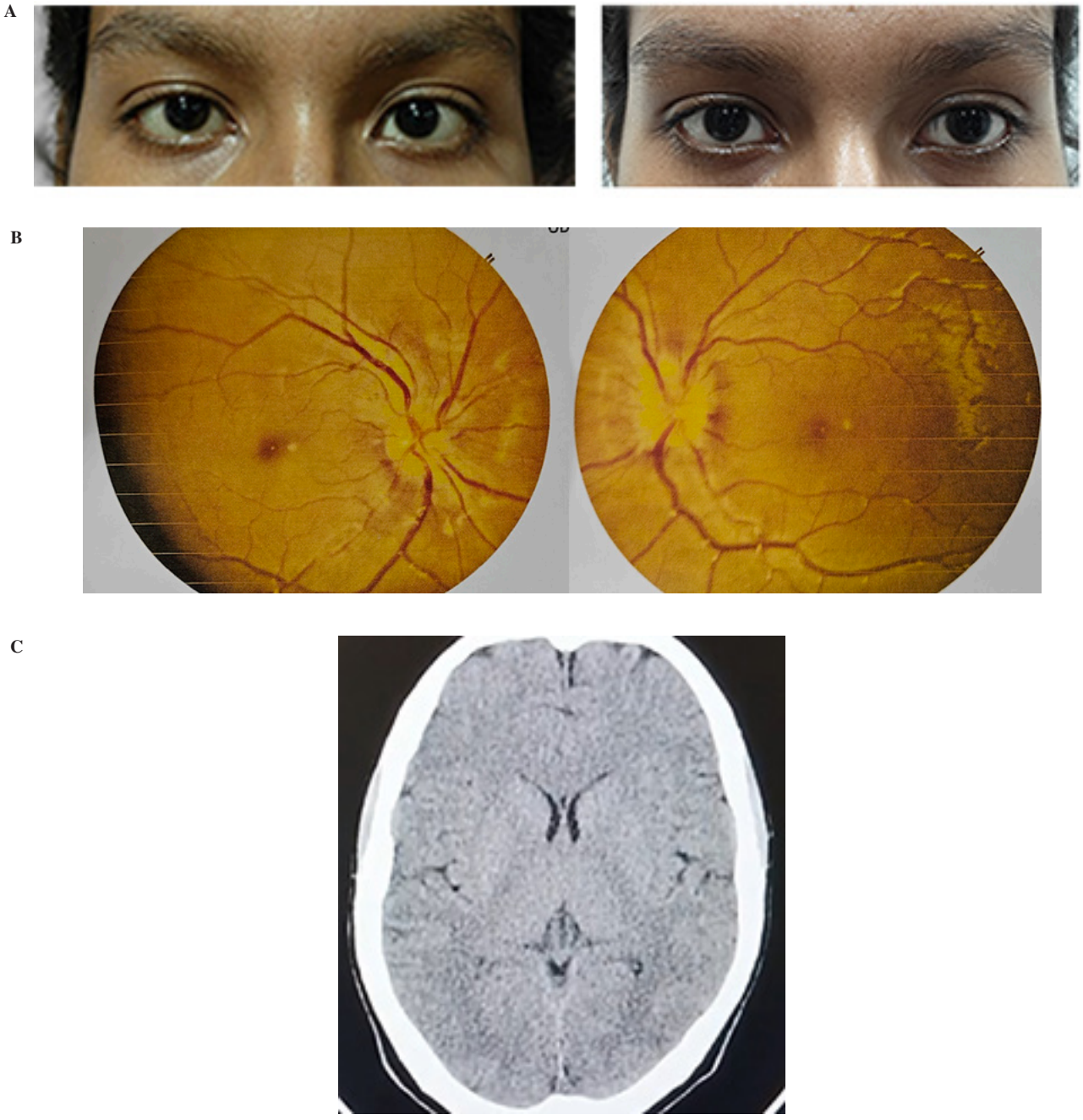

Figure 1. Clinical and radiological findings in a 17-year-old girl with neuroleptospirosis and bilateral abducens nerve palsy. A: Convergent squint secondary to bilateral abducens nerve palsy at disease presentation (left panel); complete resolution of sixth nerve palsy and icterus one week after treatment (right panel). B: Fundoscopic examination revealing no evidence of papilledema. C: Contrast-enhanced brain computed tomography scan showing no radiological abnormalities. The patient provided consent to the use of the photos.

manifestation encountered. CSF typically has an elevated opening pressure with normal cellularity and biochemistry. The organism may be isolated from the CSF during this phase. The immune phase is characterized by elevated protein, normal glucose, and lymphocytic pleocytosis (typically <500 cells/μL). *Leptospira* antibodies may become detectable in the CSF, but viable organisms will be absent. Immune-mediated capillary endothelial damage and vasculitis are the underlying pathologies of CNS manifestations. Myeloradiculopathy, myelopathy, cerebellitis, and transverse myelitis are among the rarer manifestations[5].

Optic neuritis and facial nerve palsy have been reported in the literature[6]. Abducens nerve palsy is extremely rare in neuroleptospirosis, with only a single case having been reported to date[7]. This palsy can be due to direct damage to the sixth cranial

nerve, brainstem nuclei, or, less frequently, diffuse axonal damage. Bilateral sixth nerve palsy is a rare clinical condition.

In our patient, the girl suddenly developed horizontal gaze diplopia when looking at distant objects. It began on day 3 of hospital admission after defervescence. CSF analysis showed elevated protein levels and lymphocytic pleocytosis. The opening pressure was normal and there was no neck rigidity. Her clinical syndrome, CSF findings, and the timing of sixth nerve palsy onset all point towards neuroleptospirosis developing in the immune phase. Asymptomatic aseptic meningitis developed, followed by bilateral sixth nerve palsy. There was no clinical, radiological, or ophthalmological evidence of elevated intracranial pressure causing sixth nerve palsy. The sixth nerve was likely affected via an immune-mediated mechanism, with subsequent complete recovery. CSF PCR for *Leptospira* was negative because it was performed during the second phase of illness; by that time, the organism must have been cleared by immune cells. She completed a total of 7 days of intravenous ceftriaxone and was discharged in a stable condition. Ophthalmological examination did not reveal any compelling indication for systemic steroids. Her recovery was uneventful, and she had no residual neurological deficit one week post-discharge. *Leptospira* IgM ELISA was repeated after two weeks and was positive, with an OD value of 12.68 (>11 NTU=positive). Her initial borderline serology became positive after two weeks. This further confirms our diagnosis and underscores the importance of repeating serology after a couple of weeks when clinical suspicion is high.

Neuroleptospirosis, though uncommon, should be kept in the differential diagnosis by clinicians when an acute febrile illness is complicated by neurological manifestations. Cranial nerve involvement is extremely rare. Our case is likely the second reported case involving the abducens nerve. Cranial nerve involvement in leptospirosis does not typically warrant systemic steroids. Careful multidisciplinary follow-up by the treating physician and ophthalmology team is often sufficient.

Conflict of interest statement

The author declares that they have no conflict of interest.

Ethical approval and patient's consent

Written informed consent was obtained from the patient's father for publication of this case report and accompanying images.

Acknowledgements

The author would like to express their gratitude to Prof. Nagarathna, Dept of Neuromicrobiology, NIMHANS, Bengaluru, India; Dr. Sambuddha Kundu, Ophthalmologist from Kolkata; Dr. Pramitasri Bhattacharya, Physician from Kolkata; Dr. Akash Shah, Pathologist; Dr. Ashish Kumar Jha, Pathologist; Mr. Koushik Ganguly and Dr. Chandan Singh, Recovery Nursing Home, Kolkata; the Pulse Diagnostic Laboratory, Kolkata; the Body Care Laboratory, Kolkata; and the Metropolis Laboratory, Kolkata, India.

Funding

No funding was received from anyone or any organization regarding this case.

Authors' contributions

DP was involved in patient care, manuscript writing, literature review, and submitting the revised manuscript.

References

[1] Vincent AT, Schiettekatte O, Goarant C, Neela VK, Bernet E, Thibeaux R, et al. Revisiting the taxonomy and evolution of pathogenicity of the genus *Leptospira* through the prism of genomics. *PLoS Negl Trop Dis* 2019; **13**(5): e0007270.

[2] Berman SJ, Tsai CC, Holmes K, Fresh JW, Watten RH. Sporadic anicteric leptospirosis in South Vietnam. A study in 150 patients. *Ann Intern Med* 1973; **79**(2): 167-173.

[3] Pavli A, Maltezou HC. Travel-acquired leptospirosis. *J Travel Med* 2008; **15**(6): 447-453.

[4] Panaphut T, Domrongkitchaiporn S, Vibhagool A, Thinkamrop B, Susaengrat W. Ceftriaxone compared with sodium penicillin G for treatment of severe leptospirosis.*Clin Infect Dis* 2003; **36**(12): 1507-1513.

[5] Abraham M. The central nervous system in leptospirosis. *Kerala Medical J* 1998; **38**: 21-22.

[6] Costa E, Sacramento E, Lopes AA, Bina JC. Facial nerve palsy associated with leptospirosis. *Rev Soc Bras Med Trop* 2001; **34**: 219-220.

[7] Mahesh M, Shivanagappa M, Venkatesh CR. Bilateral abducent palsy in leptospirosis-an eye opener to a rare neuro ocular manifestation: A case report. *Iran J Med Sci* 2015; **40**(6): 544-547.

Publisher's note

The Publisher of the *Journal* remains neutral with regard to jurisdictional claims in published maps and institutional affiliations.

Edited by Pan Y, Lei Y, Zhang Q