

Letter to Editor

Asian Pacific Journal of Tropical Medicine

apjtm.org

doi: 10.4103/apjtm.apjtm_52_24

Measles giant cell pneumonia diagnosed in pleural decortication specimen

Sathe Pragati A✉, Vaideeswar Pradeep

Department of Pathology, Seth G. S. Medical College, Mumbai, India

Measles, caused by the measles virus (MeV), is a highly infectious pediatric viral disease and its recovery usually occurs within one week of the onset of the rash[1]. However, some patients may develop complications, the most common of which is pneumonia, often detected at autopsy[2,3].

In our case, a four-year-old girl presented with fever and cough for three weeks. Despite receiving antibiotic therapy, she developed left-sided empyema and was referred to our tertiary-care center on the 24th day of her illness. She received the BCG vaccine and two doses each of Oral Polio and Hepatitis B vaccine before the onset of the disease. Chest auscultation revealed reduced air entry on the left side. Investigations revealed anemia, neutrophilia and positive blood culture yielding *Klebsiella* species. Computed tomography of the chest showed left lung empyema, loculated pneumothorax and left lower lobe collapse. On the 12th day of hospital admission, she developed a confluent maculo-papular rash over the trunk, which suggested a viral exanthema. Two days after the rash, she underwent thoracotomy. Intraoperatively, gangrenous parts of the left lower lobe and adherent thickened pleura were excised. On histopathology, large areas of pulmonary infarction were noted with some viable parenchyma. The alveolar spaces in the viable areas were filled with fibrino-purulent exudates with mononuclear cell infiltration in the septa. A characteristic finding revealed the presence of many multinucleated giant cells within the alveolar spaces, and lining the alveolar septa and the bronchioles. Well-defined intra-nuclear eosinophilic inclusions surrounded by a halo (Figure 1A and 1B), typical of measles infection were also noted; however, cytoplasmic inclusions were not seen. The fever and the rash subsided about a week after the decortication.

A giant cell pneumonia (GCP) with typical inclusions of MeV was rarely reported in pleural decortications performed in children. GCP can occur in malnourished children, elderly patients and those who are immunocompromised. The giant cells are formed by the fusion of the epithelial cells due to the expression of the H and F viral proteins on the surface of the infected cells and lining the alveolar septa and the bronchioles[4]. Of the four stages of measles, giant cell formation is a feature of prodromal phase and thus occurs before the development of rash[5]. Our patient had been symptomatic for a period of nearly a month, which is beyond the usual duration of the incubation period of measles. It is likely that our patient probably started with a bacterial pneumonia and empyema, and then infected by MeV. The aggravating factors would have been

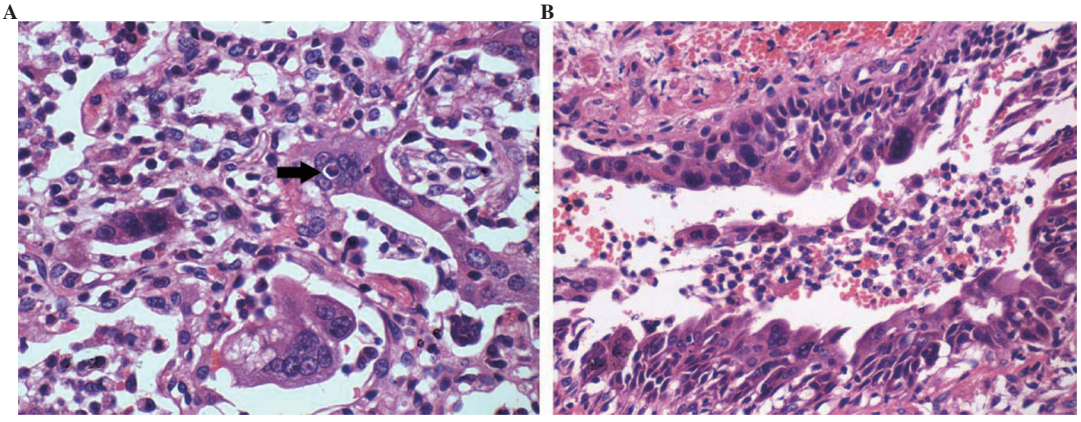

Figure 1. H&E staining of pleural decortication specimen in a four-year-old girl diagnosed with measles giant cell pneumonia. (A) Syncytial giant cells with intranuclear eosinophilic inclusion bodies surrounded by halo (arrow) seen lining thealveolar septa (×600). (B) Bronchiole showing similar syncytial giant cells with intranuclear inclusions (H&E ×600).

profound immunosuppression induced by MeV, malnutrition and non-immunized status for measles.

GCP is also caused by other viruses like respiratory syncytial virus, parainfluenza virus and human metapneumovirus[6]. Serological and microbiological tests were not performed in our case but the typical well defined eosinophilic intranuclear inclusions clinched the diagnosis. There is also often bacterial super-infection, as seen in our case along with more alarming lung gangrene. Most descriptions of measles GCP are in autopsied cases. To the best of our knowledge, this is the first case of measles GCP to be described in a pleural decortication tissue.

Conflict of interest statement

The authors declare that they have no conflict of interest.

Ethical approval and patient's consent to participate

The patient's parents gave consent for the publication, as the patient is only 4 years old.

Funding

The authors received no extramural funding for the study.

Authors' contributions

Concepts, design, definition of intellectual content and literature search: SPA and PV; data acquisition and manuscript preparation by SPA; manuscript editing by PV; manuscript review by SPA and PV; guarantor by SPA.

References

[1] Moss WJ. Measles. *Lancet* 2017; **390**: 2490-2502.

[2] Dardis MR. A review of measles. *J Sch Nurs* 2012; **28**: 9-12.

[3] Gelaw A, Belyhun Y, Wondimeneh Y, Kokeb M, Dagnew M, Amare A, et al. Knowledge and associated factors of healthcare workers on measles vaccine and cold chain management at health institutions in Gondar, Ethiopia. *Asian Pac J Trop Med* 2023; **16**(1): 26-32.

[4] Rota PA, Moss WJ, Takeda M, de Swart RL, Thompson KM, Goodson JL. Measles. *Nat Rev Dis Primers* 2016; **2**: 16049.

[5] Leung AKC, Hon KL, Leong KF, Sergi CM. Measles: A disease often forgotten but not gone. *Hong Kong Med J* 2018; **24**: 512-520.

[6] Pritt BS, Aubry MC. Histopathology of viral infections of the lung. *Semin Diagn Pathol* 2017; **34**: 510-517.

Publisher's note

The Publisher of the *Journal* remains neutral with regard to jurisdictional claims in published maps and institutional affiliations.

✉To whom correspondence may be addressed. E-mail: pragativk@yahoo.com

This is an open access journal, and articles are distributed under the terms of the Creative Commons Attribution-Non Commercial-ShareAlike 4.0 License, which allows others to remix, tweak, and build upon the work non-commercially, as long as appropriate credit is given and the new creations are licensed under the identical terms.

For reprints contact: reprints@medknow.com

©2024 *Asian Pacific Journal of Tropical Medicine* Produced by Wolters Kluwer-Medknow.

How to cite this article: Pragati SA, Pradeep V. Measles giant cell pneumonia diagnosed in pleural decortication specimen. Asian Pac J Trop Med 2024; 17(11): 523-524.

Article history: Received 19 January 2024 Revision 14 November 2024
Accepted 19 November 2024 Available online 26 November 2024

Edited by Pan Y, Lei Y, Zhang Q